

MAY - AUG. 1999  
Volume V Number II

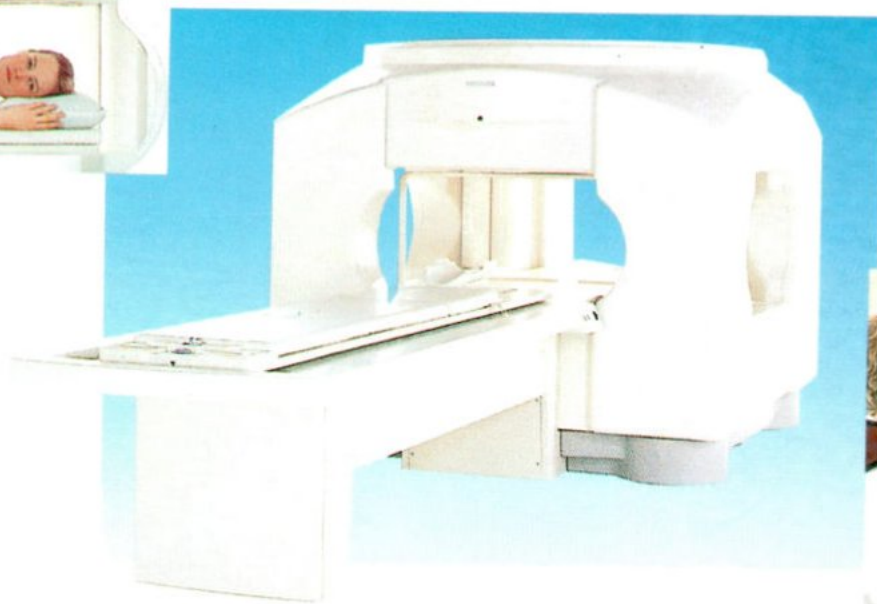
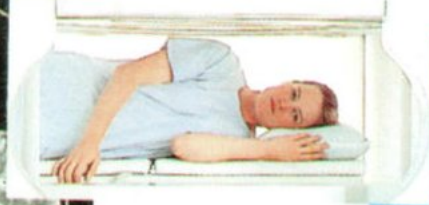ISSN 0859 144X

# THE ASEAN JOURNAL OF RADIOLOGY

Published by The Radiological Society and  
The Royal College of Radiologists of Thailand,  
Bangkok, Thailand

Supported through an educational grant from





# OPART

## Superconducting Performance, OPEN MR Advantages.

The pioneer of open MR imaging, Toshiba has now developed a superconducting cryogenless magnet which sets new standards for open MR systems.

OPART takes advantage of the latest technology to provide exceptional image quality through a variety of fast scanning techniques.

A unique open magnet design offers all-round patient access, enabling even large, claustrophobic, and pediatric patients to be scanned with ease.

### OPART Advantages

- Fast, flexible throughput for clinical productivity.
- Four sided patient accessibility, enhances patient comfort and throughput.
- A floating tabletop facilitates easy and accurate patient positioning for improved image quality.
- Icon driven computer platform, with user friendly software for true multitasking power.
- Long-term reliability and system upgradeability.
- Scanning is possible while the patient is still connected to ancillary MR compatible monitoring equipment.
- Exceptional performance across a variety of clinical applications.

# TOSHIBA

GLOBAL IMAGING • MEDICAL SYSTEMS



(SOLE DISTRIBUTOR)

**CMC BIOTECH CO., LTD.**

364 Muban Town-in-Town, Ladphrao 94 Ladphrao Road,  
Wangthonglang, Bangkok 10310

Tel. (662) 530-4995-6, 559-3261-2 559-2179-80, 538-4102, 538-0710 Fax 539-6903

MAY - AUG. 1999

Volume V Number II

ISSN 0859 144X

# THE ASEAN JOURNAL OF RADIOLOGY

Published by The Radiological Society and  
The Royal College of Radiologists of Thailand,  
Bangkok, Thailand

Supported through an educational grant from



**Editor-in-Chief**

Professor Kawee Tungsubutra  
Kaweewej Hospital, 318 Tarksin Road, Dhonburi, Bangkok 10600, Thailand.

**Associate Editors.**

- Indonesia:**
1. Professor Muhamad Djakaria  
Dept. of Radiology  
General Hospital Dr. Cipto  
Mangunkusumo  
Jalan Diponegoro 71  
Jakarta, Indonesia.
  2. Dr. Cholid Badri  
Dept. of Radiology  
General Hospital Dr. Cipto  
Mangunkusumo  
Jalan Diponegoro 71  
Jakarta, Indonesia.
- Singapore:**
1. Dr. Khor Tong Hong.  
Dept. of Radiotherapy  
Mt. Elizabeth Hospital  
Singapore 0922
  2. Dr. Lee Khai Mun  
Secretary Singapore Radiological Society  
c/o Singapore General Hospital  
Department of Therapeutic Radiology  
Outram Road. Singapore 169608  
Tel : ++65-3214210/3214204  
Fax : ++65-2228675
- Malaysia:**
1. Dr. Joginder Singh.  
President, The Malaysian  
Radiological Society  
c/o Department of Radiology  
University Hospital  
50603 Kuala Lumpur  
Malaysia  
Tel/Fax : ++60-3-7581973
  2. Dr. Maimunah Atan.  
Secretary General,  
The Malaysian Radiological Society.  
Department of Radiology.  
Hospital UKM.  
Jalan Tenteram. Bandar Tun Razak.  
56000 Kuala Lumpur, Malaysia.
- Philippines:**
1. Dr. Justo J. Dañguilan  
President, Philippine College  
of Radiology  
Unit 203, 1386 Merchant Square  
Condominium, E. Rodriguez Sr. Ave.,  
Corner Mabolo St., New Manila,  
Quezon City, Philippines.
  2. Dr. Eugene C. DY.  
The Chairman of The Committee on  
Continuing Medical Education  
and Research  
Unit 203,1386 Merchant Square Condominium,  
E. Rodriguez Sr. Ave., Corner Mabolo St. ,  
New Manila, Quezon City, Philippines.
- Brunei:**
1. Dr. Mohd lyaz Mohd Shafi  
Specialist Radiologist and  
Head, Radiology Department  
RIPAS Hospital  
Bandar Seri Begawan 2680  
BRUNEI DARUSSALAM
  2. Dr. Shahrin Merican  
Specialist Radiologist  
Radiology Department  
RIPAS Hospital  
Bandar Seri Begawan 2680  
BRUNEI DARUSSALAM
- Thailand:**
1. Dr. Saroj Vanapruks  
Dept. of Radiology,  
Siriraj Hospital  
Bangkok 10700  
Thailand.

**Editorial Board:**

- (1) Nitaya Suwanwela  
Dept. of Radiology, Chulalongkorn Hospital, Bangkok.
- (2) Suthisak Suthipongchai  
Dept. of Radiology, Siriraj Hospital, Bangkok.
- (3) Pacharin Pekan  
Dept. of Radiology, Ramathibodi Hospital, Bangkok.
- (4) Kaesorn Vajarapongse  
Dept. of Radiology, Chulalongkorn Hospital, Bangkok.
- (5) Poonsook Jitnusun  
Dept. of Radiology, Siriraj Hospital, Bangkok.
- (6) Sutee N. Songkla  
Dept. of Radiology, Siriraj Hospital, Bangkok.

**Manager:** Permyot Kosolphand.

# THE ASEAN JOURNAL OF RADIOLOGY

Volume V Number II MAY - AUG. 1999

## CONTENTS

|   | Page    |
|---|---------|
| 1. IMPACT OF RADIATION AND CHEMORADIATION WITH MITOMYCIN-C ON CELLULAR IMMUNITY OF PATIENTS WITH LOCALLY ADVANCED CERVICAL CANCER<br>Cholid BADRI   | 103-116 |
| 2. POSTOPERATIVE ADJUVANT RADIATION THERAPY IN BREAST CANCER PATIENTS WITH 10 OR MORE POSITIVE AXILLARY LYMPH NODES.<br>Nan SUNTORNPONG, M.D.   | 117-122 |
| 3. COLON CANCER: RADIOGRAPHIC FINDINGS DETECTED BY BARIUM ENEMA.<br>Chalida APHINIVES, Sukhonta SANMAHACHAI,<br>Jitjaroen CHAIYACUM, Eimorn MAIRIANG,<br>Jiraporn SRINAGARIND, Vallop LAOPAIBOON.                 | 123-128 |
| 4. DIVERTICULAR DISEASE OF THE COLON IN THAILAND :<br>" INCIDENCE AND DISTRIBUTION "Kamolwan JUNGMEECHOKE   | 129-132 |
| 5. ANGIOGRAPHIC FINDINGS OF HEPATOCELLULAR CARCINOMA IN SIRIRAJ HOSPITAL<br>KRUATRACHUE Chutakiat, PRABHASAVAT Krisdee,<br>IEMSAWATDIKUL Kriengkrai, VANAPRUNKS Saroj,<br>CHAIYASOOT Walailak, DANPUKDEE Kanjana. | 133-142 |
| 6. PERCUTANEOUS ABSCESS DRAINAGE OF INTRA-ABDOMINAL ABSCESSSES AND FLUID COLLECTION<br>Komgrit TANISARO   | 143-147 |
| 7. GLUE EMBOLIZATION IN RENAL TRAUMA WITH MASSIVE HEMATURIA<br>Kanjana DANPUKDEE, Anchalee CHUROJANA,<br>Suthisak SUTHIPONGCHAI.  | 149-152 |
| 8. EARLY DETECTION OF BREAST CANCER BY SCREENING MAMMOGRAPHY<br>Malai MUTTARAK, Ladda CHALOEYKITTI,<br>Hongsin TRAKULTIVAKORN, Chanane WANAPIRAK,<br>Benjaporn CHAIWUN, Samreung RANGDAENG.                       | 153-158 |
| 9. CT SCAN OF THE METASTATIC BRAIN TUMORS ; IS NON CONTRAST-ENHANCED CT SCAN NECESSARY ?<br>SORNSUPHA CHOKECHAIPAISAL,<br>ASSO PROF. PAITON CHONGCHITNANT,<br>KONGRIT THANISARO,MD. CHIRAWAT UTTAMAKUL.           | 159-162 |

# THE ASEAN JOURNAL OF RADIOLOGY

Volume V Number II MAY - AUG. 1999

## CONTENTS

|  | Page    |
|--|---------|
| 10. MRI AND US APPEARANCE OF AN INTRAMUSCULAR MYXOMA: A CASE REPORT<br>Chate SIVASOMBOON   | 163-166 |
| 11. COMPARISON OF BREATH HOLD MULTI-SLICE FAST MAGNETIC RESONANCE CHOLANGIOPANCREATOGRAPHY WITH ENDOSCOPIC CHOLANGIOPANCREATOGRAPHY: INITIAL EXPERIENCE<br>Kumar G, Abdullah BJJ, Rosmawati, Goh KL, Moosa F, Ahmad Sarji S & Bux SI                                 | 167-176 |
| 12. MR IMAGING OF AN EXTRAABDOMINAL DESMOID TUMOR OF THE SUPRACLAVICULAR AREA<br>Chate SIVASOMBOON   | 177-181 |
| 13. FIBROLIPOMATOUS INFILTRATION OF THE MEDIAN NERVE<br>NITINAVAKARN Benjaporn, JATUPARISUTHI Piyawan, MITCHAI Chumpon.  | 183-186 |
| 14. RUPTURE OF RADIOPAQUE TIP OF TORCON NB CATHETER<br>Komgrit TANISARO  | 187-189 |
| 15. SPINAL CORD-SUBARACHNOID SPACE RATIO AT CERVICAL REGION IN NORMAL THAI PEOPLE.<br>Pichest METARUGCHEEP   | 191-194 |
| 16. PROGNOSTIC VALUE OF THE RATIO THYROGLOBULIN TO I-131 UPTAKE AFTER THYROIDECTOMY BEFORE ABLATIVE RADIOIODINE THERAPY IN WELL-DIFFERENTIATED THYROID CANCER<br>Sunanta CHIEWVIT, Wanna TRIVITAYARATANA<br>Busara SATAYABAN, Ruentip TIPPAROJ,<br>Vipa BOONNAMSIRI. | 195-198 |
| 17. THE ADVANTAGE OF DOUBLE PHASE <sup>99m</sup> Tc-MIBI SCINTIGRAPHY OVER DUAL-TRACER SUBTRACTION METHOD IN TERTIARY HYPERPARATHYROIDISM WITH SICK EUTHYROID SYNDROME<br>Supatporn TEPMONGKOL, Kanaungnit KINGPETCH,<br>Supot BOONVISUT.                            | 199-204 |
| 18. OPTIMUM FIELD SEPARATION IN ADJACENT FIELDS OF ELECTRON BEAM THERAPY<br>TUNTIPUMIAMORN L., POLWATSATIEN V.,<br>SUTUD NA AYUTHAYA B., SAINET S.   | 205-212 |

---

## IMPACT OF RADIATION AND CHEMORADIATION WITH MITOMYCIN-C ON CELLULAR IMMUNITY OF PATIENTS WITH LOCALLY ADVANCED CERVICAL CANCER

Cholid BADRI, MD., PhD.

### ABSTRACT

**OBJECTIVE:** To evaluate the impact of chemoradiation therapy with Mitomycin-C (MMC) on the cellular immunity of patients with locally advanced cervical cancer compared with radiation therapy alone.

**MATERIALS AND METHODS:** Fifty-six patients with locally advanced cervical cancer were divided into two groups, 34 patients treated with radiation alone and 22 patients with chemoradiation. Chemoradiation was performed by adding 15 mg MMC/m<sup>2</sup> body surface through intravenous bolus injection on the first day of external radiation and on the first day of intracavitary radiation during the radiation routinely administered. In all patients, lymphocyte transformation test was performed after completion of external radiation, in one month, and three months after full-course treatment.

**RESULTS:** In radiation group, a significant decrease of lymphocyte transformation index was evident after external radiation compared with pre-treatment values, i.e., from  $25.82 \pm 14.30$  % to  $19.02 \pm 10.54$  % ( $p = 0.08$ ). These parameters were further decreased to  $17.85 \pm 9.63$  % in one month after full-course radiation. Although there was an increase to  $18.97 \pm 9.29$  % at three months after full-course radiation, these values were still significantly lower than the values before radiation ( $p = 0.015$ ). In chemoradiation group, there was an insignificant decrease of lymphocyte transformation index after external radiation and first MMC administration, compared with the values before radiation, i.e.,  $19.09 \pm 12.66$  % to  $21.72 \pm 12.68$  %. A significant decrease of these parameters to  $13.68 \pm 8.23$  % ( $p = 0.038$ ) was noted at one month after full-course chemoradiation compared with the values before treatment. There was an increase of the parameters to  $17.31 \pm 11.32$  % after full-course chemoradiation, such that they were not significantly different from the values before treatment.

**CONCLUSIONS:** Chemoradiation with MMC in patients with locally advanced cervical cancer did not result in greater impact on cellular immunity than radiation alone; the parameters would even improve rapidly in three months after treatment. The factors that possibly played a part in such condition were working mechanism and interval of MMC administration, as well as rebounded overshoot phenomena of lymphocyte transformation after cytotoxic treatment.

**Keywords:** Cervical cancer, chemoradiation, cellular immunity, lymphocyte transformation.

---

Department of Radiology, Faculty of Medicine University of Indonesia/Dr Cipto Mangunkusumo Hospital, Jakarta

## INTRODUCTION

Chemoradiation therapy is frequently applied for locally advanced cancers with the purpose of providing better responses to both modalities than the separate treatment.<sup>1</sup> Each modality can decrease immunity of patients particularly cellular immunity which is the function of the important immune cells in cancer patients in coping with and eradicating tumor cells developing in their body. The decreased cellular immunity due to radiation is associated with a number of typical diseases, such as herpes zoster,<sup>2</sup> and even with the decreased survival rate in cancer patients receiving postoperative radiation.<sup>3</sup> Cellular immunity may also decrease as a result of chemotherapy such that infectious and fungal diseases may occur.<sup>4</sup> There is a possibility that the combined radiation and cytotoxic drug can result in synergism of immunosuppressive effects that lead to infection, increased metastasis, and development of secondary tumor.<sup>5</sup> This is even more likely when chemoradiation is performed in patients with advanced stage whose cellular immunity generally tends to decrease because of the progress of the disease and malnutrition.<sup>6</sup>

Thus, even though chemoradiation may provide better therapeutic effects than the administration of radiation alone, it may cause toxicity to the extent that its benefits and risks should be carefully considered.

The examination of immunoblastic transformation is one of the qualitative tests for cellular immunity through the determination of the functional abilities of lymphocytes *in vitro*, i.e. the abilities to provide responses to mitogen.<sup>7</sup> Lymphocyte transformation test is basically aimed to show responses of T- lymphocyte to stimulation by mitogen.<sup>8</sup> Although not a single immunologic test *in vitro* can explain the functional abilities of lymphocytes *in vitro* appropriately, since there are other numerous functions in body at work, the re-

sults of this test are considered to have a correlation with the biologic expression of lymphocyte in the body.<sup>9</sup>

The examination of lymphocyte transformation as an immunologic parameter has been performed in various studies in cancer patients who were treated by radiation or other modalities.<sup>10, 11</sup>

Chemoradiation therapy was a method of treatment in locally advanced cervical cancer and one of cytotoxic agents used was Mitomycin-C (MMC). This agent was indicated as a hypoxic radiosensitizer although its application was limited due to bone marrow suppression.<sup>12</sup> However, the impact of chemoradiation using MMC on cellular immunity, particularly in cervical cancer patients, has not been reported yet.

In this study, analysis of the impact of radiation therapy and chemoradiation with MMC of locally advanced cervical cancer on cellular immunity was examined with lymphocyte transformation test. The objective of the study was to evaluate the extent to which the combined therapy exerted its impact on patients' cellular immunity compared with radiation therapy alone.

## MATERIALS AND METHODS

The study was performed in locally advanced cervical cancer patients referred for radiation therapy at Department of Radiotherapy, Dr Ciptomangunkusumo Hospital. Patients were from Department of Obstetrics and Gynecology, Faculty of Medicine University of Indonesia who had undergone routine examinations and biopsy to determine clinical stage and histopathological type in accord with the prevailing protocols.<sup>13</sup> The determination of clinical stage was performed using the 1976 FIGO system. Patients with locally ad-



vanced stage, i.e., stage IIb to stage IIIb meeting the inclusion criteria i.e., performance status of 50-100 according to Karnofsky scale, hemoglobin  $\geq 10$  g%, leucocyte  $> 4000/\text{mm}^3$ , thrombocyte  $> 100,000/\text{mm}^3$ , normal renal and heart functions, and having not received radiation and chemotherapy were included in this study.

Biospy specimen was sent for routine histopathologic and immunostaining examinations using Ki-67 monoclonal antibody,<sup>14</sup> to Department of Anatomic Pathology, Faculty of Medicine University of Indonesia. Routine histopathologic examinations were performed to identify histopathologic type and differentiation specified in the protocol of routine histopathologic examinations. Immunostaining using Ki-67 monoclonal antibody was performed to determine growth fraction of tumor<sup>15</sup> those were assumed to be associated with hypoxic state of the tumor.<sup>16</sup>

Patients receiving the treatment were divided into two groups, i.e., those with Ki-67 index  $\geq 40$  (high growth fraction) and those with Ki-67 index  $< 40\%$  (low growth fraction). Each group was randomized into two treatment arms i.e. chemoradiation with MMC and radiation alone. Written informed consent was obtained as needed after the subject of the study and her family were counseled on the objectives and steps of the study.

## RADIATION THERAPY

Radiation therapy was performed in the form of external radiation administered in whole pelvis, and intracavitary radiation was followed 1-2 weeks afterwards. External radiation was administered using anterior-posterior radiation portals with superior border was between IV and V lumbar spines, inferior border was lower border of symphysis pubis, lateral border was 1.5 cm from linea inominata. The dose administered was 180 cGy fraction per week, and a total dose of 5040 cGy in 5½ weeks with 10 MV linear accel-

erator or telecobalt-60 machine.

Intracavitary radiation was generally administered with HDR afterloading technique using Cobalt-60 sources with Selectron machine. Overall, it was performed twice with a one-week interval with Manchester system using RRTI (Rotterdam Radiotherapeutisch Instituut) applicator. A dose of 850 cGy was given at point A in each application such a way that the bladder and rectal doses did not exceed 700 and 800 cGy, respectively. In small number of patients after loading technique was performed manually with Low Dose Rate (LDR) system using Cs-137 source. This technique was performed twice in the same interval as HDR system with a dose of 1300 cGy at point A and with bladder and rectal doses equivalent to HDR system.

## CHEMORADIATION THERAPY

The radiation technique performed was similar to that applied in the radiation group. MMC was administered simultaneously on day one of external radiation and on day one of intracavitary radiation, with a dose of 15 mg/m<sup>2</sup> of body surface through intravenous bolus injection.

## CLINICAL AND LABORATORY EXAMINATIONS

In each patient, clinical examinations were performed prior to the treatment, every week during the treatment, after external radiation with or without MMC, at one month and 3 months after overall treatment. Routine peripheral blood examinations were performed at the same periods except 3 months after treatment. The examinations of liver and renal functions were performed before treatment, after external radiation with or without MMC and at one month after completion of overall treatment. Lymphocyte transformation tests were performed at the same periods and also three months after completion of the overall treatment.

## EXAMINATIONS OF LYMPHOCYTE TRANSFORMATION

Culture medium was made in accordance with Suharso's method, 1978.<sup>17</sup> The study of cell morphology of the culture could be done if the culture had lasted for 72 hours, and culture medium was separated with centrifugation of 600 gravitation during 10 minutes. Furthermore, the following steps were done:

(a) Deposit obtained was rinsed twice with BBS pH 7.2 Hanks solution. Then it was poured into hypotonic solution (KCI 0,075 M KCI solution) for 15 minutes such that its cells become lysis.

(b) Fluid was separated by re-centrifugating at the speed of 600 gravitation for 10 minutes. The deposit was fixated with Carnoy fixation. Fixations were changed several times until the deposit had the color of clean white.

(c) A suspension was made from the last deposit, scattered on the object glass and stained with Giemsa solution. After it has dried, the specimen was covered with Canada balm.

Microscopic examination was performed by dividing each specimen into 75 selection areas, in which each selection area measured 1 x 1 cm<sup>2</sup>. Within the selection area chosen, 100 cells were counted and classified according to their morphology observed under a 10 x 45 magnified microscope. Classifications of the cells observed under microscope were as follows:

(a) Cells that did not transform: also called as the usual lymphocytes; small, round cells of dark and solid color with a diameter of 1.k. 8 m.

(b) Cells that transformed, consisting of:

- Lymphoblasts or blastocytes: 12-50 m diameter

round-shaped cells, red-bluish color with Giemsa staining. Occasionally blue cytoplasm was observed around the nucleus

- Mitotic phase: Lymphoblast would enter mitotic phase when nuclear membrane was unobserved, and chromosome threads began to appear clearly. In advanced mitotic phase, only the scattered chromosome had a long and short size. The degree of lymphocyte transformation was stated in transformation index according to Matangkasombut and Tharavanich, 1972.<sup>18</sup>

## DATA IDENTIFICATION AND STATISTICAL ANALYSIS

Data of the study were identified manually and entered into computer to be analyzed statistically with SPSS program. Data were processed with independence T-test for unpaired groups, paired test, and X<sup>2</sup> - test for comparability among groups.

## RESULTS

The study was carried out from October 1994 to September 1996. The examinations of lymphocyte transformation were performed in 114 patients; however, only 56 patients were able to undergo regular lymphocyte transformation tests up to three months after radiation. In other patients, analysis could not be performed because of incomplete data, technical errors, and untimely admission of the patients.

From the same patients examination results of leukocyte number were obtained prior to the treatment, after external radiation with or without MMC and one month after completion of treatment except at three months after completion of treatment. Of 56 patients, 24 were included in the group receiving radiation alone, while the other 22 received chemoradiation with MMC (Table 1).

**Table 1.** Characteristics of patients

|                  | Radiation therapy | Chemoradiation group |
|------------------|-------------------|----------------------|
| Stage            |                   |                      |
| II b             | 20                | 13                   |
| III b            | 14                | 9                    |
| Histology        |                   |                      |
| Squamous cell ca | 32                | 20                   |
| Adeno            | 2                 | 2                    |
| Differentiation  |                   |                      |
| Well/moderate    | 27                | 17                   |
| Undifferentiated | 7                 | 5                    |
| Tumor size       |                   |                      |
| < 4 cm           | 17                | 9                    |
| ≥ 4 cm           | 17                | 13                   |
| Hemoglobin       |                   |                      |
| < 12 g %         | 20                | 12                   |
| ≥ 12 g %         | 14                | 10                   |
| Ki -67 index     |                   |                      |
| < 40 %           | 7                 | 12                   |
| ≥ 40 %           | 27                | 10                   |
| Response         |                   |                      |
| complete         | 28                | 18                   |
| partial          | 6                 | 4                    |
| Total patients   | 34                | 22                   |

### INDEX OF LYMPHOCYTE TRANSFORMATION

In the group of radiation alone (n = 34) index values of lymphocyte transformation were obtained, i.e., before radiation in the range of 00.00 to 53.00%, mean  $25.82 \pm 14.30$  % and after external radiation 5040 cGy from 00.00 to 51.00%, mean  $19.02 \pm 10.54$ %. One month after complete radiation, the values ranged from 00.00 to 38.00%, mean  $17.85 \pm 9.63$ %, and three months after complete radiation from 00.0 to 36.00%, mean  $18.97 \pm 9.29$ %.

A significant decrease in lymphocyte transformation index was evident after 5040 cGy radiation compared with the index prior to radiation (p = 0.008). In the period of three months after complete radiation, the index was still significantly low compared with that before radiation (p = 0.015), even though the values had improved (Table 2).

**Table 2.** Mean values of lymphocyte transformation in radiation group

| Period of examination       | Transformation index | p     |
|-----------------------------|----------------------|-------|
| Before radiation            | 25.82 ± 14.30        |       |
| After external radiation    | 19.02 ± 10.54        | 0.008 |
| One month post radiation    | 17.85 ± 9.63         |       |
| Three months post radiation | 18.97 ± 9.29         | 0.015 |

In the group of chemoradiation (n = 22) the following index values of lymphocyte transformation were obtained: before chemoradiation ranged from 00.00 to 40.00%, mean 21.72 ± 12.68%, after external radiation of 5040 cGy + MMC from 00.00 to 52.00%, mean 19.09 ± 12.66%. One month after complete chemoradiation, the values obtained ranged from 00.00 to 28.00%, mean 13.68 ± 8.23, and three months after complete chemoradiation from 00.00 to 35.00%, mean 17.31 ± 11.32% .

It was evident that after the first MMC administration and 5040 cGy radiation, there was no significant difference from the values prior to chemoradiation. However, after one month of the second administration of MMC and complete chemoradiation, there occurred a significant decrease compared with the values before therapy (p = 0.038). Lymphocyte transformation values at three months after completion of combined therapy showed an increase to the extent that there was no significant difference (p = 0.192). from the values prior to treatment (Table 3).

**Table 3.** Mean values of lymphocyte transformation in chemoradiation group

| Period of examination         | Transformation index | p     |
|-------------------------------|----------------------|-------|
| Before treatment              | 21.72 ± 12.68        |       |
| Post external radiation + MMC | 19.09 ± 12.66        |       |
| One month post treatment      | 13.68 ± 8.23         | 0.038 |
| Three months post treatment   | 17.31 ± 11.32        |       |

The comparison of index values between the two groups in various periods of examination was as follows: means before therapy ranged from 25.82 ± 14.30% to 21.72 ± 12.68% and after 5040 cGy radiation from 19.02 ± 10.54% to 19.09 ± 12.66%. After one month of complete radiation, the comparison between means of index values was from 17.85 ± 9.63% to 13.68 ± 8.23%, and after three months of complete radiation from 18.97 ± 9.29%, to 17.31 ± 11.32% .

If the index values in each period of examination were compared, there would be no significant difference between both groups (p > 0.05). However, there was a trend of slow decrease and then followed by rapid increase of lymphocyte transformation values during treatment in chemoradiation group compared with radiation group (Figure 1).

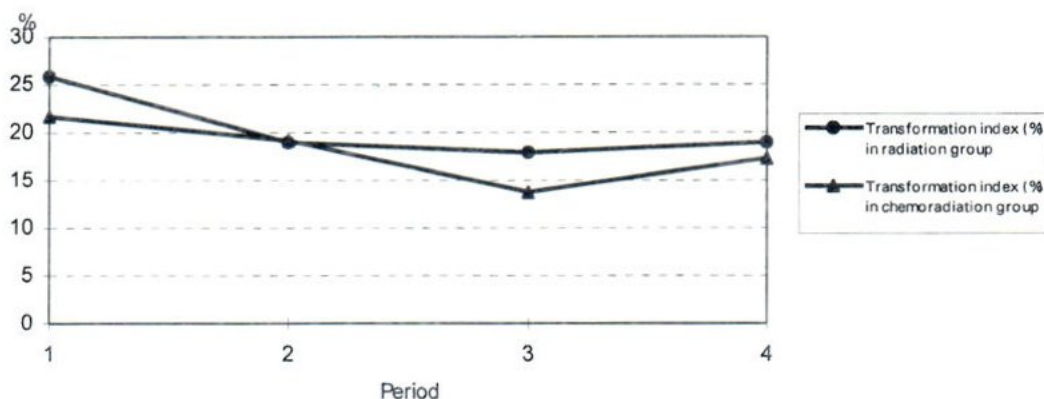


Fig. 1 Mean values of lymphocyte transformation index in both groups of treatment

**NUMBER OF LEUKOCYTES**

The average number of leukocytes before radiation was obtained in radiation group was between 1100/mm<sup>3</sup> and 16600/mm<sup>3</sup>, mean 8756 ± 3920/mm<sup>3</sup>. After external radiation, the number of leukocytes was 1000/mm<sup>3</sup> to 9500/mm<sup>3</sup>, mean 5615 ± 1786/mm<sup>3</sup>. After one month of complete radiation, the number of leukocytes was 2500 / mm<sup>3</sup> to 10800 /mm<sup>3</sup>, mean 5836 ± 1825/ mm<sup>3</sup> (Table 5).

Compared with the number of leukocytes before therapy, there occurred a significant

decrease after external radiation (p = 0.000) and at one month after complete radiation (p = 0.001). Although there was an increase in the number of leukocytes at one month after completion of therapy; however, this was not significant compared with the number of leukocytes after the completion of external radiation therapy (p = 0.643). These results showed that although there was a decrease, mean of leukocytes number remained within normal limit (4500-10,000/mm<sup>3</sup>).

Table 4. Number of leukocytes before and after treatment in radiation group

| Period of examination    | Number of leukocytes /mm <sup>3</sup> | p     |
|--------------------------|---------------------------------------|-------|
| Before radiation         | 8756 ± 3920                           |       |
| Post external radiation  | 5615 ± 1786                           | 0.000 |
| One month post radiation | 5836 ± 1825                           | 0.001 |

The average number of leukocytes before chemoradiation was 1000 /mm<sup>3</sup> to 11700/mm<sup>3</sup>, mean 7382 ± 3035/mm<sup>3</sup>. After external radiation, the number of leukocytes was 3200/mm<sup>3</sup> to 9000/ mm<sup>3</sup>, mean 5482 ± 1542. After one month of complete radiation, the number of leukocyte was 1000/ mm<sup>3</sup> to 7800 /mm<sup>3</sup>, mean 5187 ± 1590/mm<sup>3</sup> (Table 5). Compared with the number of leukocytes before treatment, there was a significant decrease after external radiation (p = 0.024) and at after

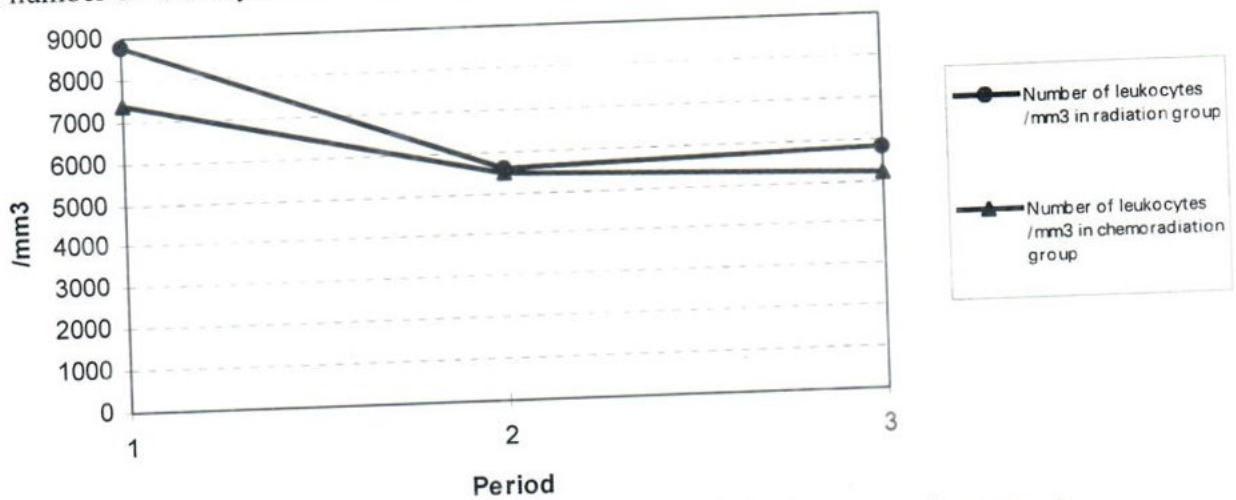
one month of complete treatment (p = 0.002). There was an increase in the number of leukocyte in one month after complete treatment (table 5) however, this was not significant compared with the number of leukocytes after completion of external radiation (p = 0.531). These results showed that although there was a decrease, mean of leukocyte number was still within the normal limit (4500 - 10,000/mm<sup>3</sup>).

**Table 5.** Number of leukocytes before and after treatment in chemoradiation group

| Period of examination     | Number of leukocytes /mm <sup>3</sup> | p     |
|---------------------------|---------------------------------------|-------|
| Before treatment          | 7382 ± 3035                           |       |
| After ERT                 | 5482 ± 1542                           | 0.024 |
| One month after treatment | 5187 ± 1590                           | 0.002 |

In addition, the results revealed that either before, after treatment, or at one month after treatment, there was no significant difference between the number of leukocytes in radiation group and

in chemoradiation group. Nevertheless, there was milder decrease of leukocytes in chemoradiation group after external radiation + MMC compared with radiation group (Figure 2).



**Fig. 2** Mean values of leukocyte number in both groups of treatment

It was evident that in each group there was a comparable distribution in age, stage, histopathologic type, differentiation degree, tumor

size, Haemoglobin value, Ki-67 index, and responses to radiation (Table 7)

**Table 7.** Comparability of two treatment group

|                                |                  | Radiation (n) | Chemoradiation (n) | p     |
|--------------------------------|------------------|---------------|--------------------|-------|
| Age                            | Mean             | 48.09         | 48.73              | 0.810 |
| Stage                          | Iib              | 20            | 13                 | 0.985 |
|                                | IIIb             | 14            | 9                  |       |
| Histopathologic type carcinoma | Squamous cell    | 2             | 2                  | 0.656 |
|                                | Adenocarcinoma   | 32            | 20                 |       |
| Differentiation degree         | Well/moderate    | 27            | 17                 | 0.705 |
|                                | Undifferentiated | 7             | 5                  |       |
| Tumor size                     | < 4 cm           | 17            | 9                  | 0.514 |
|                                | ≥ 4 cm           | 17            | 13                 |       |
| Hemoglobin value               | < 12 g %         | 20            | 12                 | 0.757 |
|                                | ≥ 12 g %         | 14            | 10                 |       |
| Ki-67 index                    | < 40 %           | 7             | 12                 | 0.089 |
|                                | ≥ 40 %           | 27            | 10                 |       |
| Tumor response                 | Complete         | 28            | 18                 | 0.960 |
|                                | Partial          | 6             | 4                  |       |

## DISCUSSION

Immunodeficiency in cancer patients is likely to occur as a result of multiple factors correlated with the patient, tumor, and environment.<sup>19</sup> It has been known that tumor occurred more frequently in people with suppression of immune system than in normal people.<sup>20</sup> Malnutrition will cause defects in cellular immune response and antibody formation.<sup>21</sup> Immunocompetence in cancer patients correlates with disease stage and prognosis<sup>22</sup> and may decrease with the progress of disease and metastasis.<sup>23</sup> In the present study, the possibility of decreased immune response was higher in patients with locally advanced stages, and presumably with malnutrition indicated by low Hemoglobin value before treatment (mean 11.72g%). It was obvious that lymphocyte transformation index before radiation or chemoradiation was lower than the normal values, i.e.,  $24.23 \pm 13.72\%$  compared with  $37.18 - 45.26 \%$ .<sup>17</sup>

Immunosuppression resulting from treatment contributing to the immunodeficiency of cancer patients was also demonstrated in this study; there was a significant decrease in lymphocyte transformation index in patients receiving either radiation or chemoradiation compared with the values before treatment, i.e.,  $25.82 \pm 14.30 \text{ mm}^3$  versus  $17.85 \pm 9.63 \text{ mm}^3$  and  $21.72 \pm 12.68 \text{ mm}^3$  versus  $13.68 \pm 8.23 \text{ mm}^3$ , respectively.

Immunologic abnormalities generally occurred in local and regional radiation; however, the length and severity of such disorder usually were neither quite obvious nor specific.<sup>24</sup> Restoration of mitogen response may occur in six months or even longer<sup>25</sup> after local radiation in various body organs. Radiation in mediastinum or pelvic region resulted in rapid decrease of T and B cell, with disorder in mitogen reaction; however, a recovery may occur in three weeks after radiation.

In present study it was evident that in radiation group there was decreased in leukocytes number that presumably indicated the decreased of lymphocyte number during external radiation. One month after full - course radiation the number of leukocytes was increased although this was not significant compared with the leukocyte number before radiation. It should be noted that the leukocyte number at 3 months after treatment was not available.

It was evident that in radiation group there was a decrease in lymphocyte transformation at the end of radiation and it tended to recover at one to three months after radiation completion although the value was still less than before radiation. Another data showed that loco-regional radiotherapy resulted in a decreased lymphocyte transformation to approximately 50 % of the initial value, with a partial recovery to 80 % of pre-treatment level 3 months after therapy.<sup>26</sup> These data are similar to our results.

The pattern of changes of lymphocyte transformation as well as the leukocyte number in radiation group could be observed in figure 3.

In general, the combined radiation and cytotoxic drug could reduce more lymphocytes than cytotoxic drug alone. In prophylactic radiation of the cranium in the treatment of acute lymphocytic leukemia which had remission after chemotherapy induction, it revealed that the decrease of lymphocytes and reduced reaction of lymphocytes toward mitogen stimulation were more evident.<sup>27</sup> Impact to cellular immunity is primarily because of stem cell death in the bone marrow and in part of peripheral lymphocyte.<sup>28</sup>

In this study, there was a significant decrease of leukocyte number of patient in chemoradiation group after external radiation and first

administration of MMC and at one month of after complete treatment. Although there was an increase of leukocyte number at one month after complete treatment, this was not significant as compared with the number after completion of external radiation + MMC. These results also showed that even though there was a decrease, mean of leukocyte number was still within the normal limit.

difference from the values prior to the treatment. However, after one month of the second administration of MMC, there occurred a significant decrease compared with values before therapy ( $p = 0,038$ ). Lymphocyte transformation values at three months after completion of chemoradiation showed an increase to the extent that there was no significant difference from the values prior to treatment.

In chemoradiation group, lymphocyte transformation values after external radiation + first administration of MMC were not significant

The pattern of lymphocyte transformation changes as well as the leukocyte number in radiation group could also be observed in figure 4.

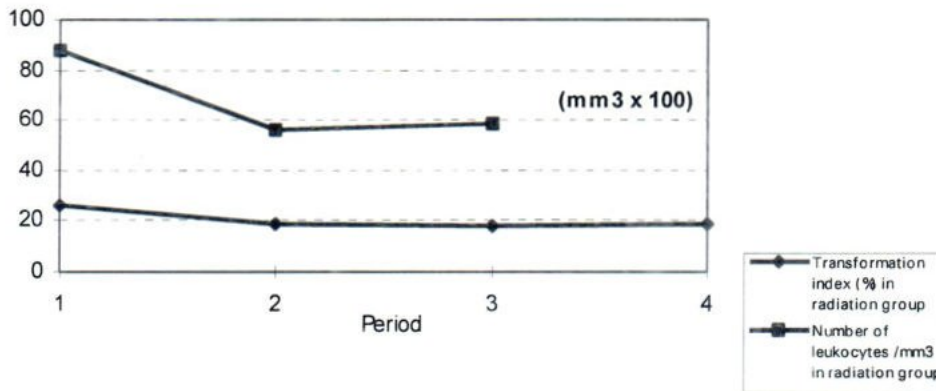


Fig. 3 Mean values of lymphocyte transformation index and leukocyte number in radiation group

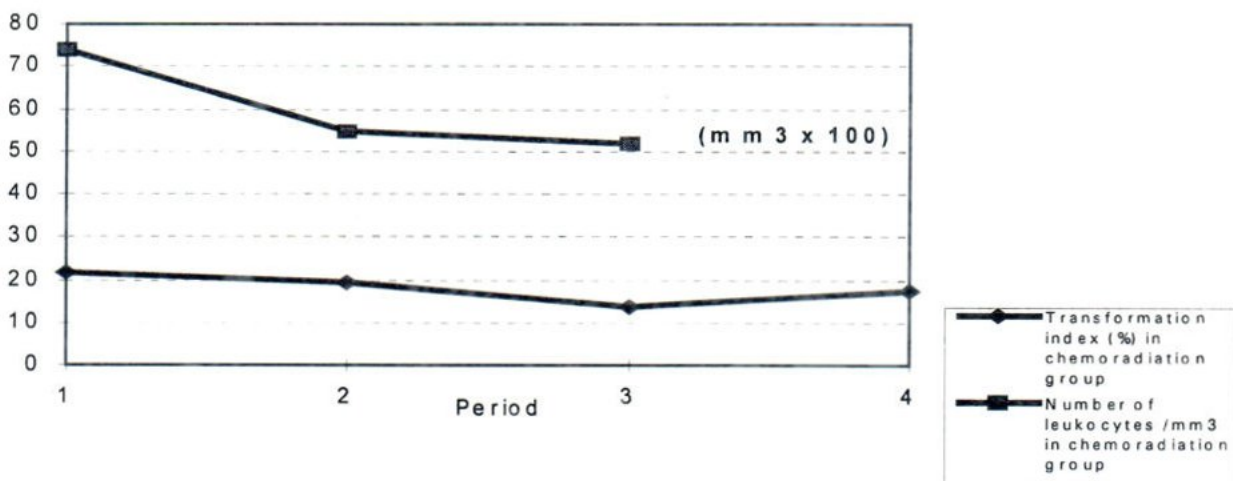


Fig. 4 Mean values of lymphocyte transformation index and values of leukocyte number in chemoradiation group



The use of MMC as single cytotoxic agent in this study presumably did not much affect lymphocyte transformation since it did not much affect T cell. The impact of cytotoxic drug on peripheral lymphocytes was relatively lower than that of radiation since T cells those constituting the majority in peripheral lymphocyte cells, were at phase  $G_0$  as such that they were not vulnerable to the treatment with MMC.<sup>29</sup>

The treatment of combined radiation and MMC could potentially enhance the impact on cellular immunity. However, the increased toxicity due to MMC would affect temporarily since the death of the main cells in bone marrow could be compensated if MMC was administered in sufficient intervals.<sup>30</sup>

In this study, lymphocyte transformation test performed at the end of the fifth week after radiation did not show any significant decrease, presumably because MMC was administered on the first the day of radiation and had compensated after five weeks. However, lymphocyte transformation values appeared to decrease in one month after chemoradiation because the second MMC administration was performed five weeks before the examination during which no complete recovery had occurred. The MMC administration performed in large dose would cause depression of bone marrow which would recover after six weeks.<sup>31</sup>

Although radiation and chemoradiation had the suppressive effect on immune system, the important difference was that in radiation such effects lasted in a long time and may depend on blood volume passing the radiation field. Suppressive effects of cytostatics were generally short-lived. Complete or nearly complete restoration of immune parameter may occur after completion of systemic chemoradiation, and many parameters could show overshoot phenomena.<sup>32</sup> This phenomena was observed following short, intensive

courses of chemotherapy in patients with solid tumor. It was demonstrated that recovery of lymphocyte transformation beginning approximately 3 days after treatment and rebounding frequently to the level of function greater than those before treatment by 9 days after cessation of treatment.<sup>33</sup>

In addition to exerting possible adverse impacts, chemoradiation may be beneficial in enhancing immune response. The enhanced response may be caused by sensitivity of suppressor cells that if their functions were disrupted due to radiation an enhanced immune response would occur. It will be likely to occur when using alkylating agents<sup>35</sup> whereas MMC is one among them.<sup>34</sup>

A number of factors called for attention in the administration of chemoradiation to avoid cumulative toxicity effects, particularly on cellular immunity includes:

### 1. Types of chemoradiation

Combination of both modalities will therefore depend on the type of cytotoxic drug being used. With chemoradiation there may exist different effects on cellular immunity due to the different type and mechanism of cytotoxic agents. The effects of MMC on cellular immunity was minimal because T cell was at  $G_0$  phase such that it was not sensitive to MMC<sup>35</sup>; although there was some effect of MMC on bone marrow, this impact was reversible.

### 2. Single or combined chemotherapy

In general, the administration of single cytotoxic agent less suppressive impacts on the number of lymphocytes compared with combined chemotherapy. B cell was more sensitive to single cytotoxic agent than was T cell, while combined chemotherapy had equal impact on both of them<sup>36</sup>.

### 3. Timing of chemoradiation administration

The main toxicity limiting the use of MMC was slowed and cumulative myelosuppressive effect. The peak value of leukopenia and thrombocytopenia would be achieved in more than 28 days after the administration of single dose.<sup>37</sup> Thus, the accumulated suppressive effects may be prevented if the subsequent administration of MMC could be performed after four weeks. In the present study, MMC was administered in a minimum interval of six weeks to the extent that its suppressive effects in the first administration had been restored.

#### **4. Sequence of radiation and chemoradiation administration**

Several studies demonstrated that a number of cytotoxic drugs required functional immune response to enable it to be effective in killing the tumor.<sup>38</sup> The reduced immunocompetency by radiation administered before and after chemotherapy may reduce the potency of chemoradiation clinically to the extent that its use should be reconsidered in designing a combined treatment.

A drawback in this study, among others, was that lymphocyte examination was not performed, particularly of T-cell which exerted enormous effects on cellular immunity.

One of the indicators of chemoradiation effects on cellular immunity was the slowed-type hypersensitivity reaction. This reaction was produced by lymphokin released by T-lymphocyte already stimulated by the antigen working in macrophage as a final mediator. Thus, examination of skin test could be performed to enhance the reliability of cellular immunity test. In addition, other qualitative examinations, such as mixed lymphocyte reaction, should be performed to corroborate the results obtained.<sup>39</sup>

Examinations by way of lymphocyte transformation test in this study were performed with

index calculation based on somewhat subjective morphologic descriptions of lymphocyte cells. The other method to measure the sensitivity of the stimulated lymphocyte activity was by measuring the activity of DNA synthesis. This could be performed by incubating the stimulated lymphocytes by mitogen with radioactive thymidine.<sup>40</sup> The activity of DNA formation was proportionate with the extent to which thymidine was incorporated into the cells calculated with measuring tool of radioactivity.

#### **CONCLUSIONS**

Chemoradiation with MMC in patients with locally advanced cervical cancers did not result in greater impact on cellular immunity than radiation alone; it would even improve more rapidly at three months after treatment compared with patients treated with radiation alone. The factors that possibly played a part in such condition were working mechanism and interval of MMC administration, as well as rebounded overshoot phenomena of lymphocyte transformation after chemotherapy.

#### **ACKNOWLEDGEMENT**

The author is indebted to Professor M. Djakaria M.D, Professor Nana Suhana Ph.D., Santoso Cornain M.D., D.Sc, for their assistance during the studies and preparation of this manuscript.

#### **REFERENCES**

1. Thomas G, Dembo A, Fyles A, et al. Concurrent chemoradiation in advanced cervical cancer. *Gynecol Oncol* 1990;38 (3): 446.
2. Hoppe R, Fuks Z, Strober S, Kaplan HS. The long term effects of radiation on T and B-lymphocytes in peripheral blood after regional irradiation. *Cancer* 1977;40:2071-78.

3. Meyer KK. Radiation induced lymphocyte-immune deficiency. A factor in the increased visceral metastases and decreased hormonal responsiveness of breast cancer. *Arch Surg* 1970;101:114-120.
4. Klatersky J. Infectious complications secondary to cancer chemotherapy. In: Hellmann K, Carter SK editors. *Fundamentals of cancer chemotherapy*. New York: Mc Graw Hill, 1987;397-405
5. Braun DP, Harris JE: Effects of combination chemotherapy on immunoregulatory cells in the peripheral blood of solid tumor cancer patients: correlation with rebound overshoot immune function recovery. *Clin Immunol Immunopathol* 1981;20:143.
6. Hersh EM, Mavligit G, Gutterman JU. Immunodeficiency in cancer and the importance of immune evaluation of the cancer patient. *Med Clin North Am* 1076; 60:623
7. Nowell PC. Phytohemagglutinin. An initiator of mitosis in cultures of normal human leukocytes, *Cancer Res* 1960;20:462-466.
8. Lindhal K, and Kiessling K. Mechanism of phytohemagglutinin (PHA) action. *Exp Cell Res* 1972;70:17-26.
9. Pogo BGT. Early events in lymphocyte transformation by Phytohemagglutinin. I. DNA dependent RNA polymerase activities in isolated lymphocyte nuclei, *J Cell Biol* 1972;53:635-641.
10. Anderson RE, Standefer JC, Tokuda S. The structural and functional assessment of cytotoxic injury of the immune system with particular reference to the effects of ionizing radiation and cyclophosphamide. *Brit. J. Cancer* 1986;53(suppl.7):140-60.
11. Suhana N, Syahrums MH, Sudarmo S, Miftahul C. Reaksi Imunitas Selular In Vitro dan Jumlah Leukosit Penderita Kanker Payudara Stadium I dan II sebelum Pengobatan. *MKI* 1988;38(7):319-328.
12. Lorvidhaya V, Tonusin A, Charoeniam V, Punpae P, Changwiwit W, Isariyodom P. Induction chemotherapy and irradiation in advanced carcinoma of the cervix. In: Azis MF, Kampono N, Sjamsudin S, editors. *Cancer of the uterine cervix. Current impact on chemoradiation therapy*. Jakarta: Department of Obstetrics and Gynaecology Faculty of Medicine University of Indonesia, 1988:47-52.
13. Badri C. Penggunaan Komputer Personal Dalam Dosimetri Penyinaran Intrakavitari Kanker Leher Rahim. *Majalah Radiologi Indonesia* 1995;2;22-27.
14. Gerdes J, Lemke H, Barsch H et al. Cell cycle analysis of a cell proliferation-associated human nuclear antigen defined by monoclonal antibody Ki-67. *J Immunol* 1984;133:1710-15.
15. Nakano T, Oka K. Differential values of Ki-67 index and mitotic index of proliferating cell population. An assessment of cell cycle and prognosis in radiation therapy for cervical cancer. *Cancer* 1993; 72:2401-8.
16. Badri C, Djakaria M, Sjamsudin S, Endang SRH. Growth fraction defined by Ki-67 immunostaining as a selection for combined treatment of radiation and Mitomycin-C in locally advanced cervical cancers. *The Asean Journal of Radiology* 1998;3 (IV):215-28.
17. Suharso P, "Phytohemagglutinine" (PHA) dan hubungannya dengan transformasi limfosit. Skripsi Sarjana FIPIA-UI, Jakarta, 1978.
18. Matangkasombut P, and Taravanich S: Lymphocyte Transformation in vitro. Second Regional Workshop in Immunology. Mahidol University, Bangkok, 1972.
19. Ghossein NA, Bosworth JI. Immunocompetence in radiation therapy patients. *Handbook Cancer Immunol* 1978;4:1.
20. Al-Saraff M, Wong P, Sardesal S, et al. Clinical immunologic responsiveness in malignant disease: 1. Delayed hypersensitivity reaction and the effect of cytotoxic drugs. *Cancer* 1970;26:262.

21. Suskind RM. Malnutrition and immunoreponse. Kroc Foundation Series. New York: Raven Press, 1977;29-127
22. Webster DJT, Richardson G, Baum M, et al. Effect of treatment on the immunological status of women with advanced breast cancer. *Br J Cancer* 1979;39:676.
23. Levy RL, Kaplan HS. Impaired lymphocyte function in untreated Hodgkin's disease. *N Engl J Med* 1974;290:181.
24. Stratton JA, Byfield JE, et al: A comparison of the acute effects of radiation therapy; including or excluding the thymus, on the lymphocyte subpopulations of cancer patients. *J Clin Invest* 1975; 56:88.
25. Slater JM, Ngo E, Lau BHS. Effect of therapeutic irradiation on the immune responses. *AJR* 1976; 126:313.
26. Blomgren H, Hammarstrom S, Wasserman J, Petrini B. Prostaglandin sensitivity of the PHA response of blood lymphocytes following radiotherapy for breast cancer. *Radiother. Oncol.* 1986;7:141-5
27. Campbell AC, Hersey P, MacLennan ICM et al. Immunosuppressive consequences of radiotherapy and chemotherapy in patients with acute lymphoblastic leukaemia. *B Med J* 1973;2:385.
28. De Ruyscher D, Waer M, Vandeputte M, van der Schueren E. Immunologic changes after loco-regional radiotherapy and fractionated total body irradiation (TBI) in mice. *Int J Radiat Biol Phys* 1989;17:1237-45
29. Rockwell S. Effects of some proliferative and environmental factors on the toxicity of mitomycin-C to tumor cells in vitro. *Int J Cancer* 1986;38:229.
30. Verweij J, Hartgh J, Pinedo HM. Antitumor antibiotic. In : Chabner BA, Collins JM, eds. *Cancer Chemotherapy Principles and Practice*. Philadelphia : JB Lippincott, 1990;382.31.
31. Rockwell S, Sartorelli AC Mitomycin-C and radiation. In : *Anti tumor drug-radiation interactions*. Hill BT, Bellamy AS editors. Boca Raton : CRC Press, 1990; 125.
32. Braun DP, Harris JE. Cancer chemotherapy and its impact on the immune system. In: Hellmann K, Carter SK editors. *Fundamentals of cancer chemotherapy*. New York: Mc Graw Hill, 1987;397-405
33. Harada M, Mori T, Kodo H, et al: Overshoot phenomenon of phytohemagglutinin response after chemotherapy and its relationship to remission in acute non-lymphocytic leukemia. *Gann* 1979;70:89.
34. Berd D, Mastrangelo MJ, Engstrom EF, et al : Augmentation of the human response by cyclophosphamide. *Cancer Res* 1982; 42:4862.
35. Rockwell S, Sartorelli AC. Mitomycin-C and radiation. In : *Anti-tumor Drug-radiation Interactions*. Hill BT, Bellamy AS editors. Boca Raton, CRC Press, 1990; 125.
36. Braun DP, Harris JE. Cancer Chemotherapy and it's Impact on the Immune System. In : Hellmann K, Carter SK, editors. *Fundamentals of Cancer Chemotherapy*, New York : Mc Graw-Hill 1987; 77-97.
37. Kaufman SD, Wetzman S,. The clinical pharmacology of anti-cancer drugs. In: Sokol GH, Maickel RP. editors. *Radiation drug interactions in the treatment of cancer* . New York: Wiley Medical, 1980; p.63.
38. Roth YA, Eilber FR, Morton DL. Effect of Adriamycin and high-dose Methotrexate chemotherapy on in vivo and in vitro cell-mediated immunity in cancer patients. *Cancer* 1978;41:814.
39. Noonan FP, Halliday WJ, Wall DR, et al. Cell-mediated immunity and serum blocking factors in cancer patients during chemotherapy and immunotherapy. *Cancer Res* 1977;37:2473.
40. Roit IM. *Essential Immunology*. Fifth Edition. Oxford: Blackwell Scientific Publication, 1986; 260.

---

## POSTOPERATIVE ADJUVANT RADIATION THERAPY IN BREAST CANCER PATIENTS WITH 10 OR MORE POSITIVE AXILLARY LYMPH NODES.

Nan SUNTORNPONG, M.D.

### ABSTRACT

This study was performed to analyse the outcome of postoperative adjuvant radiation therapy (RT) for breast cancer patients with 10 or more involved axillary nodes receiving adjuvant chemotherapy. Seventy - five patients treated at Division of Radiation Oncology, Department of Radiology, Siriraj Faculty of Medicine from January 1978 to March 1995 were retrospectively reviewed with the median follow-up period 25 months. The overall survival and disease-free survival were 54.5 % and 25.9% respectively. Adjuvant RT significantly decreased locoregional disease-free survival but not improved distant disease-free survival or overall survival compared to those of systemic therapy alone. The role of RT on distant control in this high risk group of patients need more studies to be confirmed.

### INTRODUCTION

The most important single factor in determining prognosis of breast cancer is the presence or absence of axillary lymph node involvement. The disease-free survival and overall survival rates of patients are closely related to total number of involved nodes.<sup>1</sup>

Four or more positive axillary nodes is one of the high risk features in breast cancer indicating need for radiation therapy (RT) in addition to chemotherapy.<sup>2</sup> This retrospective study was performed to assess the impact of adjuvant locoregional RT on the management of breast cancer patients with very high number of positive axillary nodes metastases (ie. 10 or more) which is a high risk factor for both locoregional and distant failure.

### MATERIALS & METHODS

One-hundred and seven breast cancer patients with 10 or more positive axillary nodes metastases treated at Division of Radiation Oncology, Department of Radiology, Siriraj Faculty of Medicine between January 1978 and March 1985 were retrospectively reviewed by charts and letters. Thirty-two patients were excluded from the analysis due to incomplete or no adjuvant systemic therapy in 30 and immediately lost after RT in 2.

Of 75 evaluable patients, the median age was 50 years (range 26-78). The pathology in all were invasive ductal carcinoma except scirrhous carcinoma in 1 and invasive apocrine gland in 1. The 1988 AJCC staging system was used to classify in all cases. The patient characteristics divided into 2 groups according to type of postoperative adjuvant therapy were given in Table 1

**Table 1.** Patient characteristics

| Variables                 | Systemic therapy alone<br>No. of patients (%) | Systemic & radiation therapy<br>No. of patients (%) |
|---------------------------|---|---|
| Total no. of patients     | 22  | 53  |
| Age * ≤40                 | 11(21)  | 9(41)   |
| >40                       | 42(79)  | 13(39)  |
| Stage+ II                 | 15(31)  | 9(38)   |
| III, IV #                 | 34(69)  | 15(62)  |
| No. of involved nodes ≤20 | 38(72)  | 13(59)  |
| >20                       | 15(28)  | 9(41)   |

\* Two patients had simultaneous bilateral breast cancer (stage IIIB and IIB, IIIA and IIB)

+ unknown stage in 5 patients

# Stage IV from metastases to supraclavicular node at diagnosis

All patients underwent modified radical mastectomy with neoadjuvant chemotherapy given before surgery in 3 cases (2 stage IIIB and 1 stage IV). The median number of involved axillary nodes in this study was 13 (range 10 to 44).

All patients received adjuvant systemic therapy after surgery with chemotherapy alone in 59, hormonal therapy (Tamoxifen) alone in 10 and combined chemotherapy and hormonal therapy in 6 (Tamoxifen in 5, irradiation castration in 1).

The chemotherapy regimens consisted of CMF (Cyclophosphamide 100mg/m<sup>2</sup> PO day 1-14, Methotrexate 40mg/m<sup>2</sup> IV day 1 and 8, 5-Fluorouracil 600 mg/m<sup>2</sup> IV day 1 and 8, repeated on a 28-day cycle as described by Bonadonna et al<sup>3</sup>) in 52 patients and CAF (C and F as above, Adriamycin 50 mg/m<sup>2</sup> IV day 1 and 8) in 7 patients.

Adjuvant postoperative external radiation therapy (RT) following systemic therapy was delivered to 53 (71%) patients. The treatment volume consisted of chest wall and regional lymph nodes (axillary, internal mammary chain (IMC), supraclavicular node) in all except 2 patients with

T2N1 and T0N2 disease who received only RT to regional lymph nodes. The total dose to each portal was 50 Gy except one patient received boost dose to primary tumor bed to total 66 Gy. All fields were given by Co60 machine with 2 Gy a fraction, 5 fraction a week except IMC in one patient treated by electron. Twenty-two patients in this study received incomplete or no adjuvant RT at all.

The median follow-up period in this study was 25 months (range 3-115 months). The overall survival (OS), locoregional disease-free survival (LRDFS) and distant disease-free survival (DDFS) were estimated by Kaplan-Meier method. Log-rank test were used to determine the variables that univariately predictive of these outcome.

## RESULT

The patient characteristics in this study showed that there were higher proportion of other poor prognostic factors (young age ≤ 40 year, more than 20 positive axillary nodes) in systemic therapy alone group than that in systemic and RT group.

### Pattern of failure

Of the 75 patients, 48 (64%) experienced treatment failure by the time of analysis. The predominant sites were distant-only (69%) while

locoregional-only comprised only 23 % of all failures. The pattern of first failures was shown in Table 2

**Table 2.** Pattern of first failure

| Site of first failure  | Systemic therapy<br>No. of patient | Systemic & RT<br>No. of patient |
|------------------------|------------------------------------|---------------------------------|
| Total no. of patients  | 22                                 | 53                              |
| Locoregional only      | 7                                  | 4                               |
| Distant only           | 10                                 | 23                              |
| Locoregional & distant | 4                                  | -                               |

Twenty-nine (78%) of all first distant failure occurred within 2 years after initial treatment while 13 (87%) of all first locoregional failure occurred within the same period. The median time to first distant and locoregional failure were 20 months (range 2 to 105) and 14 months (range 3-77) respectively.

Three patients in this study developed contralateral breast cancer during follow-up at 8, 12 and 24 months after initial treatment. The pathology were similar to those of previous cancer in all.

### Survival

For all 75 patients, 28 (37%) have died by the time of analysis. The causes of death were un-

known in 3 and from distant metastases to lung in 15, liver in 7 and brain in 3. patients.

The 5-year OS for all patients in this study was 54.5 %. The 5-year DFS was 25.9% (Fig. 1)

Postoperative RT significantly reduced locoregional failure. At 5 years, LRDFS in systemic therapy alone group and combined systemic-RT group were 90.5% and 38.6% respectively ( $P = < 0.001$ ). (Fig.2)

The 5-year DDFS and OS were not different between 2 groups. The DDFS in systemic therapy alone group and combined systemic-RT group were 15.1% and 42.3%. respectively ( $P= 0.09$ ) (Fig.3). The OS were 61.2% and 51.5% respectively ( $P= 0.46$ ) (Fig.4)

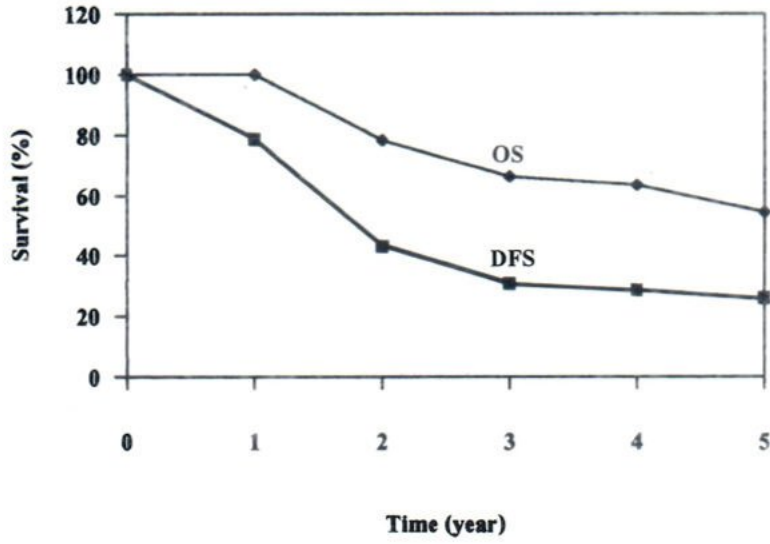


Fig.1 Overall survival and disease-free survival of all patients

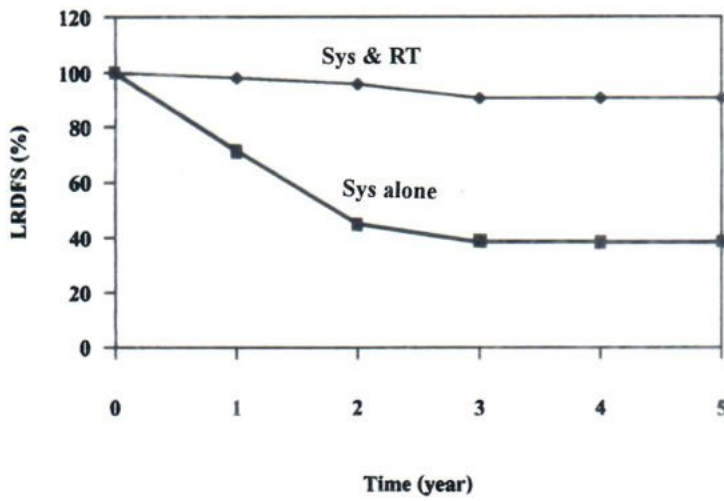


Fig.2 Locoregional disease-free survival of Sys & RT VS Sys alone group

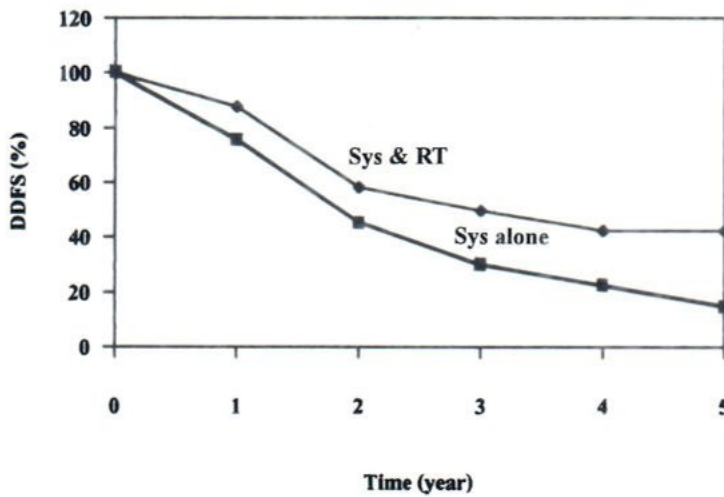


Fig.3 Distant disease-free survival of Sys & RT VS Sys alone group



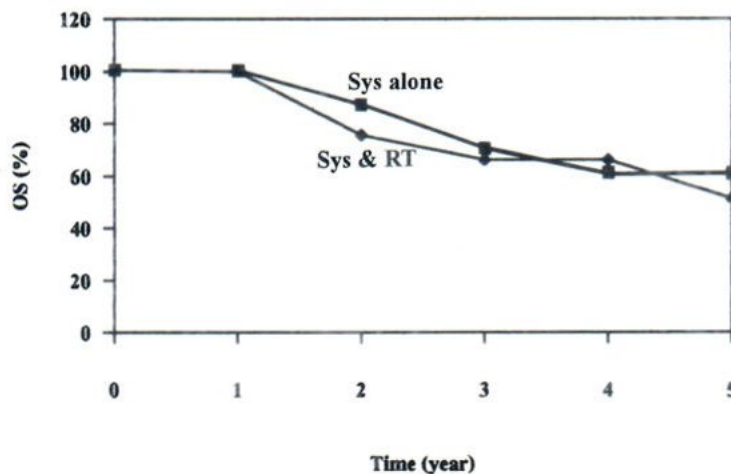


Fig.4 Overall survival of Sys & RT VS Sys alone group

## DISCUSSION

The most consistent prognostic factor for survival and recurrence after primary surgery for operable breast cancer is number of involved axillary nodes. The historical data from randomised trials in patients with 10 or more positive nodes receiving standard dose chemotherapy indicated less than 50% 5-year relapse-free survival rates.<sup>4</sup> The 5-year disease-free survival of the patients given mostly CMF regimen in the present study was 25.9% with 64% of all patients experienced disease failure at least at one site during follow-up period.

The role of RT as an effective modality for locoregional control have been proven by several prospective randomised trials. The 2 most important factors predicting for locoregional recurrence were number of positive nodes and primary tumor size. Locoregional recurrence rates in the patients with 4 or more positive nodes receiving adjuvant CMF regimen without and with RT were 20-64% and 10-22% respectively<sup>5</sup> depending on follow-up time. The LRDFS in this study supported the significant benefit of adjuvant RT.

However, the impact of adjuvant RT on improved distant control and survival from those trials is still controversial. The inconsistent outcome is due to : inadequate number of patients in each study to detect modest benefit, inclusion

of low or intermediate risk patients for whom RT would be minimal benefit, lack of adjuvant systemic therapy and nonqualified RT technique resulting in high complication.

Recently, Overgard et al reported improved DFS and OS by postoperative RT in randomised trial of 1708 high risk premenopausal women receiving CMF irrespective of tumor size, number of involved node or grade.<sup>6</sup> Ragaz et al also reported improved systemic DFS by Adjuvant RT and CMF in 318 node positive premenopausal patients. No significant difference in locoregional and systemic DFS were observed between group of patients with 1-3 and 4 or more positive nodes.

Postoperative RT in this study showed trend to prolong DDFS even no statistic significance reached but this caused no effect on OS. Higher number of patients is required. For more confirmative result. RT technique in this study was similar to that used in general at present. Almost all patients in our division received RT to IMC postoperatively but some were treated by electron instead of photon to reduce cardiac dose. No severe or fatal cardiac complication from RT presented in this study except 3 cases with unknown causes of death.

The selected patients with 10 or more positive nodes have been sparsely studied for benefit of RT. Diab et al studied retrospectively in 618 patients of this criteria. At first, they mentioned that all patients with this very high risk can be assumed to have systemic disease at diagnosis so benefit of RT on distant control and survival should be less expected than that in low risk patients. The result in their study showed significant reduced locoregional failure, improved distant control and OS by combined RT and systemic therapy. They suggested that prolonged survival may be due to decreased secondary systemic spread from improved locoregional control.<sup>8</sup>

Gina et al also reported benefit of RT on locoregional failure and DFS in this high risk patients when combined with adjuvant chemotherapy including high dose regimen with autologous reserve.<sup>9</sup>

The standard adjuvant therapy for patients with 10 or more positive nodes at present is still conventional doxorubicin-based chemotherapy. The results of high dose chemotherapy with hematopoietic stem-cell support from 2 recent randomised trials<sup>10, 11</sup> contradicted the promising early results. Therefore, it should not be given in routine clinical practice now. If the benefit of RT on distant control and survival in this group of patients can be proven consistently in the future, its role can be considered as part of the intensive therapy for the patients with very poor prognostic factor.

## REFERENCES

1. Nenoto T, Vana J, Bedwan R et al. Management and survival of female breast cancer : results of a national survey by the American College of Surgeon. *Cancer* 1980; 45: 2917-21.
2. Perez CA, Fields JN. Role of radiation therapy for locally advanced and inflammatory carcinoma of the breast. *Oncology* 1987; 1: 81-90.
3. Bonadonna G, Brusamolino E, Valagussa P et al. Combination chemotherapy as an adjuvant treatment in operable breast cancer. *N Eng J Med* 1976;294 :405-10.
4. Perez CA, Taylor ME .Breast: Tis, T1 and T2 Tumors. In : Perez CA, Brady LW (eds), *Principles & Practice of Oncology*, 3<sup>rd</sup> ed. J.B. Lippincott Co. 1997: 1269-1414.
5. Fowble B. Postmastectomy radiation : then and now. *Oncology* 1997; 11:213-31.
6. Overgaard M, Hansen PS, Overgaard J et al. Postoperative radiotherapy in high risk premenopausal women with breast cancer who receive adjuvant chemotherapy. *N Eng J Med* 1997; 337:949-55
7. Ragaz J, Jackson SM, Le N et al. Adjuvant radiotherapy and chemotherapy in node-positive premenopausal women with breast cancer. *N Eng J Med* 1997;337: 956-62.
8. Diab SG, Hilsenbeck SG, Moor C et al. Radiation therapy and survival in breast cancer patients with 10 or more positive axillary lymph nodes treated with mastectomy. *J Clin Oncol* 1998;16:1655-60.
9. Jabro G, Wazer D, Erban J et al. The importance of locoregional radiotherapy with conventional or high dose chemotherapy in the management of breast cancer with  $\geq 10$  positive axillary nodes. *Proc ASTRO* 1997; 39:( abstr.2045)
10. Hortobagyi GN, Bazdar AU, Chaplin R et al. Lack of efficacy of adjuvant high-dose (HD) combination chemotherapy (CT) for high-risk primary breast cancer. (HRPBC: a randomised trial) .*Proc ASCO* 1998;17: (abstr 417).
11. Rodenhuis S, Richel DJ, Wall E et al. Randomised trial of high-dose chemotherapy and haemopoietic progenitor-cell support in operable breast cancer with extensive axillary lymph-node involvement. *Lancet* 1998; 352: 515-19

---

## COLON CANCER: RADIOGRAPHIC FINDINGS DETECTED BY BARIUM ENEMA.

**Chalida APHINIVES, M.D., Sukhonta SANMAHACHAI, M.D.,  
Jitjaroen CHAIYACUM, M.D., Eimorn MAIRIANG, M.D.,  
Jiraporn SRINAGARIND, M.D., Vallop LAOPAIBOON, M.D.**

**OBJECTIVE :** To determine the radiographic findings detected by barium enema in the patients of colon cancer.

**DESIGN :** Retrospective, descriptive study.

**SETTING :** Department of Radiology, Faculty of Medicine, Khon Kaen University.

**SUBJECTS :** All patients of colon cancer performed barium enema between January 1993 and February 1998.

**DATA COLLECTION :** Review from medical records, endoscopic notes, radiographic reports, operative notes, and pathological reports.

**MEASUREMENT :** Descriptive statistics, including number, means, and percentages.

**RESULTS :** One hundred and eighteen patients were reviewed. No asymptomatic patients found. Seventy-nine patients (66.95%) had annular lesions, 29 (24.58%) had semiannular lesions, 4 (3.39%) had polypoid lesions, 6 (5.08%) had other lesions. Sixty-four patients (54.24%) had lesions in the sigmoid colon or below, and 54 (45.76%) had lesions more proximally in the colon. Four patients (3.39%) had Dukes' stage A lesions; 29 (24.58%), stage B lesions; 43 (36.44%), stage C lesions; 42 (35.59%), stage D lesions. All patients of Dukes' stage A had polypoid lesions.

**CONCLUSIONS :** Almost all patients had annular or semiannular lesions. Polypoid lesions related directly to Dukes' stage A (100%).

Some foreign researches demonstrated the detection rate of colon cancer by barium enema examination.<sup>1-3</sup> Some studies demonstrated the pattern of radiographic findings correlated with the pathologic findings, esp. in the early colon cancer.<sup>4-7</sup> However, Thai life style differs from the

western style, as we know. So we have to focus on the late cases instead of the early ones. The purpose of this study is to demonstrate the pattern of radiographic findings found in the patients living in northeast part that has the lowest economic status in Thailand.

## MATERIALS AND METHODS

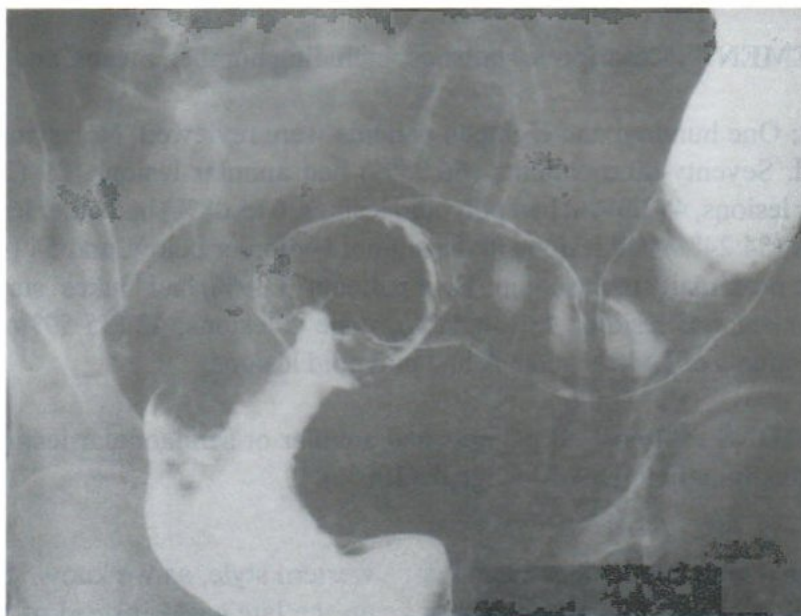All patients of colon cancer performed double-contrast barium enema examinations between January 1993 and February 1998 were included in this study. Medical records, endoscopic notes, radiographic reports, operative notes, and pathologic reports were reviewed. Clinical parameters that were evaluated included signs and symptoms such as bowel habit change, mucous bloody stool, weight loss, abdominal mass, abdominal pain or distention, constipation.

The pattern of radiographic findings was divided into 4 groups that were annular (figure 1), semiannular (figure 2), polypoid, and other lesions. The semiannular lesions represented all varied lesions between polyp and annular lesion, i.e. polypoid mass (figure 3) that was more than 2 cm in

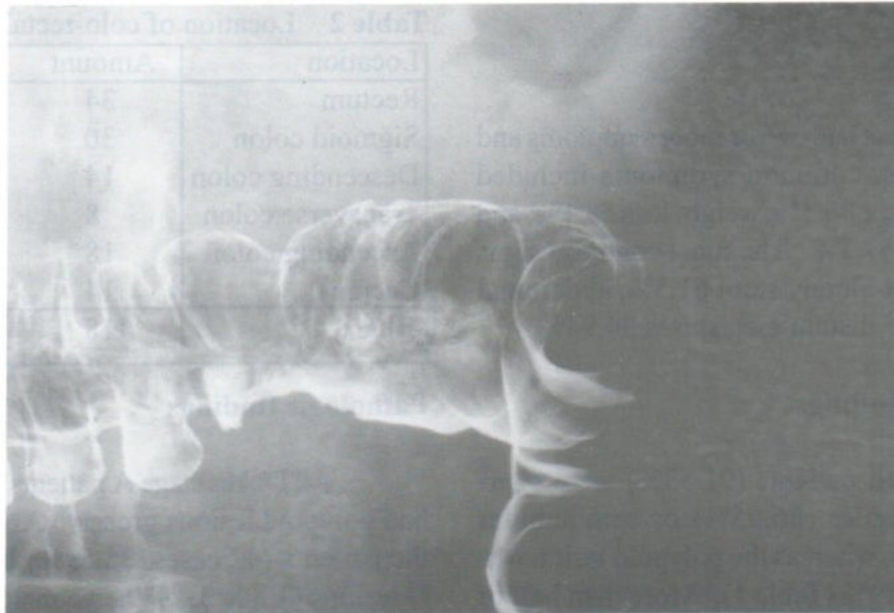greatest dimension, intraluminal mass, saddle mass (one-third to one-half of circumference). In this study, ulcerated lesions were not divided into separate group but included in annular or semiannular groups instead. The last group included the remaining lesions besides the first three groups; e.g. scirrhous lesion, submucosal lesion, etc.

Dukes' staging was used to classify the pathologic findings.<sup>8</sup> Tumor confined to mucosa was Dukes' stage A; tumor confined to serosa was stage B; tumor with local lymph node metastases was stage C; and distant metastases was stage D.

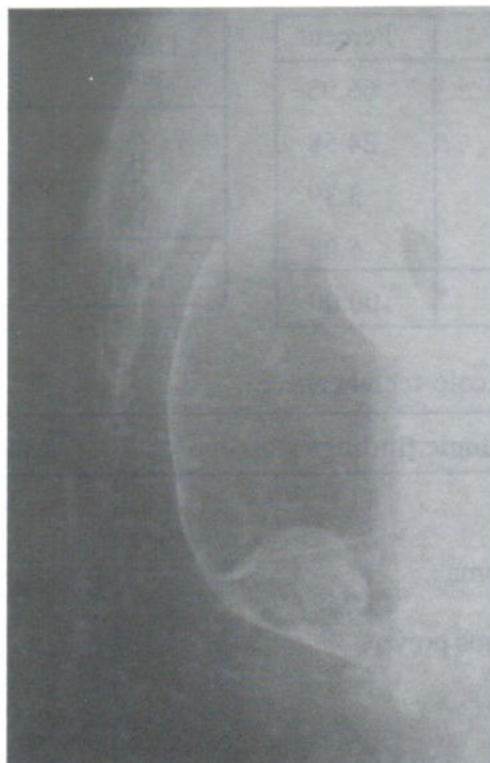The descriptive statistics (number, means, and percentages) were used to analyze the data.



**Fig.1** Annular lesion. Spot radiograph of the mid-rectum showed a circumferential mass, 5 cm long, which was a classic core appearance.



**Fig.2** Semiannular lesion. Spot radiograph of splenic flexure of colon showed a 3-cm saddle lesion that was straddle one-third of circumference of the mesenteric site of distal part of transverse colon.



**Fig.3** Polypoid lesion. Prone cross-table rectal film showed a 3-cm polypoid mass at posterior aspect of lower rectum with a broad base and lobulated surface.

**RESULTS**

**Clinical findings**

All patients had one or more symptoms and signs. The most common symptoms included bowel habit change 86.3%, weight loss 58.1%, and abdominal pain 57.3%. The most common signs included mucous bloody stool 61.5%, abdominal mass 38.5%, and distant metastases 34.94%.

**Radiographic findings**

Almost all patients (91.53%) were characterized as annular (66.95%) or semiannular (24.58%) lesions, whereas the polypoid lesion was found in only 3.39% (Table 1). More than half of the patients (54.24%) had lesions locating at sigmoid colon or below, whereas the remainder (45.76%) located above that part. (Table 2).

**Table 1** Morphology detected by barium enema.

| Morphology  | Amount | Percent |
|-------------|--------|---------|
| Annular     | 79     | 66.95   |
| Semiannular | 29     | 24.58   |
| Polypoid    | 4      | 3.39    |
| Other       | 6      | 5.08    |
| Total       | 118    | 100.00  |

**Table 4** Histologic findings of colo-rectal cancer.

| Histologic findings                 | Amount | Percent |
|-------------------------------------|--------|---------|
| Adenocarcinoma                      | 104    | 88.14   |
| Mucinous adenocarcinoma             | 2      | 1.69    |
| Mucin producing adenocarcinoma      | 2      | 1.69    |
| Signet ring cell                    | 2      | 1.69    |
| Adenocarcinoma in adenomatous polyp | 2      | 1.69    |
| Carcinoid                           | 1      | 0.85    |
| Papillary adenocarcinoma            | 1      | 0.85    |
| Mucinous cystadenocarcinoma         | 1      | 0.85    |
| Liposarcoma                         | 1      | 0.85    |
| Leiomyosarcoma                      | 1      | 0.85    |
| Carcinoma NOS                       | 1      | 0.85    |

**Table 2** Location of colo-rectal cancer.

| Location         | Amount | Percent |
|------------------|--------|---------|
| Rectum           | 34     | 28.82   |
| Sigmoid colon    | 30     | 25.42   |
| Descending colon | 14     | 11.87   |
| Transverse colon | 8      | 6.78    |
| Ascending colon  | 18     | 15.25   |
| Cecum            | 14     | 11.86   |
| Total            | 118    | 100.00  |

**Pathologic findings**

All Dukes stage A patients (4 cases, 3.39%) had polypoid lesions grossly. About one-third of the patients (42 cases, 35.59%) had Dukes stage D lesions (Table 3). When considering the histologic findings, most specimens showed adenocarcinoma (88.10%), the remaining were distributed in 1 or 2 cases in each types. (Table 4)

**Table 3** Pathologic staging of colo-rectal cancer.

| Dukes stage | Amount | Percent |
|-------------|--------|---------|
| A           | 4      | 3.39    |
| B           | 29     | 24.58   |
| C           | 43     | 36.44   |
| D           | 42     | 35.59   |
| Total       | 118    | 100.00  |

## DISCUSSION

At our institution, there were three differences from other studies. Firstly, all of our patients underwent barium enema examination because of significant symptoms and signs.<sup>6</sup> Secondly, almost all patients had annular or semiannular lesion.<sup>6</sup> Finally, one-third of patients had advanced stage (Dukes D) of cancer.<sup>6-7</sup> However, there were also two similarities. Firstly, Dukes stage A was found only in 3-4%. And around half of patients could be detected lesions by using barium enema and sigmoidoscopy.<sup>6</sup>

The American Cancer Society, the American College of Physicians, and the National Cancer Institute all currently recommend fecal occult blood testing every year and flexible sigmoidoscopy beginning at age 50 years every 3-5 years for colon cancer screening. Perhaps eating behavior or other factors, the incidence of colon cancer in Thailand is increasing, esp. in the town people.

Although very few screening examinations have been performed at our hospital, we encourage that these should be considered increasingly. Because more early lesions, better prognoses are received. Patients with Dukes stage A have survival rate almost equal to age-matched subjects without colon cancer. Patients with Dukes stage B have 5-year survival rate of 80-85%. Patients with Dukes stage C have 5-year survival rate of about 70%. And patients with Dukes stage D have 5-year survival rate of only 6-14%.<sup>7,9</sup> When considering the half of the patients who can be detected by barium enema and sigmoidoscopy (lesions below rectosigmoid junction). Because the barium enema and sigmoidoscopes are available in almost all provincial hospital, cancer lesions can be detected earlier.

Similar to other studies.<sup>6-7</sup>, the morphology correlated to the pathology was confined to the polypoid lesion which had the early stage of cancer (Dukes A).

## CONCLUSIONS

Almost all patients had annular or semiannular lesions. Barium enema and sigmoidoscopy that were available at all provincial hospital in Thailand could detect half of the patients of colo-rectal carcinoma. Polypoid lesions related directly to Dukes stage A (100%).

## REFERENCES

1. Johnson CD, Carlson HC, Taylor WF, Welland LP. Barium enema of carcinoma of the colon: sensitivity of double- and single-contrast studies. *AJR* 1983;140:1143-1149.
2. Kelvin FM, Gardiner R, Vas W, Stevenson GW. Colorectal carcinoma missed on double-contrast barium enema study: a problem in perception. *AJR* 1981;137:307-313.
3. Ott DJ, Gelfand DW, Chen YM, Munitz HA. Single-contrast vs double-contrast barium enema in the detection of colonic polyps. *AJR* 1986;46:993-996.
4. Ekelund G, Lindstrom C, Rosengren JE. Appearance and growth of early carcinomas of the colon-rectum. *Acta Radiol* 1974;15:670-679.
5. Skucas J, Spataro R. The radiographic features of small colonic cancers. *Radiology* 1982;143:335-340.

6. Peter AM, Stephen ER, Marc SL, Curtis PL, Igor L, Emma EF, Hans H. Colon cancer: morphology detected with barium enema examination versus histopathologic stage. *Radiology* 1995;197:683-687.
7. Zinkin LD. A critical review of the classification and staging of colorectal cancer. *Dis Colon Rectum* 1983; 26:37-43.
8. Dukes C. The classification of cancer of the rectum. *J Pathol Bacteriol* 1932;35: 323-332.
9. Boring CC, Squires TS, Tong T. Cancer statistics, 1992. *CA* 1992;42:19-38.



---

## **DIVERTICULAR DISEASE OF THE COLON IN THAILAND : “ INCIDENCE AND DISTRIBUTION ”**

**Kamolwan JUNGMEECHOKE**

### **ABSTRACT**

Of a total 1051 barium enemas performed in Bumrungrad Hospital and Pramongkutklao Hospital in 1995-1996, 13.5% showed colonic diverticulosis. Right colon was the most common site, 53.52%; while left colon was involved in 14.78% and bilateral involvement was 30.11%. This is different from western countries where the disease is predominantly on the left. Our study also showed that right sided colonic diverticulosis was more common in younger age group and more predominant in men.

### **INTRODUCTION**

Colonic diverticulosis is common in western countries and is predominantly left sided.<sup>1</sup> In Thailand, there was only one study in 1980 done by Vajrabukka et al<sup>2</sup> which showed the incidence of 4.2% with predominance of right sided disease. The number of cases in the study was small and all were symptomatic. This together with cases of right sided diverticulitis we found more frequently, prompted us to do this study to determine the incidence and distribution of colonic diverticular disease in Thailand in a larger number of cases including both symptomatic and asymptomatic population.

### **PATIENTS AND METHODS**

Prospective survey of colonic diverticular disease of the patients who had barium enema examination in Bumrungrad hospital from November 1995 to August 1996 and in Pramongkutklao hospital from November 1995 to June 1996 were done. Foreigners were excluded from the study.

The patients came from both Bangkok and urban areas.

All patients received barium enema examinations because of having one or more of the following symptoms: abdominal pain, change of bowel habit, bloody stool, positive occult blood test of feces, anemia, weight loss and suspected colonic malignancy, or for checking up.

Total number of barium enema examination in the study was 1051. There was one patient with diverticulosis but whose entire colon was not visualized from previous partial colectomy. This patient was not included in the table of “site of diverticular disease”.

Diverticular disease was divided into three types: (1) right sided with diverticula at the cecum, ascending and proximal transverse colon; (2) left sided with diverticula at distal transverse, descending and sigmoid colon.; and (3) bilateral type.; the same as in the study of Nakada<sup>3</sup>

**RESULTS**

**INCIDENCE AND SEX**

Among 1051 patients receiving barium enema examinations, colonic diverticular disease was found in 142 patients (13.51%), including 81 males (57.04%) and 61 females (42.96%).

**AGE**

The age range and mean age of patients with colonic diverticulosis were 26-92 years and 59.15 years respectively.

**DISTRIBUTION OF THE DIVERTICULI (TABLE 1)**

There were involvement of the right colon in 53.52% of the cases. The mean age of this group was 55.57 years.

Left-sided disease was found in 14.78%. The mean age of this group was 63.7 years.

In the remaining 30.99%, there was bilateral type with mean age of 62.06 years.

Our patients with right-sided disease were younger than the patients with left-sided disease by about 8 years.

Right-sided disease was more prevalent in men; while left-sided and bilateral types involved almost equal in male and female populations.

**Table 1** Site of Diverticular Disease

|            | Right-sided | Left-sided | Bilateral |
|------------|-------------|------------|-----------|
| Total (n)  | 76          | 21         | 44        |
| % of total | 53.52       | 14.78      | 30.99     |
| Age range  | 26-92       | 43-84      | 43-87     |
| Mean age   | 55.57       | 63.7       | 62.06     |
| Sex        |             |            |           |
| -male(%)   | 61          | 50         | 51        |
| -female(%) | 39          | 50         | 49        |

**SINGLE DIVERTICULAR DISEASE (TABLE 2, 3)**

Of 1,051 barium enema examinations performed, 21 cases (1.9%) revealed single diverticulum of the colon. This was 4% of all colonic diverticular disease. Age range and mean age of this group were 26-79 and 59.4 years. It was slightly more prevalent in men, and it was more common in the right-sided colon with roughly equal distribution at cecum, ascending colon and at hepatic flexure.

**Table 2** Site of Single Colonic Diverticulum

|           | Right-sided | Left-sided | Total |
|-----------|-------------|------------|-------|
| Number    | 16          | 5          | 21    |
| Percent   | 76.19       | 23.81      | 100   |
| Age range | 26-79       | 46-65      | 26-79 |
| Mean age  | 53.6        | 56.8       | 59.4  |
| Sex F:M   | 7:8         | 2:3        | 9:11  |

**Table 3** Site of Single Right-Sided Diverticulum

|                 | Number | Percent |
|-----------------|--------|---------|
| Cecum           | 6      | 37.5    |
| Ascending colon | 6      | 37.5    |
| Hepatic flexure | 4      | 25      |

**Table 4** Distribution of Diverticular Disease in Patients Younger Than 40 Years Old.

|                  | Single | Multiple(Number) |
|------------------|--------|------------------|
| Cecum            | 3      | 1(4)             |
| Ascending colon  | 1      | 1(2)             |
| Left-sided colon | 0      | 0                |

## COLONIC DIVERTICULAR DISEASE IN PATIENTS YOUNGER THAN 40 YEARS OLD (TABLE 4)

In our study, there were 6 patients with colonic diverticular disease who were younger than 40 years old. Male: female was 1:1. Age range was 26-39 years old. All of these six cases were right-sided disease; with single diverticulum in 4 cases and multiple ones in 2 cases.

## DISCUSSION

The incidence of colonic diverticulosis in our study was 13.51 %. This is lower than in the United States<sup>1</sup> (30% in age over 50 and 50% in age over 70), and slightly lower than in Singapore<sup>4,5</sup> (19-20%) and Japan<sup>6</sup> (15.7%), developed countries of Asia but much higher than Vajrabukka's study<sup>2</sup>. The incidence of the colonic diverticulosis is highly suspected to depend on eating habits (usually found in societies with low fiber diets); as seen in the study of Nakada et al.<sup>3</sup>, Stemmermann and Yatani<sup>7</sup>. Nakada et al.<sup>3</sup> showed that as lifestyle in Japan had changed, the incidence of this disease had been steadily increasing during the past ten years. Stemmermann and Yatani<sup>7</sup> showed that Japanese Hawaiians had higher incidence of the disease than Japanese. This may be the reason for our low incidence. However, with changing of eating habit and diet intake of more western food by the Thai population, the incidence of colonic diverticular diseases may increase in the future and further study is still needed.

Colonic diverticular disease in Thailand is predominantly right-sided type; the same as in Singapore,<sup>4</sup> Japan,<sup>5</sup> Hong Kong<sup>8</sup> and Korea.<sup>9</sup> On the contrary, it is predominantly left-sided in the United States,<sup>1</sup> European countries,<sup>10</sup> India<sup>11</sup> and Jordan.<sup>10</sup> Our study also showed that right-sided diverticulosis was more common in younger age

group and more predominant in men; the same as in Japan and Singapore. These suggest that the race may have a role in determining predominant site, age and gender distributions of colonic diverticular disease.

About single colonic diverticulum, there are two possibilities. Some studies<sup>12</sup> believed that it was a separate entity from multiple diverticulosis because of different site and age distributions. That is it's predominantly involved right-sided colon especially the cecum<sup>13</sup> and usually found in younger age group, about ten years earlier than left-sided multiple colonic diverticulosis.<sup>14</sup> Pathologically it was true diverticulum, consisting of all layers of intestinal wall including the muscular layer. It was thought to be congenital in origin. While others<sup>4,15</sup> showed that it was false diverticulum, comprising only mucosa and submucosa herniating through the muscular wall, and was acquired, the same entity as multiple diverticulosis. This includes the study of Lee<sup>4</sup> from Singapore which pathologically showed that all of the single diverticuli in his study (39 cases) were false type. In our study, the incidence of single colonic diverticulum was 1.9%. and was predominantly right-sided with age distribution following the pattern of right-sided multiple colonic diverticular disease. Cecum was involved only about one-third of cases and there were both single and multiple types of colonic diverticulosis in patients younger than 40 years old. From these informations, it is more suggestive that single and multiple colonic diverticulosis are parts of the spectrum of the same disease rather than a separate entities.

Lastly because colonic diverticular disease in Thailand is more common to be right-sided and right-sided diverticulitis is not rare, right-sided diverticulitis should always be in the differential diagnosis of right lower quadrant abdominal pain.

## REFERENCES:

1. Cheskin LJ, Bohlman M, Schuster MM. Diverticular disease in the elderly. *Gastroenterology Clinic of North America* 1990; 19:391-403.
2. Vajrabukka T, Sakornchai K, Jimakorn P. Diverticular disease of the colon in a far-eastern community. *Dis Colon Rectum* 1980;23:151-154.
3. Nakada I et al. Diverticular disease of the colon at a regional general hospital in Japan. *Dis Colon Rectum* 1995;38:755-759.
4. Lee VS. Diverticular disease of the large bowel in Singapore. An autopsy survey. *Dis Colon Rectum* 1986;29:330-335
5. Chia JG, Wilde CC, Ngoi SS, Gok PM, Ong CL. Trends of diverticular disease of the large bowel in a newly developed country. *Dis Colon Rectum* 1991;34:498-501.
6. Sugihara K, Muto T, Morioka Y, Asano A, Tamamoto T. Diverticular disease of the colon in Japan. A review of 615 cases. *Dis Colon Rectum* 1984;27:531-537.
7. Stemmermann GN, Yatani R. Diverticulosis and polyps in the large intestine. A necropsy study of Hawaii Japanese. *Cancer* 1973;31:1260-1270.
8. Coode PE, Chan KW, Chai YT. Polyps and diverticula of the large intestine. A necropsy survey in Hong Kong. *Gut* 1985; 26:1045-1048.
9. Munakata A, Nakaji S, Yoshida Y, Han NC, Choi WK. Study on the diverticular disease of the colon in Korea. *J Jap Soc Coloproct* 1982;35:224-231.
10. Fatayer WT, A-Khalaf MM, Shalan KA, Toukan AU, Daker MR, Arnaout MA. Diverticular disease of the colon in Jordan. *Dis Colon Rectum* 1983;26:247-249.
11. Kochhar R, Goenka MK, Nagi B, Bhasin DK, Mehta SK. The emergence of colonic diverticulosis in urbanised India. A report of 23 cases. *Trop Geogr Med* 1989; 41:254-256.
12. Mariani G, Tedoli M, Dina R, Giacomini I. Solitary diverticulum of the cecum and right colon. *Dis Colon Rectum* 1987;30: 626-629.
13. Magness LJ, Sanfelippo PM, Hurden JA, Judd SS. Diverticular disease of the right colon. *Surg Gynecol Obstet* 1975;140:30-31.
14. Sardi A, Gokli A, Singer JA. Diverticular disease of the cecum and ascending colon. A review of 881 cases. *Am Surgeon* 1987; 53: 41-45.
15. Hughes LE. Postmortem survey of diverticular disease of the colon. *Gut* 1969;10: 336-351.

## ANGIOGRAPHIC FINDINGS OF HEPATOCELLULAR CARCINOMA IN SIRIRAJ HOSPITAL

**KRUATRACHUE Chutakiat,MD., PRABHASAVAT Krisdee,M.D.  
IEMSAWATDIKUL Kriengkrai,M.D., VANAPRUNKS Saroj,M.D.  
CHAIYASOOT Walailak,M.D., DANPUKDEE Kanjana,M.D.**

### ABSTRACT

Five years collection of 126 cases of celiac and hepatic angiography of hepatocellular carcinoma were done and analysed in the aspects of sex, age and angiographic findings, such as, neovascularity, vascular distortion, etc. The most common finding was neovascularity(88%), the least findings were avascularity(5%), and normal angiographic finding(5%). Comparison between eighteen cases of pathological diagnosis with the other study was also performed.

### INTRODUCTION

Hepatocellular carcinoma is the most common primary malignant tumor of liver, responsible for at least one million death per annum world-wide.<sup>1</sup> It is common in Africa and South East Asia but relatively uncommon in United States and Europe. In United states, hepatocellular carcinoma constituting only 1-2.5 % of all cancer.<sup>2</sup>

In Thailand, liver cancer is the most frequent cancer in males and the third in females.<sup>3</sup> The geographic distribution of liver cancer closely related to viral hepatitis, mycotoxin, cirrhosis.

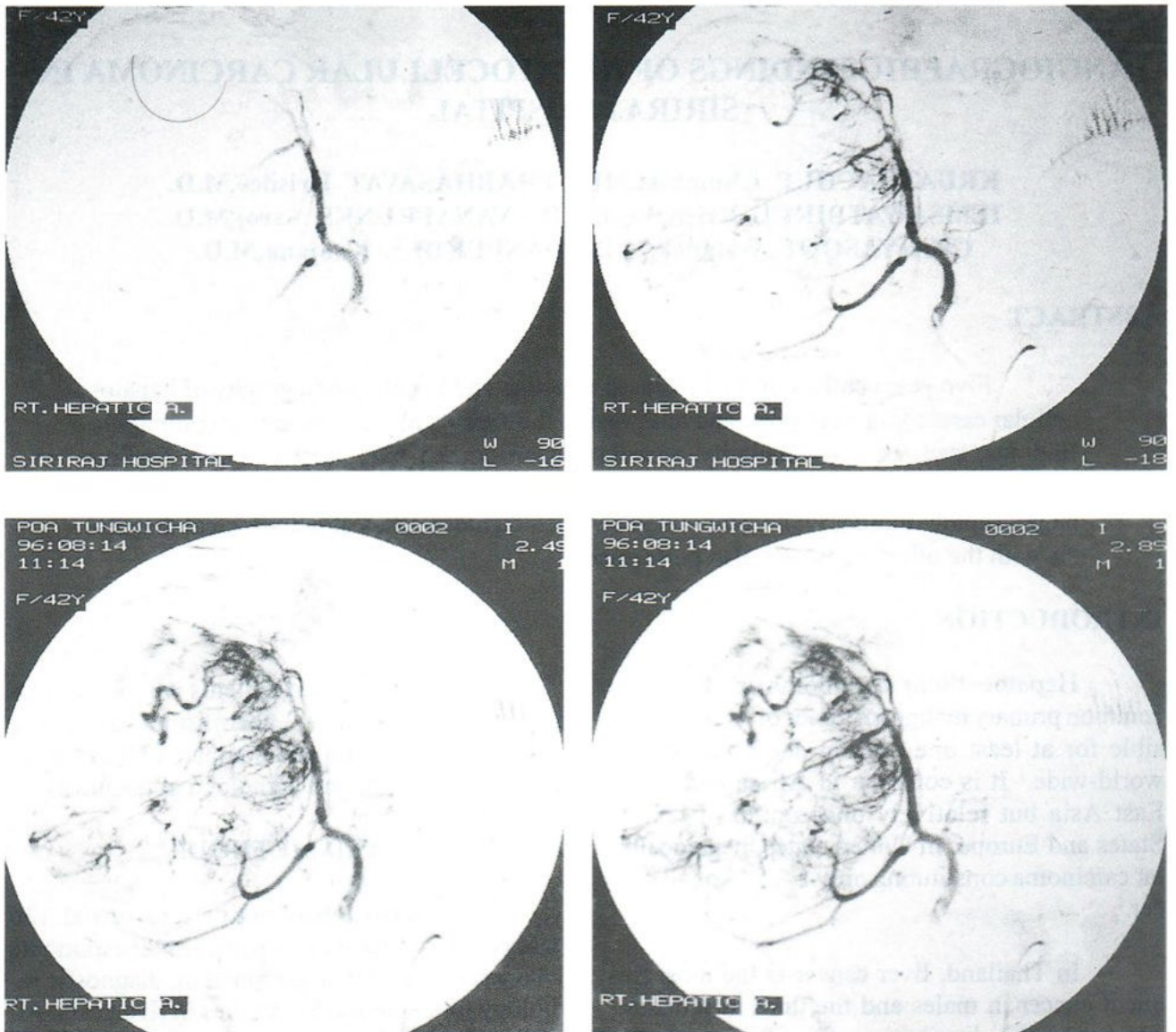
There are many radiological methods for detecting hepatocellular carcinoma such as ultrasonography, CT scan, CT arterial portography, CT with lipiodol and angiography. However, the main role of arteriography in modern radiological practice is for planning and performing the treatment of hepatocellular carcinoma : this modality is in fact important in assessing the surgical resectability, providing the vascular road map for surgery and chemoembolization, when the surgery is not indicated.<sup>4</sup>

We had analyzed patients who were diagnosed to have liver carcinoma by using angiographic method and compared all of the results with surgical and pathological diagnosis.

### MATERIALS AND METHODS

We have retrospectively reviewed 126 cases of known case of hepatocellular carcinoma who were referred to department of diagnostic radiology for angiographic studies in five years. All patients were evaluated by both celiac and superior mesenteric angiography to search for abnormality such as neovascularity, vascular distortion, vascular encasement, irregularity of vascular margin, arterio-venous shunting and portal vein invasion or portal vein thrombosis. All of angiographic films were reviewed by two experienced radiologists without knowing the final diagnosis.

Finally, in all patients, the diagnoses were confirmed by using peritoneoscopy, surgical biopsy, laboratory studies or pathological evidence. After collection of all data, they were analyzed by statistical methods.



**Fig 1** The hepatic angiograms show displacement of hepatic artery branches encircle the large intra-hepatic tumor mass, there are also demonstration of neovascularity in the mass regions.

**RESULT**

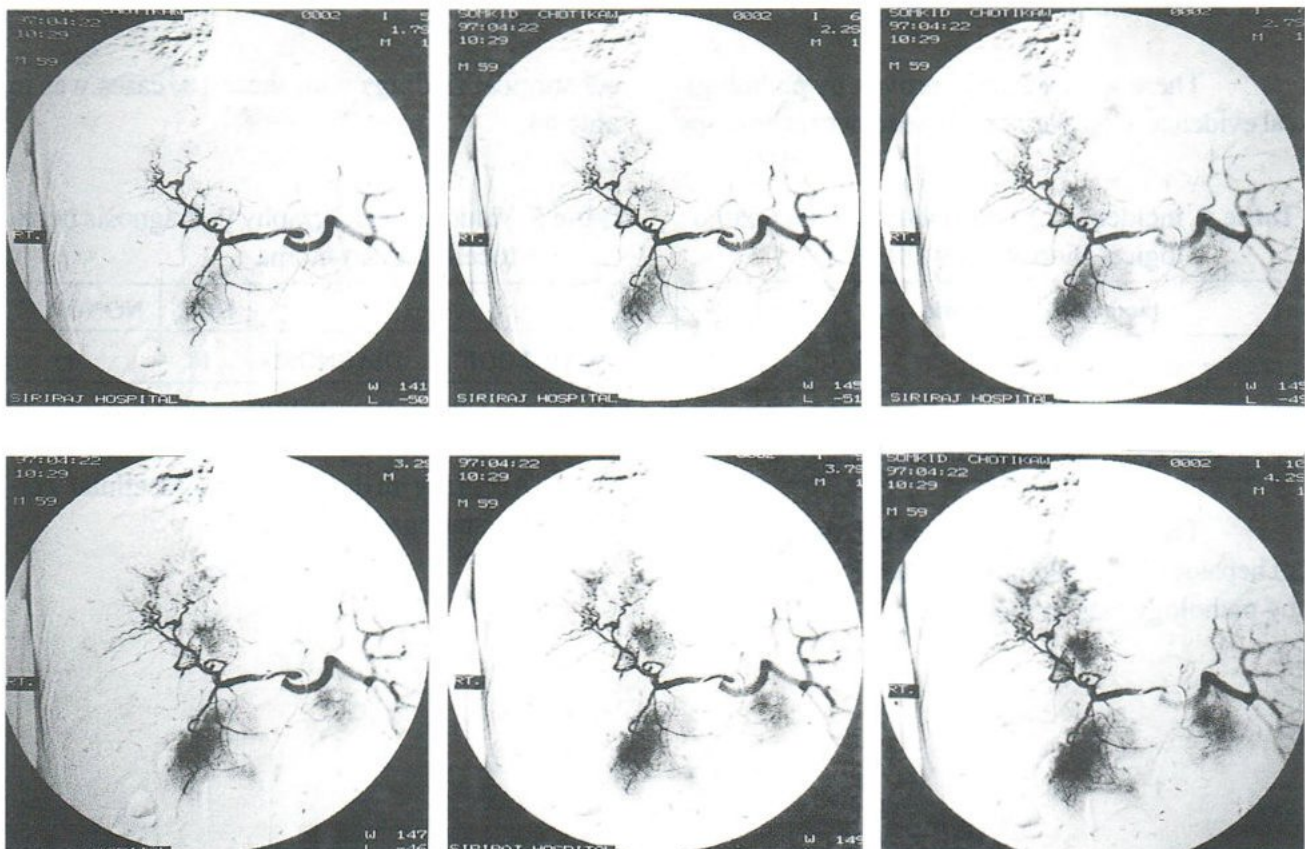
In all of 126 cases, the incidences of sex, age and angiographic findings were demonstrated in the tables below :

**Table 1.** sex incidence

| Sex    | Number |
|--------|--------|
| Male   | 84     |
| Female | 42     |

**Table 2.** age incidence

| Age range | Number |
|-----------|--------|
| 1 - 10    | 0      |
| 11 - 20   | 0      |
| 21 - 30   | 21     |
| 31 - 40   | 28     |
| 41 - 50   | 35     |
| 51 - 60   | 35     |
| 61 - 70   | 7      |
| 71 - 80   | 0      |



**Fig 2** Celiac angiography shows multiple areas of abnormal staining in both lobes of the liver.

**Table 3.** angiographic finding ( N= 18)

| FINDING                                  | NUMBER    |
|--|-----------|
| neovascularity                           | 112 (88%) |
| vascular distortion                      | 105 (83%) |
| vascular pooling                         | 72 (66%)  |
| vascular encasement                      | 35 (27%)  |
| irregular margin                         | 56 (44%)  |
| AV shunting                              | 42 (33%)  |
| portal vein thrombosis                   | 7 (5%)    |
| avascularity                             | 7 (5%)    |
| normal finding (No abnormality detected) | 7 (5%)    |

There were 18 cases proven by pathological evidence. Comparison between peritoneoscopy

and surgical findings with these 18 cases was in table #4.

**Table 4** incidence of peritoneoscopy and pathological biopsy (N= 18)

| methods of diagnosis                    | Number |
|---|--------|
| positive peritoneoscopy                 | 6      |
| positive surgical finding               | 7      |
| not proven by peritoneoscopy or surgery | 5      |

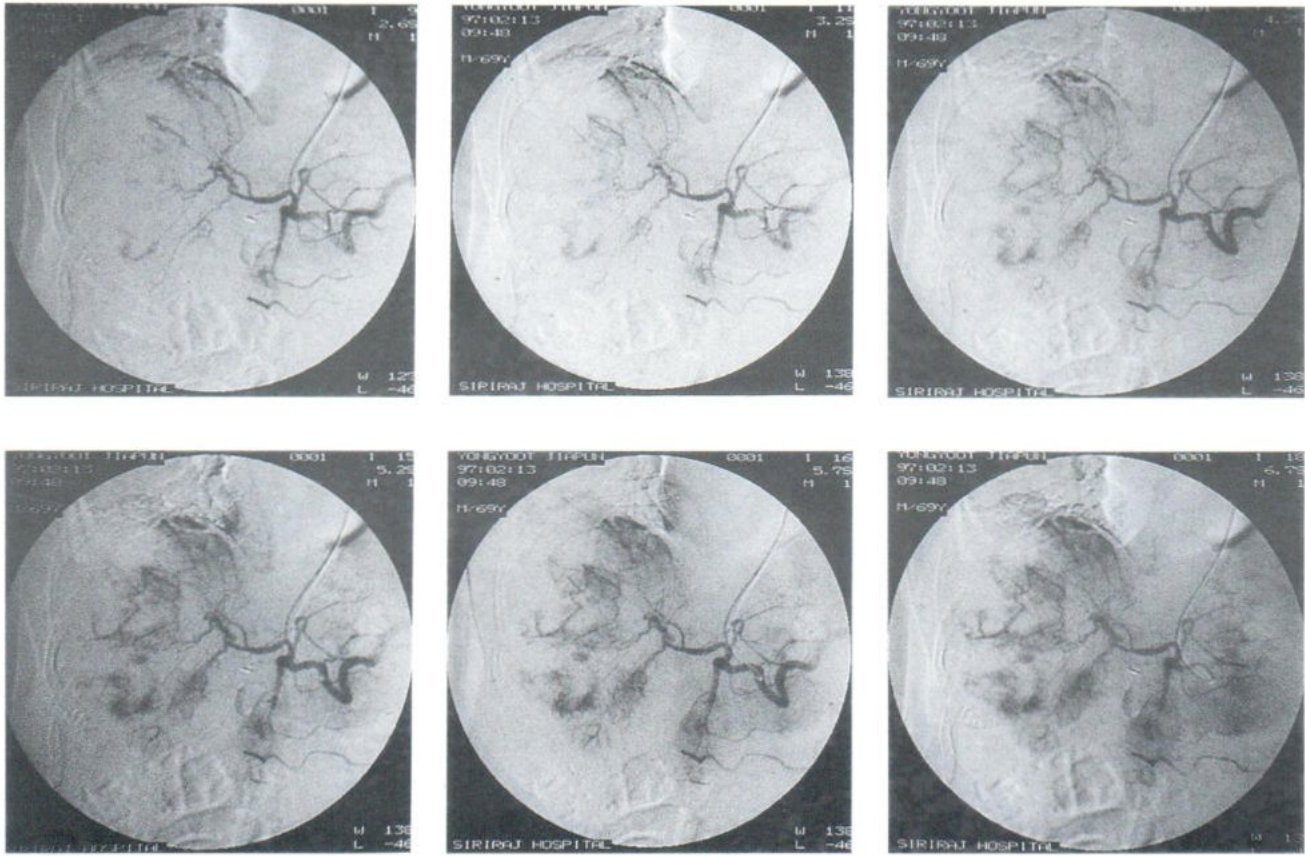
The value of angiography in the diagnosis of hepatocellular carcinoma in the 18 cases, proven by pathology was in the Table #5.

**Table 5** Value of angiography in diagnosis hepatocellular carcinoma

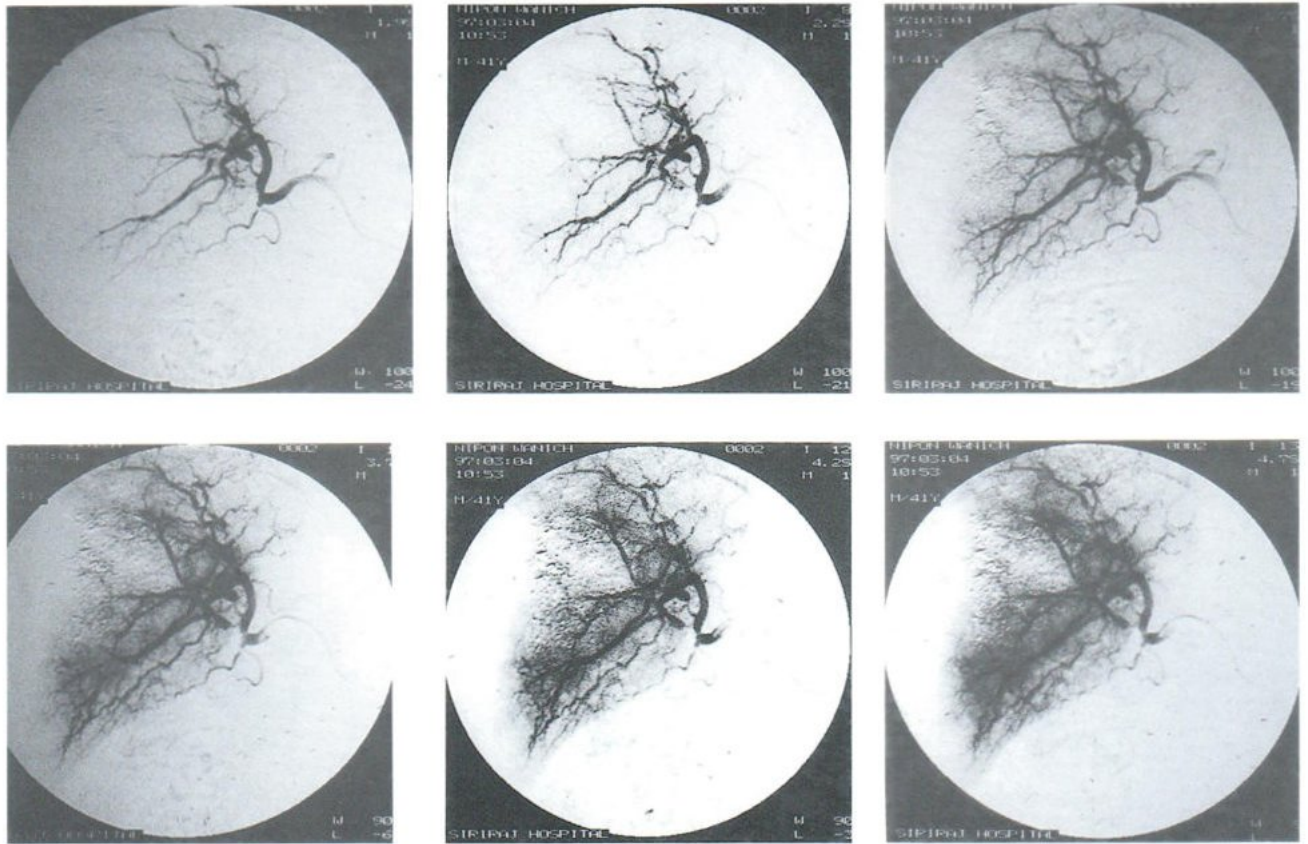
|                        | HCC | NON-HCC |
|------------------------|-----|---------|
| PATHOLOGICAL DIAGNOSIS | 18  | 0       |
| ANGIOGRAPHIC DIAGNOSIS | 17  | 1       |

Accuracy in diagnosis hepatocellular carcinoma by angiography is 94 %

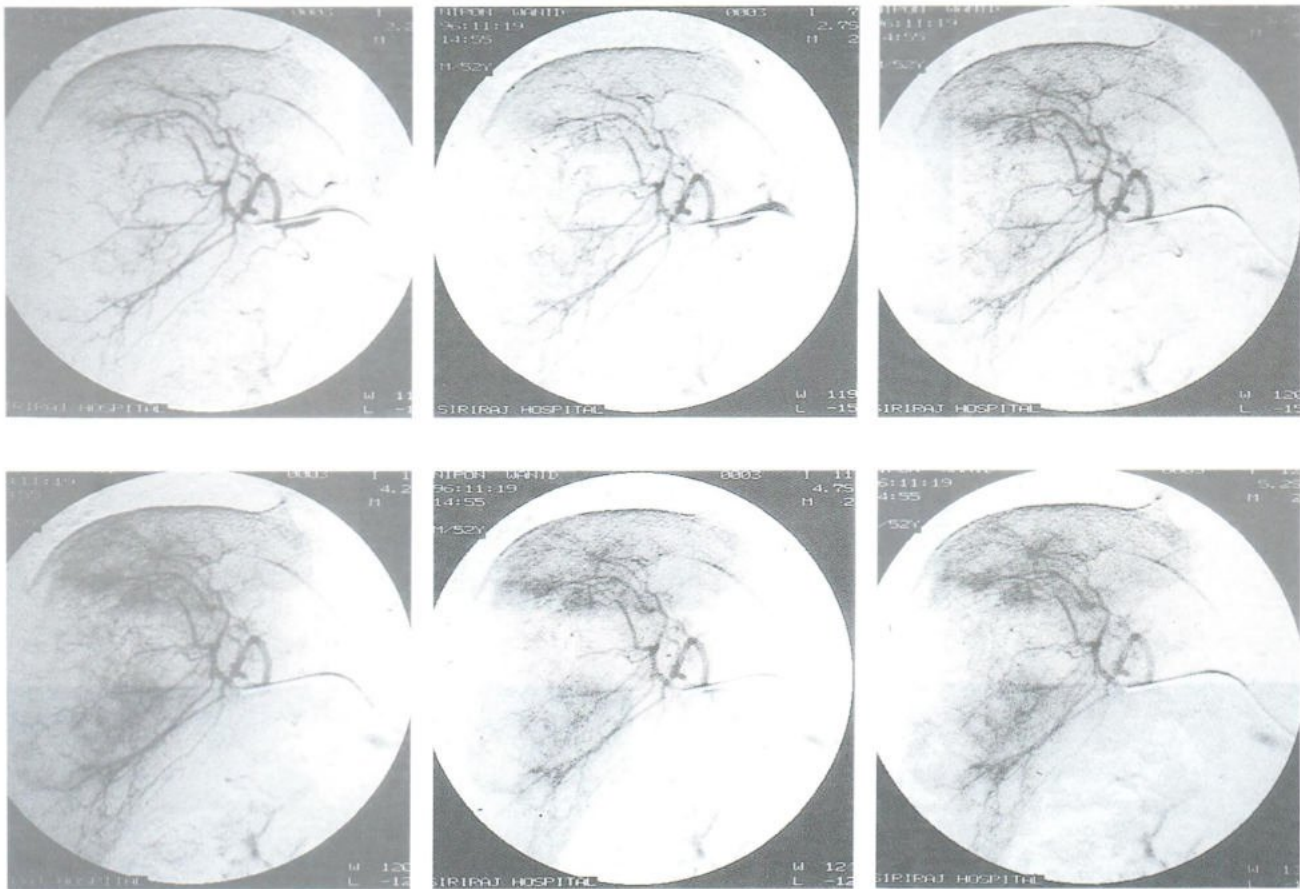




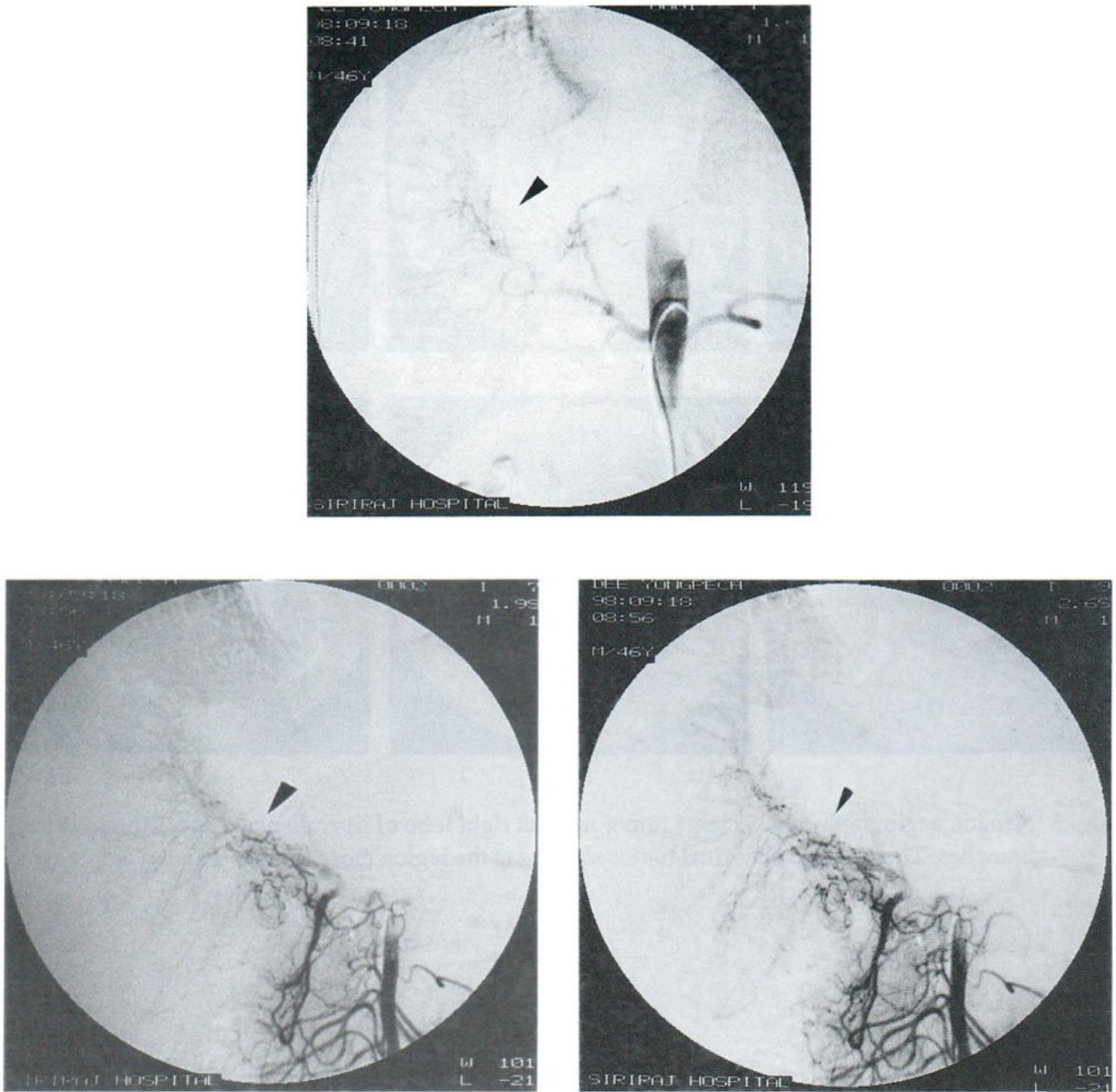
**Fig 3** Celiac angiography shows multiple areas of abnormal vascular staining in right lobe of liver. There is also demonstrable of hepatic artery branches encircle the right lobe tumor mass.



**Fig 4** Hepatic angiography shows straightening of hepatic artery branches because of tumor mass effect.



**Fig. 5** Hepatic angiography shows large tumor mass at right lobe of liver displace the hepatic artery branches. There is also abnormal tumor staining at the region close to right dome of diaphragm.



**Fig. 6,7** These figures show multiple liver vascular channels from hepatic and superior mesenteric arteries (arrow heads) coursing along portal venous radical suggesting portal venous involvement.

## DISCUSSION

Hepatocellular carcinoma, also known as hepatoma, is one of the most important neoplasm in the human population. Its true incidence is not known but the tumor is estimated to cause at least a quarter of a million death world wide in each year.<sup>5</sup> It is common in sub-saharan Africa and in much of the South East Asia (SEA), Far East, but relatively uncommon in North America. In Thailand, hepatocellular carcinoma is the most frequent cancer in males and the third in females.<sup>2</sup>

**Table 6** Geographic incidence of hepatocellular carcinoma<sup>6</sup>

| COUNTRY               | INCIDENCE (PER 100,000) |        |
|-----------------------|-------------------------|--------|
|                       | MALE                    | FEMALE |
| UK                    | 1.4                     | 0.4    |
| CANADA                | 1.3                     | 0.3    |
| USA                   |                         |        |
| WHITE                 | 2.4                     | 0.6    |
| BLACK                 | 8                       | 1.8    |
| JAPAN                 | 12                      | 2.9    |
| CHINA                 | 32                      | 9.1    |
| SOUTH AFRICA          |                         |        |
| BLACK                 | 28                      |        |
| WHITE                 | 1.4                     |        |
| TAIWAN <sup>9</sup>   | 1158                    |        |
| THAILAND <sup>7</sup> | 36                      | 14     |

In most of all population hepatocellular carcinoma is more common in the males than the females. Male to female ratio of 4:1 are common in Africa and Southeast Asia, whereas a ratio of 2.4 males to 1 females has been reported for United States. In our study, the result ratio of 2:1, is found.

Age incidences are slightly different in geographic location. In South Africa, common age range is between 30-50 years old. In North America and Asia common age range is between 60-80 and 40-60 years old respectively. In our

study, common age range is between 40-60 years old which correlating with other previous studies.<sup>5</sup>

**Table 7** Age incidence of hepatocellular carcinoma<sup>6</sup>

| COUNTRY       | COMMON AGE RANGE (year) |
|---------------|-------------------------|
| AFRICA        | 30 - 50                 |
| ASIA          | 40 - 60                 |
| NORTH AMERICA | 60 - 80                 |

There are many methods for evaluating hepatocellular carcinoma. Angiography is one of the most useful methods. It is mandatory in the staging of hepatocellular carcinoma despite its relative higher morbidity compare to the other technique. It allows detection of the vascular tumors as small as 0.5 cm and 2.0 cm if the tumor is hypovascular. The vast majority of hepatocellular carcinoma are hypervascular tumors, characterized by AV shunting and increased capillary blush in the hepatogram (late venous) phase. As with other imaging techniques, the main objective is to distinguish between unifocal and multifocal disease. Additionally, the presence of venous invasion, both into hepatic vein and segmental portal vein may be assessed.<sup>2</sup>

In our study, spectrum of angiographic finding in hepatoma range from avascular to hypervascular. The most angiographic finding is neovascularity 88% (112/126). Other findings include vascular distortion 83% (105/126), vascular pooling 66% (72/126), vascular encasement 27% (35/126), irregular margin 44% (56/126), AV shunt 33% (42/126), portal vein thrombosis 5% (7/126), avascularity 5% (7/126) no abnormal angiography detected 5% (7/126). These findings agree with typical angiographic picture of HCC.

Compared with previous study of Tonkin et al 1998, some angiographic findings are similar but some are different as described in table 8.

**Table 8** Comparison between study of Tonkin et al 1988 and Siriraj (18 cases with pathological diagnosis).

|                     | FINDINGS TONKIN et al<br>(n = 26) 1988 | SIRIRAJ<br>(n = 18) |
|---------------------|--|---------------------|
| neovascularity      | 26 (10%)                               | 16 (89%)            |
| vascular pooling    | 22 (85%)                               | 15 (83%)            |
| vascular distortion | 5 (19%)                                | 12 (67%)            |
| vascular encasement | 20 (77%)                               | 5 (28%)             |
| irregular margin    | 18 (69%)                               | 8 (44%)             |

Accuracy in the diagnosis of HCC by angiography remain in doubt. Lack of typical angiographic modification in small HCC suggests that the neovasculature has not yet developed fully or that vascular changes are already present but angiography is not sensitive enough to demonstrate them.<sup>4</sup> It is possible for the 5% of our cases, whose angiography show no abnormality, the HCC-tumor size is too small lesion to be demonstrated by hepatic angiography. And in our studies with color Doppler ultrasonography (Krisdee Prabhasavat 1997), we find that the small HCC is supplied by the portal circulation, so we cannot find any abnormality in the hepatic angiography study in the case of the small HCC ( size less than 1-2 cm).

We could correctly diagnosed HCC in 94% of case(17/18) but because of too small sample size we used and no non HCC group in this study, the value of angiography should be carefully interpreted. Most of our cases show no surgical or laparoscopic diagnosis. It is possible that the proved cases trend to have true hepatocellular carcinoma than non-proved case (not included in this study), so, there may be some populational bias for the diagnosis of HCC.

In summary, although in our study show correctly diagnosed of HCC in 94% of cases, more

strictly design of study is needed for interpretation with more confidence. However, other than diagnostic role of angiography, angiography play role in staging, identification of multiplicity and evaluation for further possible chemoembolization.

## REFERENCES

1. Rustgi. VK. Epidemiology of Hepatocellular Carcinoma. *Annals of Internal Medicine*. 1998;108:390-391.
2. J. Karani, R Williams. The Staging of Hepatocellular Carcinoma, *Clinical Radiology* 1993;47:297-301.
3. Alton. I. Sutnick, Kusuya, Nishioka. Hepatitis and Hepatocellular Carcinoma in Southeast Asia. *Cancer detection and Prevention*. 1988;11:337-351.
4. Mrio BZ, Carlo C, Plunio R. The Role of Angiography in Hepatocellular Carcinoma. *Journal of Surgical Oncology (Supplement)*. 1993;3:197-199.
5. Kew MC : Tumor of the liver, in Zakim D, Boyer TD. Eds : *Hepatology : a text book of liver diseased 2* Philadelphia, 1989, WB Saunders.
6. Beasley, RP, Hwang LY, CC, Chien CS : Hepatocellular carcinoma and hepatitis B virus : A prospective study of 22,707 men in taiwan. *Lancet* 2 :1129-1133,1981.
7. James C Harvey, MD Edward J Beatte MD, *Cancer Surgery*, Sander company ed1,1996.
8. Vatanasapt V , Martin N, Sriplung H, et al *Cancer in Thailand 1988-1991 IARC Technical Report No.16*.Lyon.1993.
9. Prabhasavat K.,et al : *Color Doppler Ultrasonography Findings in the Hepatocellular Carcinoma*, Siriraj Vol. 48, No 5; 1997.

## PERCUTANEOUS ABSCESS DRAINAGE OF INTRA-ABDOMINAL ABSCESSSES AND FLUID COLLECTION

Komgrit TANISARO

**PURPOSE :** To assess the safety and efficacy of Percutaneous Abscess Drainage (PAD) of intra-abdominal abscesses or fluid collections with small-bore catheter in patients who were followed up for 2 years.

**MATERIALS AND METHODS :** Retrospective analysis was performed in 55 consecutive PAD patients who were treated from July 1993- May 1996 in whom 2-years follow up data were available. Results of PAD were defined as cure, palliation/temporization and failure.

**RESULTS :** 55 abscesses and fluid collections were drained in 52 patients. Cure rate, palliation/temporization rate and failure rate were 68, 17 and 15 percent respectively. Catheter complication was 19 percent. Minor complication was 10 percent. One patient died due to intraperitoneal bleeding. Recurrent rate was 2.4 percent. Most of PAD were performed by small-bore catheter.

**CONCLUSION :** Our 85 percent success rate of PAD with small-bore catheter and acceptable minor complication rate indicate efficacy and safety of this technique in treating intra-abdominal abscesses and fluid collections.

**Index term :** Abdomen, abscess  
Abscess, percutaneous drainage  
Interventional procedures

**Abbreviation :** PAD = Percutaneous Abscess Drainage  
US = Ultrasonography  
CT = Computed Tomography

Percutaneous drainage has quickly become the preferred treatment for various type of abscesses and fluid collections. It is also the treatment of choice for the majority of intra-abdominal abscesses and fluid collections, regardless of etiology.<sup>1</sup> The safety, efficacy, and ease of the procedure have revolutionized the treatment of abscess. Few radiological procedures has been accepted so uniformly by nonradiologists as has percutaneous abscess drainage.<sup>2</sup> Imaging technique such as US and CT have greatly enhanced

an ability to properly locate abscesses and identify daughter abscesses, extensions, and area of loculation or subseptation.<sup>3</sup> Percutaneous drainage has several advantages over and at least as efficacious as operative drainage.<sup>4</sup>

Most published studies did not show any long-term clinical follow-up. Thus, recurrence rates of abscesses are difficult to determine. A consecutive series of 44 percutaneous drainage of intra-abdominal abscess and fluid collection in 41

Department of Radiology Hospital of Prince of Songkla University Hatyai, 90110, Thailand

Correspondence to: Komgrit Tanisaro, MD telefax: 074-212900 telephone: 074-212070 e-mail: tkomgrit@ratree.psu.ac.th

patients with at least 2 years clinical follow-up was carried out.

## MATERIALS AND METHODS

Retrospective analysis was performed in 52 patients who underwent PAD of intra-abdominal abscess or fluid collection between July 1993 to May 1996 in whom at least 2 years follow-up information were available. Selective criteria included 1) a well-established, unilocular fluid collection having variable ultrasonography or CT scan signs of abscess, 2) patients in whom percutaneous technique was thought to be preferential to operative technique (i.e., poor anesthetic risk, a recent cerebrovascular accident), or 3) patient or physician preferences.

All data were reviewed from the radiology information sheet which was filled by interventional radiologist performing the PAD and from the medical record of the hospital. The collected data were 1) patient profiles. 2) past medical and surgical history. 3) suspected cause(s) of abscess or fluid collection. 4) underlying disease(s). 5) antibiotic uses. 6) septic and coagulopathic laboratory results. 7) imaging modalities used in diagnosis and intervention. 8) method of drainage. 9) equipment and catheter used in PAD. 10) postprocedural care and complication(s). 11) duration of catheter placement. and 12) duration of hospital stay.

Percutaneous management was defined as "cure" if complete resolution of clinical signs and symptoms occurred in long-term clinical follow up (at least 2 years) and diagnostic imaging showed complete resolution of the abscess cavity. It was defined as "palliation/temporization" if resolution of the abscess improved the patient condition prior to adjunctive surgery to remove the underlying cause or an improvement in signs and symptoms with the patient clinically stable but not cured. Finally, it was defined as "failure"

if patient failed to meet the criteria for cure and palliation/temporization.

All PAD were performed by one interventional radiologist (K.T). All data from the radiology information sheet were entered onto computer software (Microsoft-excel, version 6.0)

## RESULTS

Fifty-five abscesses or fluid collection were drained in 52 patients. 2 years follow-up could be performed in 41 patients who regularly visited or admitted by problem not related to abscess or fluid collection. The patients ranged in age from 2 months to 81 years (mean, 42 years). There were 24 males and 17 females. There were 20 patients (48%) with postoperative abscess or fluid collection: 4 occurred after operation due to severe blunt abdominal injury, 4 after Whipple's operation, 4 after gastric surgery, 3 after common bile duct surgery or stenting and 2 after splenectomy. Three postoperative patients had 2 sites of collection. Locations of postoperative abscess or collection were left subphrenic space in 7, right subphrenic space in 6, interloop region in 6, perihepatic region in 5, and paracolic space in 3. 8 patients (19.5 percent) had liver abscesses. Three of them were ruptured status.

The imaging guidance were ultrasonography with fluoroscopy in 33 patients, ultrasonography alone in 5 patients, CT scan alone in 2 patients and fluoroscopy alone in 1 patient. Route of access were anterior abdominal wall in 17 patients, lateral abdominal wall in 7 patients, right intercostal space in 9 patients, left intercostal space in 6 patients, transincision in 1 patient and transrectal in 1 patient.

Catheter french size included 8.5-F in 20 patients, 8-F in 5 patients, 10-F in 3 patients and 12-F in 2 patients. Angiocatheter technique (Modification of the Seldinger techniques used in



angiography) was used in nearly all patients except one whom trocar catheter technique was used. Type of drainage catheter were Cope-loop nephrostomy catheter (COOK®, Bloomington, IN, USA) in 32 patients and Hydrophillic pigtail drainage catheter (Meditech®, Watertown, MA, USA) in 3 patients. The rest were locally hand-made 8-F self-retaining loop catheter. Drainage catheter remained in position 5-24 days (mean, 13 days). To evaluating size of abscess or fluid collection, ultrasound alone, fistulography alone and combination were performed in 30, 5 and 5 patients respectively.

Patients were febrile (body temperature above 37.5 Celsius) in 35 cases. Thirty-one patients (75%) were defevered and 4 patients were sustained. In all patients, the cure rate was 68.5 percent (28/41), palliation/temporization rate was 17 percent (7/41) and failure rate was 12 percent (5/41). Cure and palliation/temporization rate were 95 percent (19/20) in the postoperative group compared to 76 percent (16/21) in the non-postoperative group. Non-ruptured liver abscesses had a cure rate of 80 percent (4/5). Percutaneous biliary drainage was also performed in one case successfully. One of them were recurrent after 2 months.

Catheter complications were found in 8 patients (19%): displacement, occlusion and dislodgment in 3, 3 and 2 patients respectively. Three of these complicated patients were treated by repositioning the drainage catheter and 1 by single additive percutaneous aspiration. Other minor complication such as minor bleeding, inflammation at punctured site, pericatheter leakage were found in 4 patients. One patient who had peripancreatic collection with acute hemorrhagic pancreatitis died 6 hours after PAD. Postmortem abdominal tapping revealed a large amount of intraperitoneal hematoma. Three patients died from causes not related to the procedure (1 from lung metastasis, 1 from complication of a later operation and 1 from uncontrollable pneumonia)

## DISCUSSION

Percutaneous Abscess Drainage (PAD) has now become a standard technique for dealing with intra-abdominal abscesses and fluid collections in 50-90 percent of cases. Controversy has sometimes been seen as a territorial battle between surgeons and radiologists and most cases are clearly the prerogative of one discipline or the other, but many are in a gray zone in which clearly defined indications are not readily available.<sup>5</sup> PAD has several advantages over surgical drainage including 1) external drainage without risk of contamination or spillage intra-abdominally or into the operative wound, 2) avoidance of surgery, general anesthesia, and related postoperative complications, 3) reduced duration of drainage, 4) probable saving of time and expense, 5) better patient acceptance, 6) easier nursing care, 7) earlier diagnosis and treatment, which may account for decreased mortality and morbidity rates, and 8) a lower incidence of inadequate drainage.<sup>4</sup>

Our study has a very favorable success rate of 85 percent. Its is quite similar to those reported in literature.<sup>6-8</sup> Most complications in this series were minor (29%), mainly related to catheter problems. This rate is acceptable as compared to 0-31 percent in previously reviewed studies.<sup>6</sup> Many reports about PAD did not give consistent clinical follow-up and some did not calculate the recurrent rate. We did follow all 41 patients for at least 2 years and found only 1 recurrence (2.4%) in patient with amoebic liver abscess. Lambiase et al.,<sup>9</sup> reported a 1-year follow up series with 2.1% recurrence 335 abscesses and believed that most recurrences would be evident within 2-3 months of the initial abscess drainage and most would be due to an incompletely treated abscess or to unrecognized communications rather than failure to obliterate completely an anatomic nidus.

Most of causes of death in this series were

not related to PAD except one who had intraperitoneal bleeding after drainage a pancreatic abscess. Mortality rate of surgery in pancreatic abscesses ranged from 22-43%.<sup>10-11</sup> Success rate was not acceptable when comparing to non-pancreatic abscesses<sup>9,12-14</sup> Some authors<sup>15</sup> recommended that pancreatic abscesses should be generally treated by surgical debridement, and usually accompanied by repeated explorations.

Result in postoperative abscesses or fluid collections were more favorable than non-operative group significantly in our series (95% VS 76%). Mclean et al.,<sup>16</sup> concluded from their data that PAD is of value only in selected cases. If an anastomotic dehiscence is a possibility the patient should be managed operatively.

The duration of catheter placement in our series was 13 days in average which is longer than most reports<sup>17-19</sup> An explanation is our use of a small-bore catheter. More than 60% of small-bore drainage catheter (less than 10-F) was used in our series. A large-bore catheter (more than 10-F) was used in a limited number of patients. Other possible causes of greater duration of drainage are lack of routine irrigation program and routine suction connecting to the drainage catheter.

In conclusion, successful drainage is achieved in 85% of cases with an acceptable rate of complication and recurrence in long-term follow-up. PAD has now become a standard technique for dealing with nearly all kinds of intra-abdominal abscesses and fluid collections.

## REFERENCES

1. Van Gansbeke D, Matos C, Gelin M, Muller P, Zalcman M, Deviere J et al., Percutaneous drainage of subphrenic abscesses. *British J Rad* 1989;62:127-133
2. Van Sonnenberg E, D'Agostino H, Casola G, Halasz N, Sanchez R, Goodacare B. Percutaneous Abscess Drainage: Current concepts. *Radiology* 1991;181:617-626
3. Lang EK. Renal, Perirenal, and Pararenal Abscesses: Percutaneous Drainage. *Rdiology* 1990;174:109-113
4. Johnson WC, Gerzof SG, Robbins AH, Nabseth DC. Treatment of Abdominal Abscesses. *Ann Surg* 1981;194:510-519
5. Bartlett JG. Intra-abdominal sepsis. *Med Clin North Am* 1995;79:599-617
6. Haaga JR. Imaging intraabdominal abscesses and nonoperative drainage procedures. *World J Surg* 1990;14:204-209
7. Van Sonnenberg E. Percutaneous drainage of abscesses and fluid collections: Technique, results and applications. *Radio-logy* 1982;142:1-10
8. Martin EC. Percutaneous drainage of postoperative intraabdominal abscesses. *Am J Roentgenol* 1982;138:13-15
9. Lambiase RE, Deyoe L, Cronan J, Dorfman GS. Percutaneous drainage of 335 consecutive abscesses: results of primary drainage with 1-year follow-up. *Radiology* 1992;184:167-179
10. Altemeier WA, Alexander JW. Pancreatic abscess: a study of 32 cases. *Arch Surg* 1963;87:80-89 (abstract)
11. Bittner R, Block S, Buchler M, Beger HG. Pancreatic abscess and infected pancreatic necrosis: difficult local septic complications in acute pancreatitis. *Dig Dis Sci* 1987;32:1082-1087 (abstract)
12. Steiner E, Mueller PR, Hahn PF, Saini S, Simoone JF, Wittenberg J et al., Complicated pancreatic abscesses: problems in interventional management. *Radiology* 1988;167:443-446

13. Van Sonnenberg E, Wittich GR, Casola G, Stauffer A, Polansky AD, Coons H et al., Complicated pancreatic inflammatory disease: Diagnosis and Therapeutic role of Interventional Radiology. *Radiology* 1985; 155:335-340
14. Freeny PC, Lewis GW, Traverso W, Ryan J. Infected pancreatic fluid collections: Percutaneous catheter drainage. *Radiology* 1988;167:435-441
15. Levinson MA. Percutaneous versus open operative drainage of intra-abdominal abscesses. *Infect Dis Clin North Am* 1992; 6:525-544
16. Mclean TR, Simmons K, Svenson LG. Management of postoperative intra-abdominal abscesses by routine percutaneous drainage. *Surg Gynecol Obstet* 1993; 176:167-171
17. Gerzof SG, Robbins AH, Johnson WC, Birkitt DH, Nabseth HD. Percutaneous catheter drainage of abdominal abscesses. *N Engl J Med* 1981;305:653-657
18. Van Sonnenberg E, Ferrucci JT Jr, Mueeler PR, Wittenberg J, Simeone JF. Percutaneous drainage of abscesses and fluid collections: technique, results and applications. *Radiology* 1982;142:1-10
19. Van Sonnenberg E, Mueeler PR, Ferrucci FT Jr. Percutaneous drainage of 250 abdominal abscesses and fluid collections. Part I. Results, failures and complications. *Radiology* 1984;151:337-341



Tomoscan M

FOR MORE INFORMATION PLEASE CONTACT  
**PHILIPS MEDICAL SYSTEMS**

- TEL. 745-4090 Ext. 3332
- FAX. 398-0792

**Philips Electronics (Thailand) Ltd.**  
209/2 Sanpavuth Road, Prakanong, Bangkok 10260



**PHILIPS**

*Let's make things better.*

## GLUE EMBOLIZATION IN RENAL TRAUMA WITH MASSIVE HEMATURIA

Kanjana DANPUKDEE, MD., Anchalee CHUROJANA, MD.,  
Suthisak SUTHIPONGCHAI, MD.

### ABSTRACT

Two cases of renal trauma presented with massive hematuria. In the first case, renal angiography revealed traumatic AVF confined to the upper pole of left kidney. The renal angiography in the second case revealed two false aneurysms at the lower pole of right kidney. The super-selective angiography of the feeding arteries was done and glue embolization was performed. Post-embolized angiogram showed complete occlusion of the AVF and aneurysms. No further hematuria is observed.

AVF = Arterio - Venous Fistula.

### INTRODUCTION

Approximately 80% of renal trauma are minor injury which surgery is not necessary.<sup>5</sup> However persistent hematuria usually needed surgery. Surgical intervention often results in nephrectomy. Selective renal embolization is alternative treatment in order to preserve viable renal parenchyma. Gelfoam and coil have been used as embolic material for long time. Gelfoam is contraindicated in arteriovenous fistula. Coil needs available proper size. Glue can be used in arteriovenous fistula and always available. We report the successful glue embolization in arteriovenous fistula and false aneurysm. We propose glue as alternative embolic material in traumatic kidney.

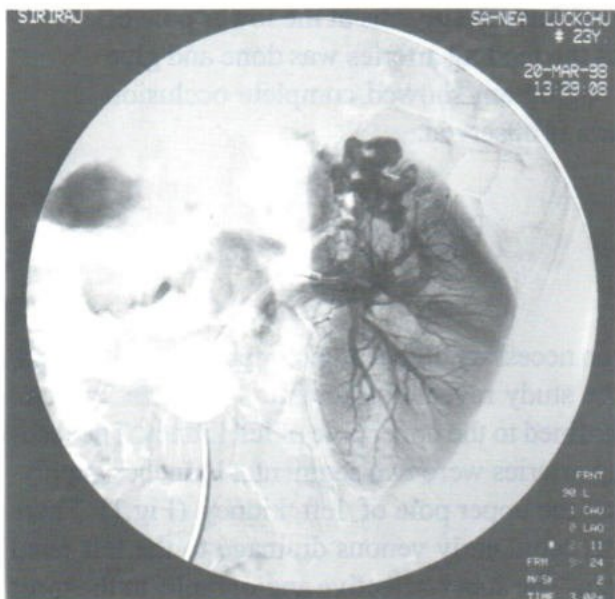
### CASE REPORT

#### CASE 1

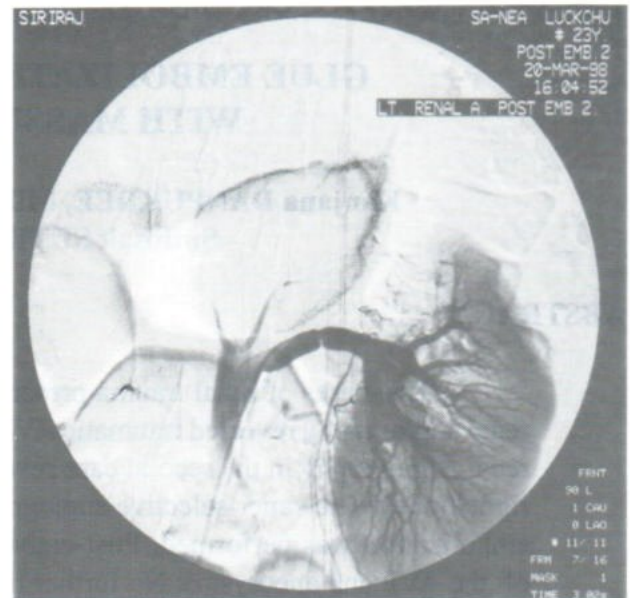A 23-year-old man was admitted after motorcycle accident. He developed massive hematuria and left flank pain. Upon the admission he was pale and hypotensive making blood transfu-

sion necessary. Renal angiography was performed. The study revealed traumatic AVF size 3x4 cm. confined to the upper pole of left kidney. The feeding arteries were two segmental branches supplying the upper pole of left kidney. (Fig.1). There was rapid early venous drainage to the left renal vein. The super-selective angiography to the most cranial branch was done with No.6 Fr. catheter. The pre-embolization angiogram revealed AVF with the rapid draining vein. A No.3 Fr. co-axial catheter was super-selectively applied deep into the feeding artery. Then, 0.8 cc of glue-lipiodol mixture was infused. Post-embolization angiogram revealed complete occlusion of the artery. Then super-selective angiography into another feeding artery was done and infusion of approximately 0.7cc glue-lipiodol mixture was performed. Post-embolization study revealed the complete occlusion of the artery and the complete disappearance of AVF (Fig.2). There is focal narrowing at the proximal renal artery which was suspected to be spasm. The patient tolerated the procedure well with no complication. No further he-

maturia was observed. The stable hemodynamic was achieved. Three-day follow-up color Doppler ultrasound revealed swelling at the upper pole of left kidney without the flow suggesting infarction. No evidence of AVF was seen. Follow-up renal angiogram at one-month later revealed infarction at the upper pole of left kidney. The preservation of the normal renal parenchyma was achieved. Focal narrowing of the main renal artery was disappeared. No evidence of hematuria is noted.



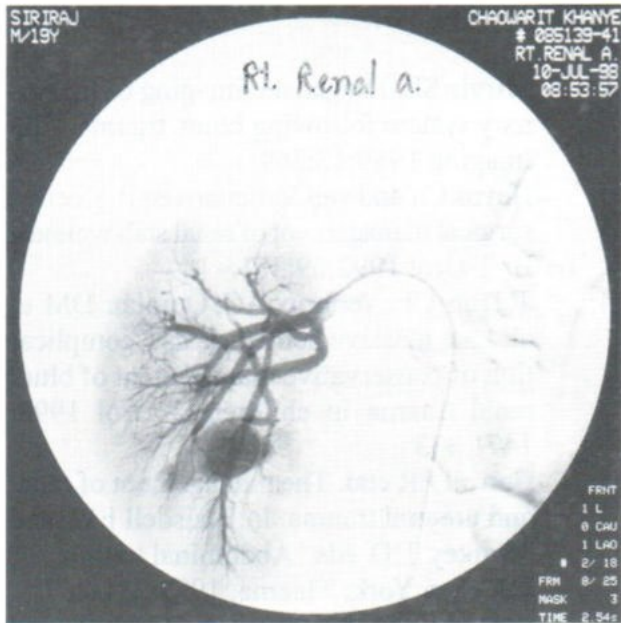
**Fig.1** Left renal angiogram showing traumatic AVF size 3x4 cm. confined to the upper pole of left kidney. The feeding arteries were two segmental branches. There was rapid early venous drainage to the left renal vein.



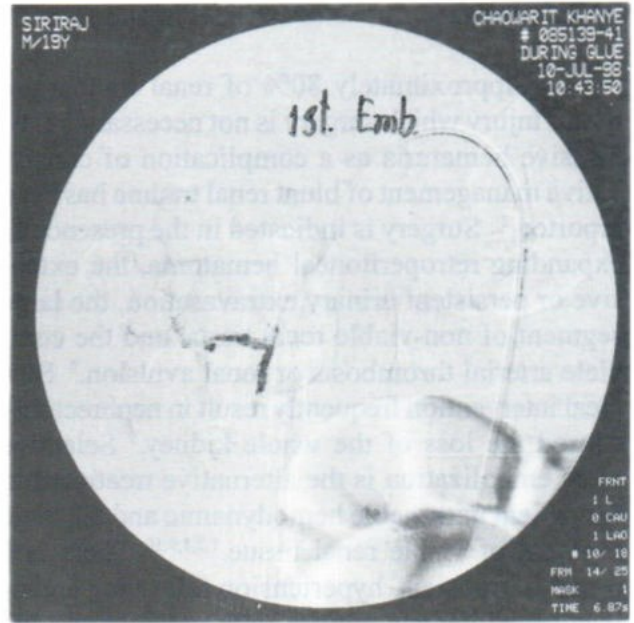
**Fig.2** Post-embolization study revealed the complete occlusion of the artery and the complete disappearance of AVF. Spasm of left renal artery is noted.

## CASE2

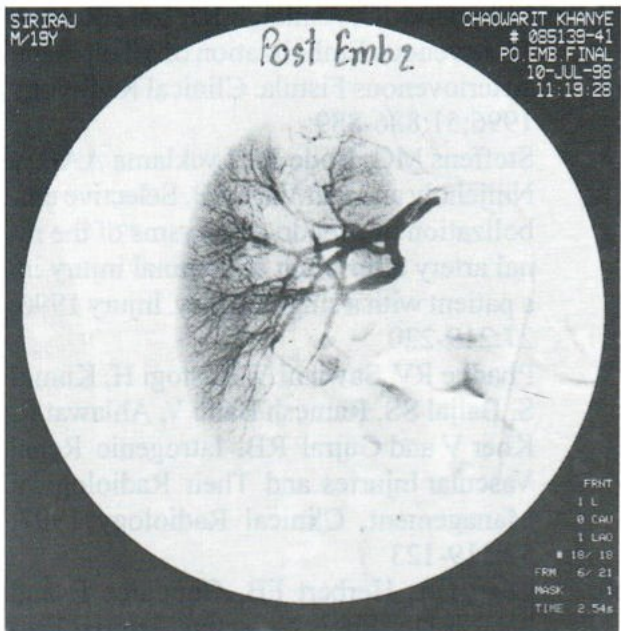
A 19-year-old man was admitted after stab wounded at right flank. The wound was explored and cortical renal laceration was observed. The patient underwent renal repair. He was discharged without any complication. Three weeks later, he was admitted again with massive hematuria. He was pale and hypotensive needed blood transfusion. The renal angiography revealed false aneurysm size 1.5 cm. at the lower pole of right kidney supplied from two segmental branches. (Fig.3). The super-selective angiography was done into each branch using No. 3Fr.catheter co-axial system. Then infusion of 0.8 cc. glue-lipiodol mixture into each branch was performed (Fig.4). Post-embolization study revealed complete occlusion of the arteries and disappearance of the aneurysm (Fig.5). The recovery was uneventful without complication. The follow-up color Doppler ultrasonography of the traumatized kidney revealed thrombosed aneurysm with infarction at the lower pole of the kidney (Fig.6).



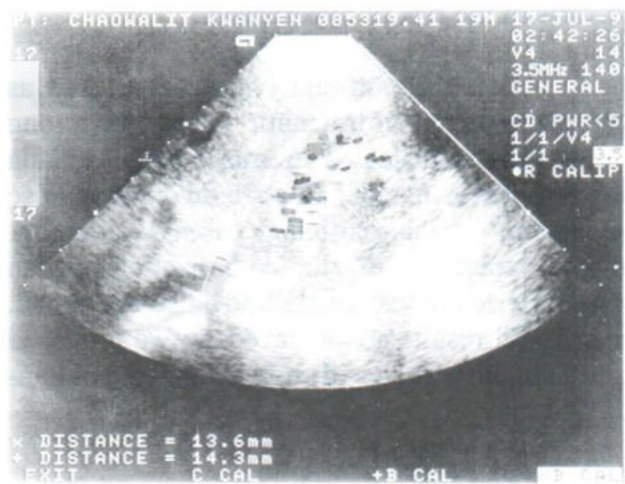
**Fig. 3** Right renal angiogram showing false aneurysm size 1.5cm. at the lower pole of right kidney supplied from two segmental branches.



**Fig. 4** Superselective into feeding arteries and infusion of 0.8 cc. glue-lipiodol mixture into each branch was performed



**Fig. 5** Post-embolization study revealed complete occlusion of the arteries and disappearance of the aneurysm



**Fig. 6** Follow-up color Doppler ultrasonography of the traumatized kidney revealed thrombosed aneurysm size 1.36x1.43cm. with infarction at the lower pole of the kidney

## DISCUSSION

Approximately 80% of renal trauma are minor injury which surgery is not necessary.<sup>5</sup> Late massive hematuria as a complication of conservative management of blunt renal trauma has been reported.<sup>4</sup> Surgery is indicated in the presence of expanding retroperitoneal hematoma, the extensive or persistent urinary extravasation, the large segment of non-viable renal tissue and the complete arterial thrombosis or renal avulsion.<sup>3</sup> Surgical intervention frequently result in nephrectomy caused the loss of the whole kidney.<sup>5</sup> Selective renal embolization is the alternative treatment in the patient with stable hemodynamic and the large segment of viable renal tissue.<sup>1,2,5,9,10</sup> There is a report of transient hypertension following embolization which can control with medication.<sup>6</sup> No other complication was noted making the procedure safe for the patient.

Traumatic arteriovenous fistula (AVF) has been reported successfully treated by embolization.<sup>6,7,8</sup> The embolization is preferable to surgery and accepted as the treatment of choice of AVF. The preservation of functional renal parenchyma is also required. The close follow-up is necessary in view of the risk of hypertension

Coil, gelfoam and ivalon were used as embolic material in traumatic kidney for a long time.<sup>9</sup> Coil is indicated in arteriovenous fistula whereas gelfoam and ivalon are favoured in false aneurysm.<sup>9</sup> In this particular cases, we demonstrated experience of glue embolization in both renal arteriovenous fistula and false aneurysm. Successful results are achieved, so we proposed glue as another choice of embolic material in traumatic kidney.

## REFERENCES

1. Hall CL, Cumber P, Higgs CMB et al. Life threatening haemorrhage from a mycotic renal pseudo-aneurysm treated by segmental renal artery embolization. *Br Med J* 1987;294:1526
2. Mirvis SE. Diagnostic imaging of the urinary system following blunt trauma. *Clin Imaging* 1989;13:269
3. Heyns CF and van Vollenhoven P. Slective surgical management of renal stab wounds. *Br T Urol* 1992;69:351
4. Teigen CL, Venbrux AC, Quinlan DM et al. Late massive hematuria as a complication of conservative management of blunt renal trauma in children. *J Urol* 1992; 1471:333
5. Carroll PR etal. The management of renal and ureteral trauma. In:Blaisdell FW and Trunkey DD eds. *Abdominal trauma*, 2<sup>nd</sup> Ed. New York: Thieme, 1993;251-267
6. van der Zee JA, van den Hoek J, and Weerts JGE. Traumatic Renal Areriove-nous fistula in 3-year-old Girl, Successfully Trated by Percutaneous Transluminal Embolization. *J. Ped Sur* 1995;30:1513-1514
7. Litherland JC, Ashleigh RJ. Case Report: Transvenous Embolization of a Traumatic Arteriovenous Fistula. *Clinical Radiology* 1996;51:886-889
8. Steffens MG, Bode PJ, Lycklama AAB, a Nnijeholy and van Vugt AB. Selective embolization of pseudo-aneurysms of the renal artery after blunt abdominal injury in a patient with a single kidney. *Injury* 1996; 27:219-220
9. Phadke RV, Sawlani V, Rastogi H, Kumar S, Baijal SS, Ramesh Babu V, Ahlawat R, Kher V and Gujral RB. Iatrogenic Renal Vascular Injuries and Their Radiological Management. *Clinical Radiology* 1997; 52:119-123
10. Legg EA, Herbert FB, Goodarce B and Neal Jr DE. Super-Selective Arterial Embolization for Blunt Trauma in the Horse-shoe Kidney. *Urology* 1998;51(2):320-321



---

## EARLY DETECTION OF BREAST CANCER BY SCREENING MAMMOGRAPHY

Malai MUTTARAK<sup>1</sup> M.D., Ladda CHALOEYKITTI<sup>1</sup>BSc.,  
Hongsin TRAKULTIVAKORN<sup>2</sup>M.D., Chanane WANAPIRAK<sup>3</sup>M.D.,  
Benjaporn CHAIWUN<sup>4</sup>M.D., Samreung RANGDAENG<sup>4</sup>M.D.,

### ABSTRACT

Mammography is currently the best modality for breast cancer screening. We have been performing a mammography screening over the last 3½ years on 1000 women seen during this period. We detected 3 cancers, all of which were ductal carcinoma-in-situ with microinvasion and no axillary node involvement. The overall cancer detection rate was three per thousand. All of our cases were younger than 49 years of age. Our cancer detection rate and stage of detected cancer meet the standard suggested by international reports. Further study to increase our sample size is on-going.

### INTRODUCTION

Breast cancer is the third most common cancer of women in Thailand after cervix and liver.<sup>1</sup> The estimated national incidence rate is 13.5 cases per 100,000. This incidence appears to be low as compared to South East Asia (22.7), China (14.6) and Japan (23.5). The etiology of breast cancer is unknown but potential, risk factors have been observed. Changes in dietary patterns, breast-feeding patterns or life style may increase the incidence of breast cancer in Thailand as has been observed in similar circumstance in many developed Asian countries such as Singapore and Hong Kong.<sup>2-4</sup>

Most patients with breast cancer in Thailand were in stage II or greater when first diagnosed. Mammography has clearly been shown to be sensitive for early breast cancer detection. Results from several international studies have

shown a reduction in breast cancer mortality rate of approximately 30%-40% from mammographic screening programs. We undertook a mammography screening trial at our institution in the hoping that the outcome would be profitable and effective for Thai women.

### MATERIALS AND METHODS

Between June 1994 to December 1997, 1000 asymptomatic women, aged 40 years and older were offered entry into the screening mammography program. Physical examination was performed by the referring physician or the radiologist in case of self-referral.

Women were asked for general information, including marital status, education, menstruation and pregnancy history, breast feeding history,

---

<sup>1</sup> Department of Radiology,

<sup>2</sup> Department of Surgery,

<sup>3</sup> Department of Obstetric-Gynecology,

<sup>4</sup> Department of Pathology, Faculty of Medicine, Chiang Mai University Chiang Mai Thailand.

Supported by Faculty of Medicine Endowment Fund for Medical research, Chiang Mai University.

familial history of breast cancer, clinical breast symptoms, hormonal supplement, history of breast surgery and history of breast self examination.

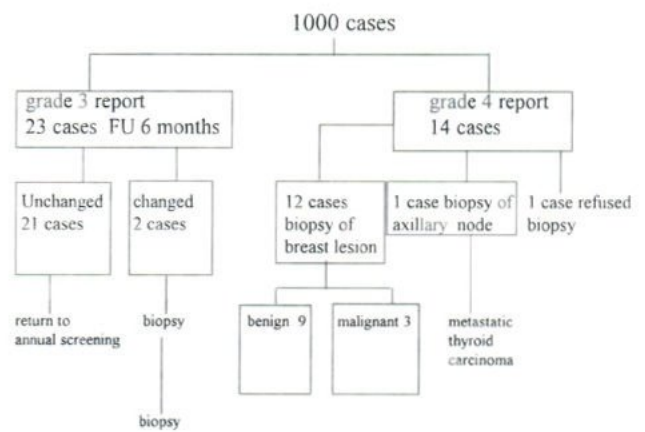
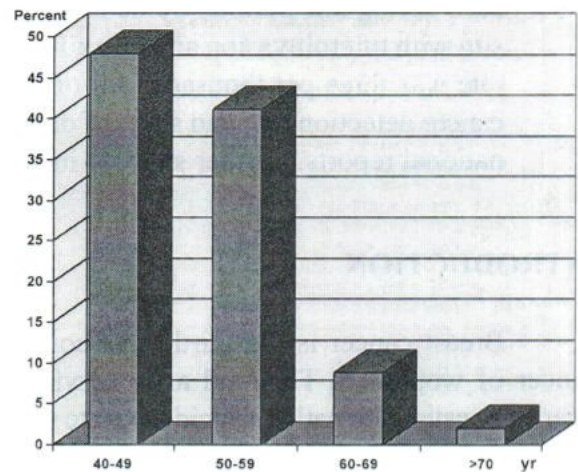
Two standard views were taken of each breast (one craniocaudal view and one mediolateral oblique view) by a dedicated mammography machine (Lorad MIII) and Kodak min-R screen-film combination. The films were reported by a qualified radiologist and graded into five categories according to the mammographic findings, 1.normal, 2.benign, 3.probably benign, 4.suspicious abnormality, 5. highly suggestive of malignancy. Additional view(s) or ultrasound of the breast may then be obtained accordingly in the same day. Women with grade 1 and 2 reports were discharged and return to annual screening. With grade 3 reports, they were asked to have a follow-up examination twice at 6 month intervals. With grade 4 and 5 reports, they were all referred to the surgeon.

**RESULTS**

All women had the first screening mammography. There were 479 cases (47.9%) in the age group of 40-49 years, 412 cases (41.2%) aged 50-59 years, 89 cases (8.9%) aged 60-69 years and 20 cases (2%) aged 70 years or older (Table 1). Twenty-three patients had grade 3 reports. Of these, 21 patients showed unchanges after 6 months and 1 year follow-up. Two were biopsied after 6 months follow up and showed benign results. Fourteen patients had grade 4 reports and were advised to have biopsy. Of these, 13 had abnormal lesions in the breasts and 1 had abnormal enlarged axillary node which was proved to be metastatic thyroid carcinoma. One patient refused to have biopsy. Biopsy of the 12 breast lesions revealed ductal carcinoma-in-situ (DCIS) with microinvasion in 3 and benign lesions in 9 cases (Fig.1). The tumor size was 1 cm. in 2 cases (Fig 2) and 2 cm.in one case.

Biopsy was performed by hook-wire localization in 9 cases, stereotactic-guided needle core biopsy in 1 case and direct biopsy in 4 cases. The overall benign-to-malignant biopsy ratio was 3.7:1. All 3 cases with cancer detected were aged 40, 42 and 43 years. The lesions were nonpalpable with negative axillary node.

**Table 1.** Age distribution of 1000 women participating in screening program

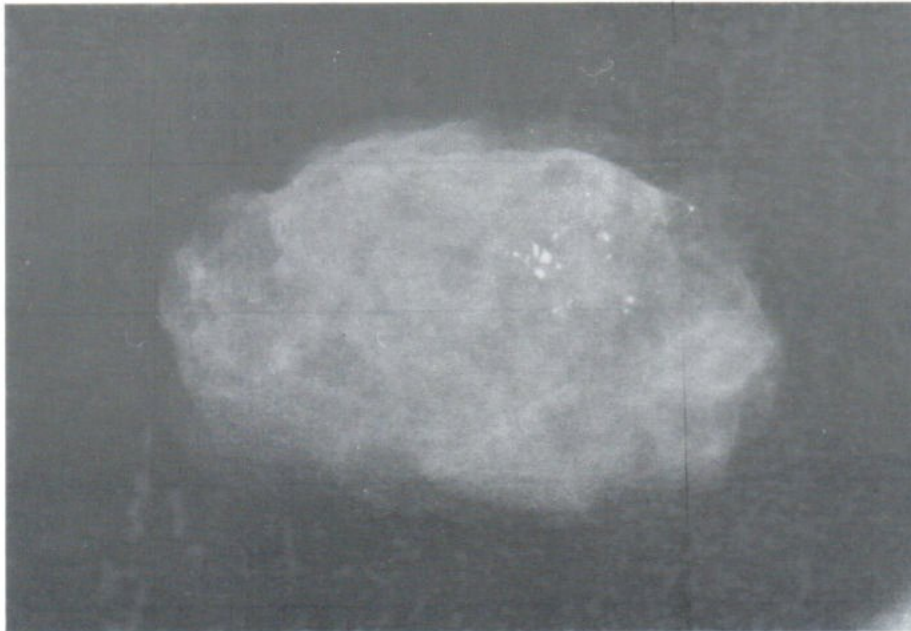


Benign : Malignant ratio = 3.7:1

**Fig 1.** Flow diagram of diagnostic pathways in 1000 screened women.



2A.



2B.

**Fig. 2A.** Magnification mammogram of a 40-year-old asymptomatic woman demonstrates a cluster of pleomorphic microcalcification (arrow). (B) Specimen radiograph confirms excision of the microcalcifications. Histology revealed ductal carcinoma-in-situ with microinvasion.

**Table 2.** Distribution of demographic characteristics in 786 women participating in screening program

| Characteristics                                      | No (%)     |
|--|------------|
| <b>Age (yr)</b>                                      |            |
| 40-49  | 377 (48)   |
| 50-59  | 323 (41.1) |
| 60-69  | 70 (8.9)   |
| >70  | 16 (2.0)   |
| <b>Marital status</b>                                |            |
| Single   | 89 (11.3)  |
| Married  | 604 (76.8) |
| Divorced   | 32 (4.1)   |
| Widowed  | 61 (1.8)   |
| <b>Parity</b>  |            |
| Nulliparous  | 153 (19.5) |
| Parous   | 633 (80.5) |
| <b>Education</b>                                     |            |
| below high school                                    | 205 (26.1) |
| high school graduate                                 | 180 (22.9) |
| university graduate or more                          | 401 (51)   |
| <b>Cumulative duration of breast feeding (month)</b> |            |
| Never  | 180 (22.9) |
| <3   | 234 (29.8) |
| 3-12   | 280 (35.6) |
| >12  | 92 (11.7)  |
| <b>Age at menarche (yr)</b>                          |            |
| 12 or less   | 109 (13.9) |
| 13-14  | 352 (44.8) |
| >15  | 325 (41.3) |
| <b>Age at menopause (yr)</b>                         |            |
| 45 or less   | 75 (9.5)   |
| 46-50  | 223 (28.4) |
| >50  | 158(20.1)  |
| premenopause and hysterectomy                        | 330 (42)   |
| <b>History of breast disease</b>                     |            |
| Yes  | 79 (10.1)  |
| No   | 707 (89.9) |
| <b>Familial history of breast carcinoma</b>          |            |
| Yes  | 86 (10.9)  |
| No   | 700 (89.1) |
| <b>Breast self examination</b>                       |            |
| Yes  | 581 (73.9) |
| No   | 205 (26.1) |

## DISCUSSION

Mammography was introduced in Thailand only recently. Currently, we have approximately 51 mammography machines in Thailand. The machines are mostly in the big cities especially in Bangkok, and most of the studies are for diagnosis of breast diseases. Several international studies have shown that mammography is sensitive in detecting early breast cancer.<sup>5-7</sup> Breast cancers tend to increase in Asian women and mammography screening in Asian women is of proven benefit.<sup>3-4</sup>

Recruitment of women for mammography screening at our institution is quite a problem and it took time to convince both the physicians and women to accept the procedure. The demographic characteristics in our screened women showed that young and educated women were more concerned about their health. Seventy four percent regularly practiced breast self-examination. Approximately 11% of screened women had a familial history of breast cancer but all of breast cancers were detected in women with a negative familial history.

The cancer detection rate in our study was 3 per thousand. All 3 positive cases had DCIS with microinvasion and occurred in young woman. This may be explained by the high proportion of young women in our study. The cancer detection rate from western countries is variable, ranging from 4 to 7 per thousand, and most of the patients are older than 50 years.<sup>5-10</sup> However, many studies have proven benefit from screening in women aged 40-49 years.<sup>11</sup> Only 2 large population trial mammography screening studies from Asia have been reported recently.<sup>3-4</sup> The overall cancer detection rate was 4.94 per thousand from Hong Kong and 4.8 per thousand from Singapore. In the study from Hong Kong, the cancer detection rate in women aged 40-49 years was 4.61 per thousand because of the high proportion of young women in the

screened population. A previous study suggested that Asian breasts are small and relatively dense, and may not be suitable for mammography because of low sensitivity in detecting the lesion.<sup>12</sup> The modern mammography machines are now much improved and all our detected cancer cases were in young women with dense breasts. Our benign-to-malignant surgical biopsy ratio of 3.7:1 was quite similar to the international studies which ranged from 10:1 to 2:1.<sup>13,14</sup>

Our data regarding the stage of detected cancer clearly meets standard suggested by international experts. For example, Tabar<sup>5</sup> et al suggested that at least half of the cancers detected at mammographic screening would be less than 15 mm. in diameter and that 70% have no nodal involvement. However, it is too early to draw any firm conclusions as our sample size is too small. We intend to continue our study, recruit more women, provide a good-quality service and compare our results to those of the major well-organized breast screening centers worldwide.

## REFERENCES

1. Vatanasapt V, Martin N, Sriplung H, et al. Cancer in Thailand 1988-1991. IARC Technical report No.16, Lyon: IARC 1993: 19-38.
2. Colemar. MP, Esteve J, Damiacki P, et al. Trends in cancer incidence and mortality. IARC Scientific Publication No.121, Lyon: IARC 1993:411-32.
3. Ng EH, Ng FC, Tan PH, et al. Results of intermediate measures from a population-based, randomized trial of mammographic screening prevalence and detection of breast carcinoma among Asian Women. The Singapore breast screening project. *Cancer* 1998;82:1521-8.

4. Chan LK, Lam HS, Chan EHS, et al. Mammogram screening of Chinese women in Kwong Wah hospital, Hong Kong. *Australasian Radiology* 1998;42:6-9.
5. Tabar L, Fagerberg CJG, Gad A, et al. Reduction in mortality from breast cancer after mass screening with mammography. *Lancet* 1985;37:829-32.
6. Andersson I, Aspegren K, Janzon L, et al. Mammographic screening and mortality from breast cancer: the Malmo mammographic screening trial. *BMJ* 1988;297:-943-8.
7. Shapiro S, Venet W, Strax P, et al. Ten-to fourteen-year effect of screening on breast cancer mortality. *JNCI* 1982;69:349-55.
8. Burhenne LJW, Hislop TG, Burhenne HJ. The British Columbia mammography screening program evaluation of the first 15 months. *AJR* 1992;158:45-9.
9. Bryant HE, Desautels JEL, Castor WR, et al. Quality assurance and cancer detection rates in a provincial screening mammography program. *Radiology* 1993;188:811-6.
10. Verbeek ALM, Hendriks JHCL, Holland R, et al. Reduction of breast cancer mortality through mass screening with modern mammography first results of the Nijmegen project, 1975-1981. *Lancet* 1984;1:1222-4.
11. Smart CR, Hendrick RE, Rutledge JH, et al. Benefit of mammography screening in women ages 40 to 49 years. *Cancer* 1995;75:1619-26
12. Alagaratnam TT, Wong J. Limitations of mammography in Chinese females. *Clin Radiol* 1985;36:175-7.
13. Rosenberg AL, Schwartz GF, Feig SA, et al. Clinically occult breast lesions: Localization and significance. *Radiology* 1987;162:167-70.
14. Meyer JE, Sonnenfeld MR, Greenes RA, et al. Preoperative localization of clinically occult breast lesions: Experience at a referral hospital. *Radiology* 1988;169:627-8.

---

## CT SCAN OF THE METASTATIC BRAIN TUMORS ; IS NON CONTRAST-ENHANCED CT SCAN NECESSARY ?

SORNSUPHA CHOKECHAIPAISAL,MD.  
ASSO PROF. PAITON CHONGCHITNANT,MD.  
KONGRIT THANISARO,MD. CHIRAWAT UTTAMAKUL,MD.

### ABSTRACT

Non contrast-enhanced CT scan (NCCT) with subsequent contrast-enhanced CT scan (CECT) are routinely practised in cases of brain tumors. For brain metastases, we observed that the lesions were better demonstrated on CECT and no useful information was obtained on NCCT. We reviewed 58 CT brain of 54 cancer patients who suspected to have brain metastases. We found that 24 cases (40%) had brain metastases. Of these, CECT demonstrated the lesions better than NCCT in 10 cases (42%), CECT and NCCT were equally good in demonstration of the lesions in 12 cases (50%). The remaining two cases were difficult to compare because of too numerous lesions. Two false negative results were also found on NCCT. These findings suggested that NCCT was unnecessary. Elimination of NCCT would be more cost-effective, reduce examination time and radiation exposure.

### INTRODUCTION

CT or MRI of the brain are widely used in determining the presence of brain metastases in cancer patients.<sup>1</sup> For CT, NCCT with subsequent CECT (combined CT) are routinely practised. In 1990, McGann GM et al<sup>2</sup> studied CT of cranial metastatic melanoma. They suggested using CECT-only for detection of melanoma metastases. We observed that not only melanoma but other brain metastases as well, CECT-only was sufficient for detection of the lesion. Elimination of NCCT would be more cost effective, reduce examination time and radiation exposure. The objective of this study were to compare each type of CT scan with combined CT and compare NCCT with CECT.

### SUBJECTS AND METHODS

We retrospectively reviewed 58 CT brain of 54 cancer patients who suspected to have brain metastases. The origins of the primary tumors were listed in (table 1). CT scans were routinely performed at 10 mm. interval. All examinations were performed before and after administration of standard dose of the contrast medium. The NCCT and CECT were initially reviewed independently by two radiologists. Examinations were assessed for the presence of the parenchymal or subarachnoid nodules and their conspicuousness. Comparison of each scan with combined CT and between each scan were evaluated. If the results were disagreed, opinion from the third radiologist was taken for consideration and final decision made.

**Table 1.**

| Type                   | No. of patient |
|------------------------|----------------|
| Lung                   | 22             |
| Hematologic malignancy | 9              |
| Reproductive organs    | 7              |
| Head and neck          | 5              |
| GI tract               | 4              |
| Breast                 | 3              |
| Adrenal gland          | 1              |
| Larynx + scrotum       | 1              |
| Melanoma               | 1              |
| Total                  | 54             |

**Table 2** Results.

|             | Negative | Positive | Total |
|-------------|----------|----------|-------|
| NCCT        | 36       | 22       | 58    |
| CECT        | 33       | 25       | 58    |
| Combined CT | 34       | 24       | 58    |

## RESULTS

Twenty-four (41%) of the 58 cases examined by combined CT had brain metastases. The metastatic lesions were found in 22 cases on NCCT and 25 cases on CECT (table 2). Two false negative on NCCT were 1.2 cm. isodense lesion at the suprasellar cistern and 1.4 cm. isodense lesion at the pineal region. One false positive on CECT had hematoma at the right occipital lobe and in the fourth ventricle. Single lesions were found in 11 cases (40%).

To assess the sensitivity of NCCT and CECT in evaluation of suspected brain metastases, the findings on NCCT were equivalent to those on CECT in 12 of 24 cases (50%). CECT were better than NCCT in 10 cases (42%). CECT showed more lesions in 7 cases, exact localization of the nodule in 1 case and better definition of the lesion in 2 cases. The remaining two cases had numerous lesions and difficult to compare on both types of scan.

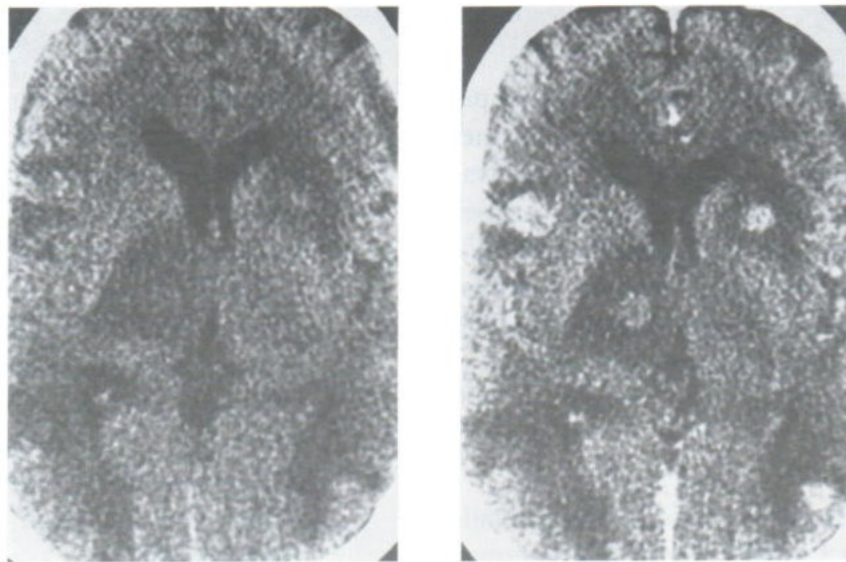
## DISCUSSION

Routine technique of CT scan in evaluation

of brain tumor is combined CT. Both types of scans have their own characters which may help in distinguishing various types of tumors. For cancer patients who were suspected to have brain metastases, demonstration of the presence or absence of brain tumors is necessary while the CT appearance is not important. Our study showed that CECT were better than NCCT. CECT delineated the lesions from surrounding edema better (Fig. 1) and detected the lesions that were inapparent on NCCT.<sup>1</sup> Therefore CECT-only is sufficient for diagnosis. This was also shown by McGann GM et al.<sup>2</sup> However there was one case of hematoma (Fig. 2) which was assumed as false positive on CECT because there was no histologically prove. This case might be bleeding from metastatic brain tumor as well. It is well known that brain tumors can cause intracerebral hemorrhage especially metastases. The incidence of hemorrhage in brain metastases is upto 15%.<sup>3</sup> Although CECT in this case did not show enhancement which might help in distinguishing bleeding metastases from hematoma as shown by Weisberg CA.<sup>4</sup> Niizuma H et al<sup>5</sup> also found 3 cases of bleeding metastases which CECT could not demonstrate any finding other than those indicating hematoma. The finding that may suggest bleeding metastasis in this case was unusual location of the hematoma.<sup>1</sup> However when NCCT is needed, it can be carried out subsequently.

Frequency of single metastases in our series was 46% which is almost the same as other series.<sup>4,5,6,7</sup> Todd N.V. et al<sup>8</sup> found that 4 of 8 cases diagnosed as metastases were incorrect. However these cases were unknown of primary malignancy which is a major factor in diagnosis of metastasis. Because the design of our study, it was not possible to determine the true sensitivity of each test. We used combined CT as our standard for detection of brain metastasis. Heimans J.J et al<sup>9</sup> reported accuracy of CT diagnosis in 64 patients with solitary brain tumor by comparison with histology. They found that predicted diagnoses agreed with histological diagnoses in only 57% and metastasis was one of the main causes of misdiagnoses. However CT is the only available diagnosis imaging method in most hospital in Thailand.

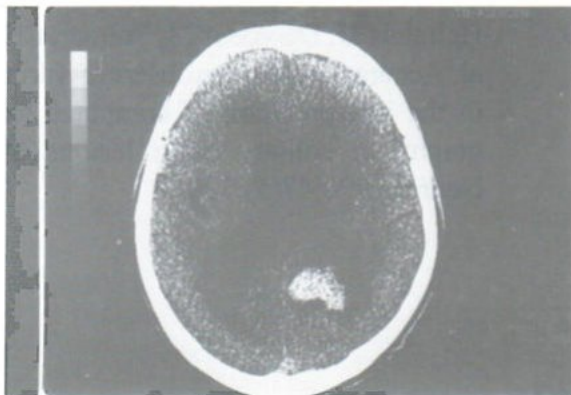




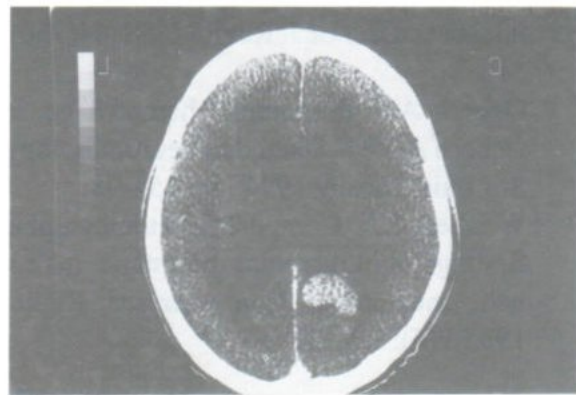
1A

1B

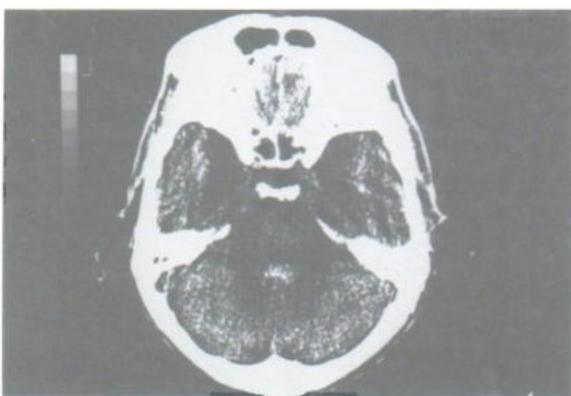
**Fig.1** NCCT showed multiple areas of abnormal hypodensities. CECT showed nodular enhancement of the metastatic tumors which are better delineated from surrounding edema.



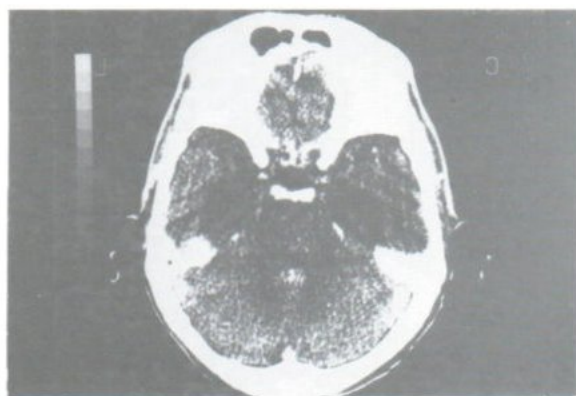2A



2B



2C



2D

**Fig.2** A case of hematoma at the right occipital lobe and in the fourth ventricle. NCCT showed area of hyperdensities which represent hematoma. CECT showed no enhancement.

## CONCLUSION

We studied 58 CT brain of 54 cancer patients who were suspected to have brain metastases. The study showed that CECT alone was sufficient in the demonstration of brain metastases and NCCT was unnecessary. Elimination of NCCT is more cost-effective and can reduce examination time resulting in increased patient throughput and reduction of the radiation exposure.

## REFERENCES

1. Johnson CE, Sze G. Intracranial meta static disease, in Lee SH, Rao K, Zimmerman RA eds. Cranial MRI and CT (3rd ed). Newyork, McGraw-Hill 1992 , pp 417-39
2. McGann GM , Platts A. Computed tomography of cranial metastatic malignant melanoma : features, early detection and unusual cases. Br J. Radiol 1991;64(760): 310-3
3. Osborn AG. Intracranial hemorrhage, in Osborn AG ed. Diagnosis neuroradiology, St.Louis, Mosby 1994 , pp 154-98.
4. Weisberg RA. Computerized tomographic findings in intracranial metastatic malignant melanoma. Computerized Radiol 1985;9(6):365-72.
5. Niizuma H., Nakasato N., Yonemitsu T, et al. Intracerebral hemorrhage from a metastatic brain tumor : importance of differential diagnosis proceeding stereotaxic hematoma aspiration. Surg Neurol 1988; 29(3):323-6
6. Delattre JY, Krol G, Thaler HT, et al. Distribution of brain metastases. Arch neurol 1988;45(7):741-4
7. Patchell RA, Cirrineione C, Thaler HT, et al. Single brain metastases : surgery plus radiation or radiation alone. Neurology 1986;36:447-53
8. Todd NV , McDonagh T , Miller JD. What follows diagnosis by computed tomography of solitary brain tumors ? Audit on one year's experience in SouthEast Scotland. The lancet 1987;14(1):611-2
9. Heimans JJ, De visser M, Polman CH, et al. Accuracy and interobserver variation in the interpretation of computed tomography in solitary brain lesions. Arch Neurol 1990;47(5):520-3

---

## MRI AND US APPEARANCE OF AN INTRAMUSCULAR MYXOMA: A CASE REPORT

Chate SIVASOMBOON, MD.

### ABSTRACT

The author reports a case of an intramuscular myxoma of the left shoulder of a middle-aged woman and discussion of the MRI and US appearance of the lesion as well as the radiological differential diagnosis.

### INTRODUCTION

Myxoma is a mesenchymal tumor composed of stellate-shaped cells in an abundant myxoid matrix.<sup>1</sup> The most common type of myxoma is cardiac myxoma while extracardiac soft-tissue myxoma is much rarer and mostly occur in the muscles of the thigh and shoulder girdle.<sup>1,9</sup> These intramuscular myxomas have distinctive MRI features that distinguish them from all other types of masses except cystic myxoid liposarcomas, which can be problematic.<sup>3,9</sup>

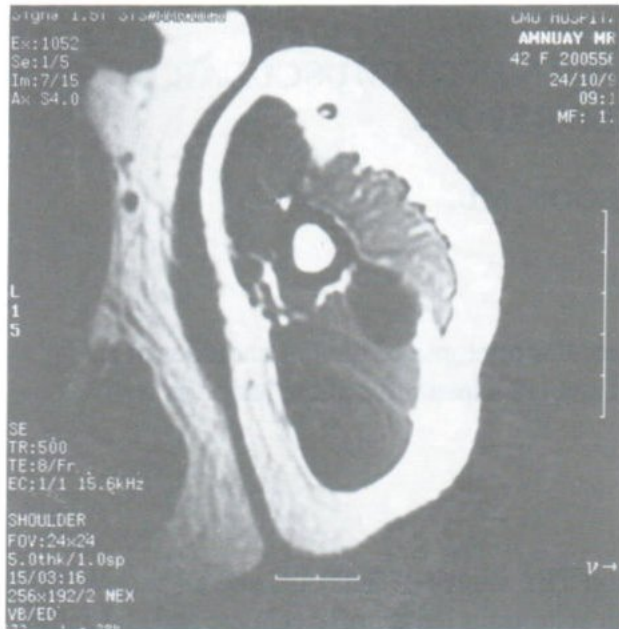
### CASE REPORT

A 42-year-old woman came to the hospital with a lump in her left shoulder that she had had for two months. It was slightly painful. Physical examination showed an ill-defined mass in the proximal part of the left arm, not fixed to the underlying tissues. There were no skin changes. A plain film of the left humerus was normal. Magnetic resonance imaging was performed using a 1.5 Tesla scanner, with the following pulse sequences: 1) a spin-echo T1-wt. pulse sequence with TR/TE 500/8Fr; 2) a dual-echo fast-spin-echo PD- and T2-wt. pulse sequence with TR, TE1,

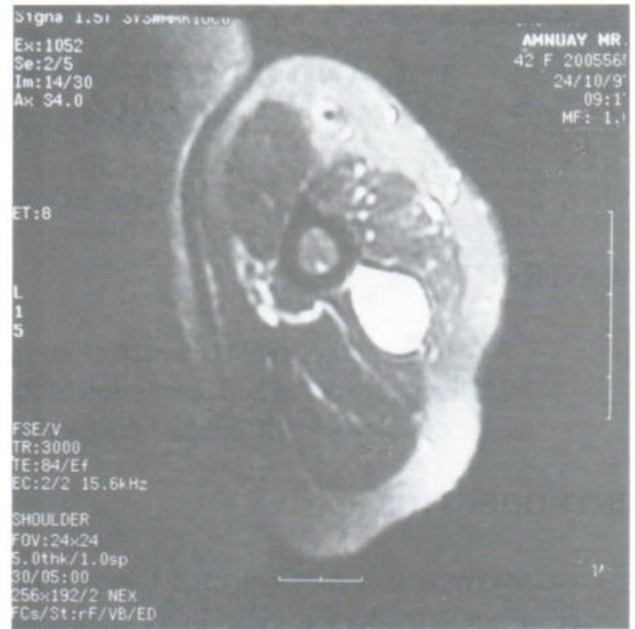
and TE2 values of 3000, 14, and 84 respectively; an echo train length of 8 echoes; and fat saturation. The sections were in axial and coronal planes, with 4-5mm. thickness and 1mm. skip, without enhancement by contrast medium. Ultrasonography of the lesion was also done after the MRI examination.

The MRI study showed an oval well-circumscribed mass in the left upper arm, arising and embedded in the distal portion of the deltoid muscle. It had a homogenous low T1 signal intensity, much lower than that of the muscle, and appeared uniformly very bright on fat-saturated FSE PD- and T2-wt. images resembling a cystic lesion, (Fig.1 and 2). It measured approximately 2.0 x 1.4 x 2.5 cm. and displaced the surrounding muscular bundles, without evidence of invasion. There was no involvement of the adjacent bony structure. Ultrasonographically, the lesion was an oval well-marginated and anechoic with posterior enhancement, surrounded by muscles (Fig 3).

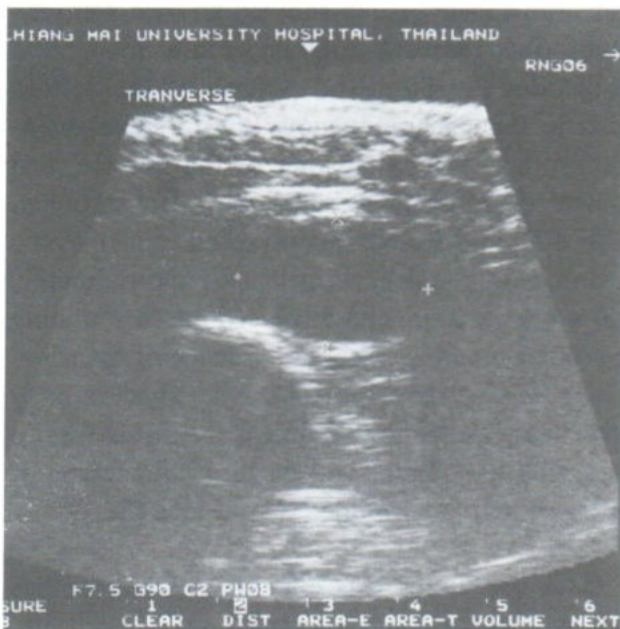The tumor was excised; the histopathological diagnosis was myxoma.



**Fig. 1** Axial T1-wt. image of the left upper arm shows an oval mass with very low homogenous T1-signal-intensity, and good margination, embedded in the distal portion of the deltoid muscle.



**Fig. 2** Axial fat-saturated FSE T2-wt. image, at the same location as Fig 1, reveals a uniformly very bright tumor.



**Fig. 3** An ultrasonographic axial image of the lesion depicts it as an anechoic mass with posterior enhancement in the lateral portion, whereas posterior to the medial portion of the mass, there is curvilinear high echogenicity of the humeral shaft.

**DISCUSSION**

Intramuscular myxomas are rare benign tumors arising in the skeletal muscles, usually in the shoulder or thigh.<sup>1,7,9</sup> The lesion in our case was in the shoulder, especially in the deltoid muscle. The age of patients with these tumors ranges from the fourth to the seventh decade, with females predominating slightly,<sup>1,7,9</sup> as in our case. Histologically, the tumors consist of fibroblast-like, histiocyte-like and myofibroblast-like cells in a myxoid matrix.<sup>9</sup>

The MRI appearance of the lesion in our case was typical of intramuscular myxomas, which show homogenous low T1 and bright T2 signal intensity with well-circumscribed borders.<sup>1,5,7,9</sup> Actually the signal intensities described resemble those of cystic lesions, since fluid and myxoid tissue have the same signal patterns.<sup>1,3</sup> The ultrasonographic findings of the tumor in our case were also the same as those of cystic lesions.

Other lesions with these MRI characteristics are cystic lesions, such as synovial cysts, intramuscular ganglion cysts, and cysticercus cellulose.<sup>1</sup> Synovial cysts occur at the sites of various bursae, which have specific locations relative to the joint. Ganglion cysts may be located near joints or may occur at various other locations, at varying distances from the joint capsule. Demonstration of a small connection between an intramuscular cyst-like lesion and the adjacent joint can confirm the diagnosis of an intramuscular ganglion; however this finding is not consistently detected in every ganglion cyst.<sup>10</sup> Gadolinium enhancement may be useful in differentiating intramuscular myxomas from other cystic lesions, as the tumors may show increased signal intensity nonuniformly.<sup>1,5</sup> Acute hematoma can have the same signal intensity pattern but the clinical signs and symptoms are totally different<sup>1</sup>. Solid tumors that may mimic intramuscular myxomas in MRI appearance are schwannomas and malignant tumors with myxoid degeneration, but usually these tumors have<sup>1</sup> T1 signal intensity equal to or greater than muscle and<sup>2</sup> inhomogenous T2 signal intensity,<sup>1,2,3</sup> and most malignant tumors usually show regions of poor margination, in contrast to the well-circumscribed borders of intramuscular myxomas.<sup>2</sup> As for myxoid liposarcomas, which tend to appear more homogenous on both T1 and T2-wt. images, a majority of them still show mild heterogeneity, possibly with some linear or lacy fatty foci within the tumors, but a minority of the tumors may appear as benign purely cystic masses, with very long T1 and T2 relaxation times and sharply marginated borders, indistinguishable from other benign cystic lesions.<sup>3,4</sup>

The ultrasonographic appearance of our case was typical of cysts. Ganglion cysts or synovial cysts should be considered in differential diagnosis, especially when they are located near joints. Solid masses that ultrasonographically resemble cystic lesions are schwannomas, which

can be hypoechoic with posterior enhancement.<sup>8</sup>

An association between intramuscular myxoma and fibrous dysplasia has been reported in both monostotic and polyostotic forms.<sup>1,9</sup> The tumors tend to occur predominantly in the latter form where they are found adjacent to the severely affected bones, sometimes in multiple. No features of fibrous dysplasia were detected in our patient.

Caution is necessary in interpretation of percutaneous needle aspiration or needle biopsy results of myxoid neoplasms, since some malignant tumors could be diagnosed as intramuscular myxomas.<sup>5,6,7</sup> The MRI appearance of the lesion may assist in the correct diagnosis of an intramuscular myxoma when the lesion is well-circumscribed, arises in the muscle and has uniformly decreased T1 and increased T2 signal intensity as well as inhomogenous contrast enhancement.<sup>5</sup> Otherwise a malignant myxoid tumor should be considered, but even if the above criteria are fulfilled, a possibility of misdiagnosing a cystic myxoid liposarcoma as an intramuscular myxoma still remains and the correct diagnosis can be reached only after excisional biopsy.<sup>3,7,9</sup>

## REFERENCES

1. Abdelwahab AF, Kenan S, Hermann G, Lewis MM, Klein MJ. Intramuscular myxoma: magnetic resonance features. *Br J Radiol* 1992 Jun;65(774):485-90.
2. Berquist TH, Ehman RL, King BF, Hodgman CG, Ilstrup DM. Value of MR imaging in differentiating benign from malignant soft-tissue masses: study of 95 lesions. *AJR* 1990;155:1251-1255.
3. Jelinek JS, Kransdorf MJ, Shmookler BM, Aboulafia AJ, Malawer MM. Liposarcoma of the extremities: MR and CT findings in the histologic subtypes. *Radiology* 1993; 186:455-9.

4. Sundaram M, Baran G, Merenda G, McDonald DJ. Myxoid liposarcoma: magnetic resonance imaging appearances with clinical and histological correlation. *Skeletal Radiol* 1990; 19:359-62.
5. Peterson KK, Renfrew DL, Feddersen RM, Buckwalter JA, el Khoury GY. Magnetic resonance imaging of myxoid containing tumors. *Skeletal Radiol* 1991;20(4): 245-50
6. Whitten CG, el Khoury GY, Benda JA, Ehara S. Case report 829: Intramuscular myxoid chondrosarcoma. *Skeletal Radiol* 1994;23(2):153-6.
7. Caraway NP, Staerkel GA, Fanning CV, Varma DG, Pollock RE. Diagnosing intramuscular myxoma by fine-needle aspiration: a multidisciplinary approach. *Diagn Cytopathol* 1994;11(3):255-61.
8. King AD, Ahuja AT, King W, Metreweli C. Sonography of peripheral nerve tumors of the neck. *AJR* 1997;169:1695-8.
9. Heymans O, Gebhart M, Alexiou J, de Sanint Aubain N, Larsimont D. Intramuscular myxoma. *Acta Chir Belg* 1998;98: 120-2.
10. Malghem J, Vende berg BC, Lebon C, Lecouvet F, Maldague B. Ganglion cysts of the knee: Articular communication revealed by delayed radiography and CT after arthrography. *AJR* 1998;170:1579-83

---

## COMPARISON OF BREATH HOLD MULTI-SLICE HASTE MAGNETIC RESONANCE CHOLANGIOPANCREATOGRAPHY WITH ENDOSCOPIC CHOLANGIOPANCREATOGRAPHY: INITIAL EXPERIENCE

Kumar G, Abdullah BJJ, Rosmawati<sup>1</sup>, Goh KL<sup>1</sup>, Moosa F, Ahmad Sarji S & Bux SI

### ABSTRACT

**OBJECTIVE :** To compare in a prospective and double blinded fashion the accuracy of a new breath-hold multi-slice half Fourier acquisition single shot turbo spin-echo technique (HASTE) magnetic resonance cholangiopancreatography (BHASTE MRCP) against endoscopic retrograde cholangiopancreatography (ERCP) in the diagnosis of patients presenting with biliary and pancreatic pathology.

**PATIENTS AND METHODS :** A total of 20 patients had both breath-hold thin slice MRCP and ERCP. There was no preparation of these patients prior to the breath-hold multi-slice MRCP. The acquisition times for MRCP was 20 seconds. For the MRCP, both the source images and MIP images were evaluated. The results were reported independently by two radiologists. The presence of dilatation, stricture and intraductal abnormalities were recorded. The ERCP was used as the gold standard.

**RESULTS :** MRCP and ERCP finding concurred in all but one patient in whom ERCP failed. An accuracy of 100% (with a sensitivity and specificity of 100%). MRCP was able to show more dilated intrahepatic ducts than ERCP. The presence of fluid in the upper gastrointestinal tract did not obscure any pathology. There were three patients with subcapsular fluid noted. This finding on MRCP has not been previously reported.

**CONCLUSION :** BHASTE MRCP is an excellent non-invasive technique to assess the biliary and pancreatic ducts and may be used to select those patients who require therapeutic ERCP. This may be done without the need for any oral preparation. This will reduce the cost as well as the complications. The additional ability to perform conventional axial MR images at the same sitting with not much extra scanning times makes this examination of choice as well as providing a "road map" for planning intervention. BHASTE MRCP has overcome some of the problems of respiration and volume averaging.

---

Departments of Radiology and

<sup>1</sup> Medicine, University of Malaya Medical Center, Kuala Lumpur, Malaysia.

**Address correspondence: G Kumar**

Department of Radiology, University of Malaya Medical Center, Jalan Universiti, 50603, Kuala Lumpur, Malaysia.

Tel. No. 03-7502069 Fax No. 603-7581973 Email gkumar@medicine.med.um.edu.my

## INTRODUCTION

Magnetic resonance cholangiopancreatography (MRCP) is a new imaging method to non-invasively visualise the biliary and pancreatic ducts (1-6). This method allows the generation of projectional images similar to those of endoscopic retrograde cholangiopancreatography (ERCP) or percutaneous transhepatic cholangiography (PTC). These images are obtained without the need for any kind of contrast medium (oral or intravenous) and depends on the visualisation of fluid within the ducts of the pancreas and liver. In addition this procedure can be carried out on an out-patient basis and therefore may be cost-effective. The role of MRCP has not been defined presently and the absence of any intervention makes it an appealing method to visualise the ducts. Numerous different sequences have been used to generate the MRCP images and we evaluated the accuracy of a new breath hold multi-slice Half Fourier turbo spin echo (HASTE) MRCP to ERCP in evaluating biliary and pancreatic duct pathology

## PATIENTS AND METHODS

A total of 20 patients (9 male and 11 female) with a mean age of 50 years (ranging from 15 to 80 years) who presented to the University of Malaya Medical Center with evidence of either biliary or pancreatic pathology were evaluated in this study. The patients were planned for MRCP prior to ERCP but this was not always possible due to the difficulty in getting access to the MRI scanner. Fourteen MRCP were performed on an average of 3 days (range of 1 to 9 days) prior to ERCP and another six were done on an average of 3 days (range 1-15 days) after ERCP.

The MR images were acquired on a 1.5T Magnetom Vision scanner (Siemens, Erlangen, Germany). A circular polarised array wrap around coil was used for this study. The patients were not prepared in any way prior to the MRCP. No

antiperistaltic agents were given either. An initial coronal and axial localiser images were acquired. From these images three sets of coronal oblique scans (13 each time) using the HASTE sequence were prescribed to cover the entire liver. HASTE techniques use a single slice selective excitation but multiple refocusing radiofrequency (RF) pulses. Each echo is acquired after the application of a different phase encoding gradient pulse. The scanning parameters used for the MRCP are as shown in Table 1. The patients were given instructions of the proper technique for breath holding. The source images from the HASTE sequences were evaluated both individually as well as reconstructed in three dimension (in the coronal plane) using a maximal intensity projection (MIP) algorithm. These three dimensional images were viewed at 15-30° around the cranio-caudal axis. Normal CBD calibre was assumed to be 4-5mm until 50 years with an increase of 1mm per decade thereafter (22).

The patients were admitted and sedated with antibiotic cover prior to ERCP. The ERCP was carried out by two senior endoscopist using a side viewing endoscope (Olympus, Tokyo, Japan). Both the biliary tree and pancreatic ducts were attempted to be demonstrated. Radiographs of the filled ducts were acquired under fluoroscopic visualisation. The examination was ended only when all the necessary data was obtained. The patients were kept in the ward overnight and discharged if there were no complications. The ERCP was considered as the gold standard. Conventional cholangiographic measurement were adjusted for magnification using the endoscope or catheters of known diameters as reference.

The images from the two studies were evaluated blindly by two radiologists independently (BJJA & GK) with the clinical



details provided. Studies where the two readers disagreed on the initial assessment were re-evaluated and agreement reached by consensus. The overall image quality of both studies was graded into three categories: Good, average and poor. Abnormalities of the biliary and pancreatic ducts (dilation, stricture, filling defects as well as other findings) were also evaluated.

## RESULTS

The results are summarised as shown in Tables 2 to 5

**Table 1** Scanning parameters for the breath hold haste sequence

| Parameters         | Values  |
|--------------------|---------|
| TR                 | 15msec  |
| TE                 | 6msec   |
| Flip angle         | 300     |
| Slice thickness    | 10 mm   |
| Scan time          | 16 sec  |
| Distance factor    | 0.0     |
| Matrix             | 240x256 |
| Field of view      | 270 mm  |
| No. of acquisition | 1       |
| Fat saturation     | Yes     |

**Table 2** The number of patients with dilated biliary ducts on MRCP and ERCP.

| Location            | Examination |      |
|---------------------|-------------|------|
|                     | MRCP        | ERCP |
| Common bile duct    | 11          | 10   |
| Common hepatic duct | 14          | 13   |
| Intrahepatic ducts  | 17          | 16   |
| Cystic ducts        | 0           | 0    |

**Table 3** The number of patients with filling defects in the biliary system.

| Location            | Examination |      |
|---------------------|-------------|------|
|                     | MRCP        | ERCP |
| Common bile duct    | 4           | 4    |
| Common hepatic duct | 0           | 0    |
| Intrahepatic ducts  | 2           | 2    |
| Cystic ducts        | 0           | 0    |
| Gall bladder        | 3           | 1    |

**Table 4** Number of patients with strictures of the biliary tree

| Location            | Examination |      |
|---------------------|-------------|------|
|                     | MRCP        | ERCP |
| Common bile duct    | 9           | 8    |
| Common hepatic duct | 3           | 3    |
| Intrahepatic ducts  | 3           | 3    |
| Cystic ducts        | 0           | 0    |

**Table 5** Number of patients with pancreatic duct pathology

| Abnormality     | Examination |      |
|-----------------|-------------|------|
|                 | MRCP        | ERCP |
| Stricture       | 2           | 2    |
| Dilatation      | 2           | 2    |
| Filling defects | 1           | 1    |

## A. IMAGE QUALITY

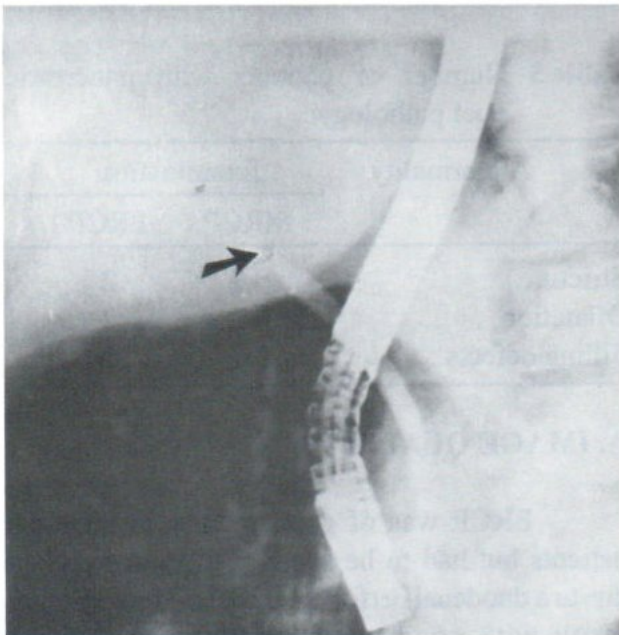ERCP was of good quality in nineteen patients but had to be abandoned in one patient due to a duodenal perforation. MRCP had a similar result with good quality images in nineteen patients. In one patient the presence of breathing artefacts degraded the subsequent MIP images and therefore considered to be of poor diagnostic value. However evaluation of the source images of this patient were considered to be of average diagnostic value. None of the MRCP had to be abandoned.

## B. NORMAL BILE DUCTS

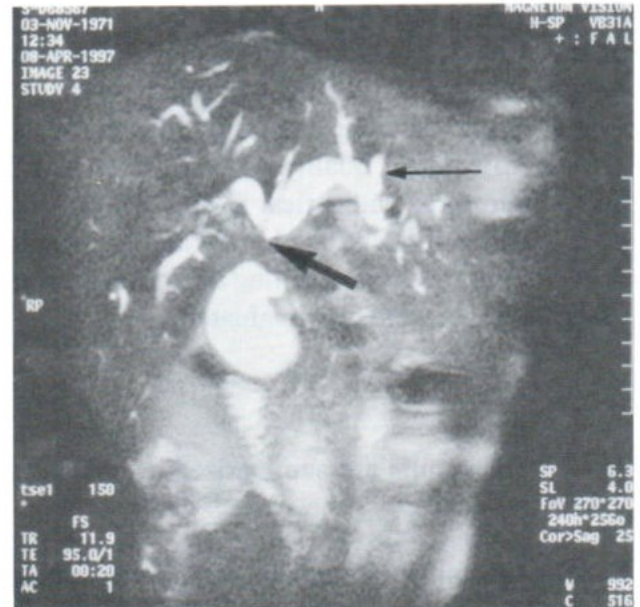MRCP was able to identify all the normal ducts of the liver and pancreas without false positive or false negative.

## C. BILIARY DUCTAL DILATATION

MRCP was able to show a higher number of dilations of the common bile and hepatic and intrahepatic ducts compared to ERCP. This was due to the failure of ERCP in one of the patients. In those patients where MRCP and ERCP concurred the level of obstruction was correctly identified by MRCP. In four patients the MRCP was able to show more intrahepatic ducts distal to a stricture compared to ERCP (Figure 1a, b). In addition MRCP was able to show a higher number of strictures in the common bile duct compared to ERCP because of the single ERCP failure. Otherwise MRCP and ERCP were similar.



**Fig. 1A.** ERCP demonstrating a abrupt narrowing (cholangiocarcinoma) (short arrow) involving the common hepatic duct. The proximal ducts are unopacified



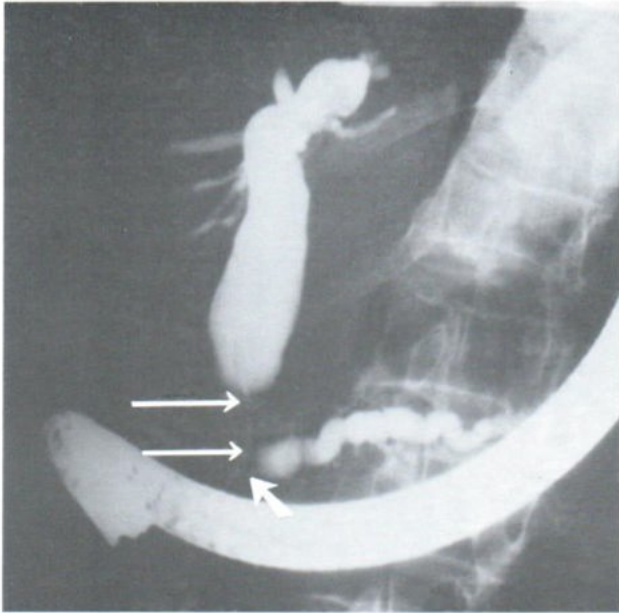
**Fig. 1B.** MRCP demonstrating a tight stricture involving the common hepatic and adjacent right and left hepatic ducts (long thick arrow). Note the dilated proximal intrahepatic ducts (long thin arrow)

## D. SUBCAPSULAR FLUID

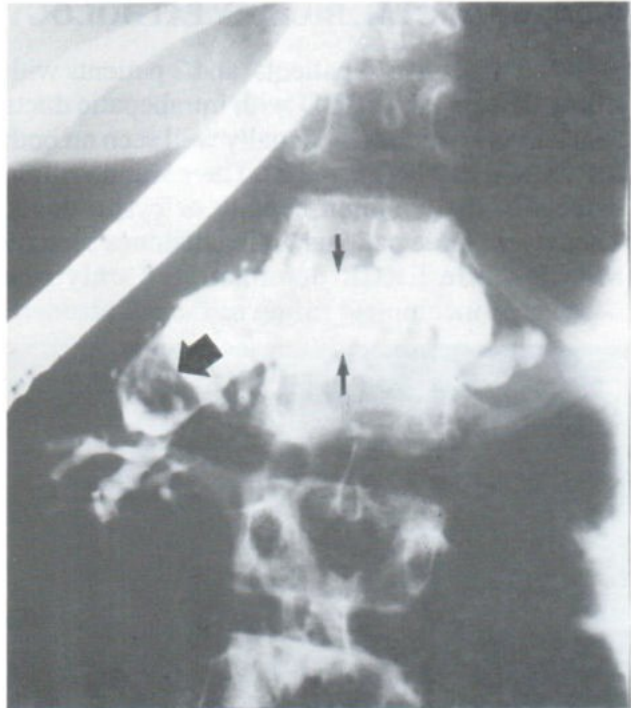
In three patients there was subcapsular fluid seen on MRCP prior to ERCP. Two of these patients had normal MRCP and ERCP studies while the third had dilated left intrahepatic ducts secondary to a cholangiocarcinoma infiltrating the liver. These patients did not have any heart failure or hypoproteinaemia.

## E. BILIARY DUCTAL STRICTURES

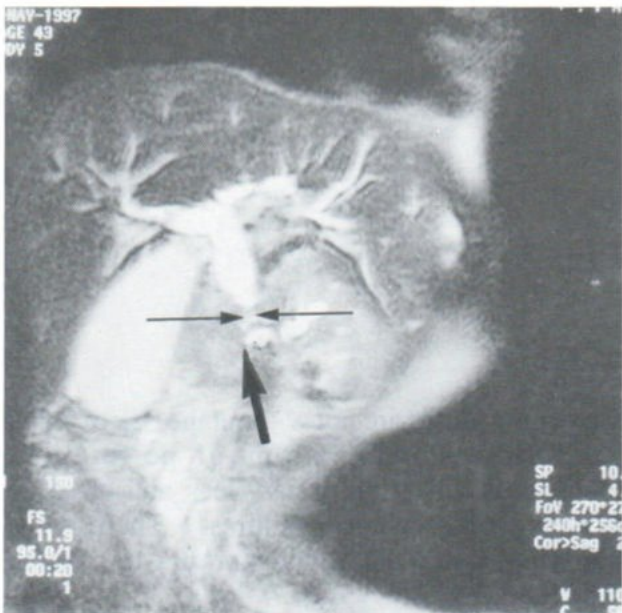
The MRCP and ERCP findings concurred for both the number and location of strictures except for the single ERCP failure where a stricture in the CBD was not demonstrated (Fig. 2a,b).



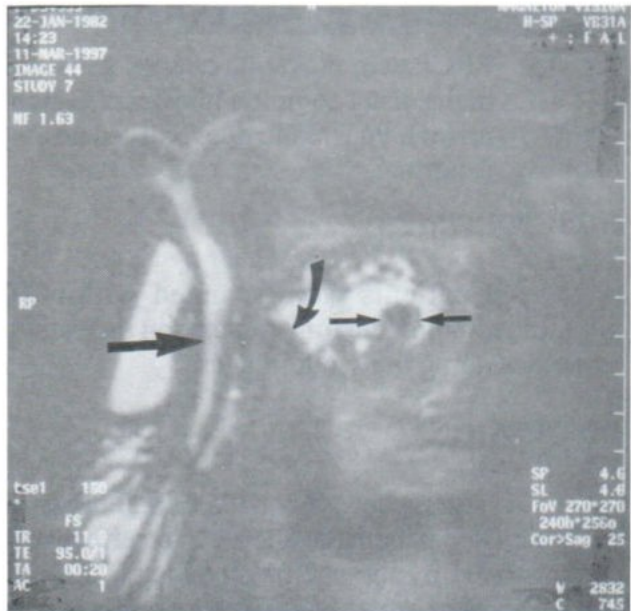
**Fig. 2A.** ERCP in a patient with carcinoma of the head of pancreas with strictured distal ends of common bile duct (long thin arrow) and pancreatic duct (thick short arrow).



**Fig. 3A.** 15 year old patient with chronic hereditary pancreatitis. Dilated proximal and mid pancreatic duct (thin short arrows) with two filling defects (calculi) (thick short arrow) within it.



**Fig. 2B.** MRCP with identical findings - 'the double duct sign' (arrows)



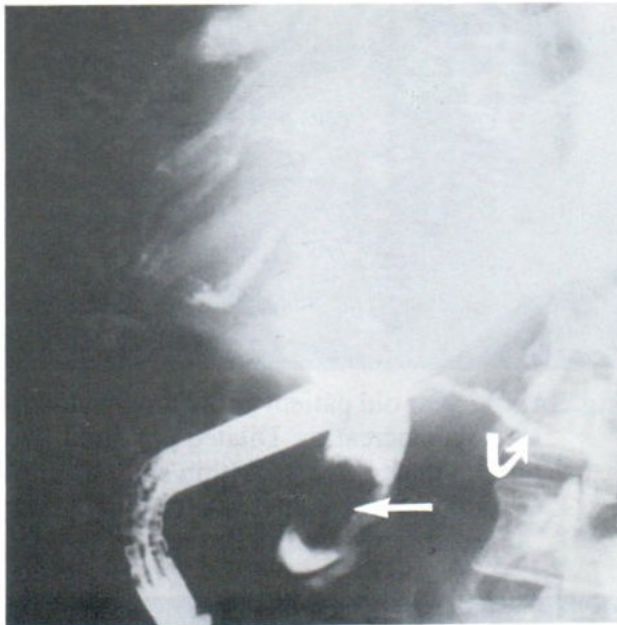**Fig. 3B.** Dilated pancreatic duct with calculi (curved and short thin arrows) and normal common bile duct (long thick arrow).

**F. PANCREATIC DUCT PATHOLOGY**

Again the MRCP and ERCP findings concurred for the presence of strictures, dilatations and filling defects (Fig. 3a,b)

**F. INTRADUCTAL BILIARY PATHOLOGY**

There were 4 patients and 2 patients with filling defects in the CBD with intrahepatic ducts respectively which were equally well seen on both MRCP and ERCP (Fig. 4a,b). There was no filling defects in the common hepatic or cystic ducts. There were three patients with gallstones seen on MRCP while ERCP demonstrated only one because of incomplete filling of the gallbladder.



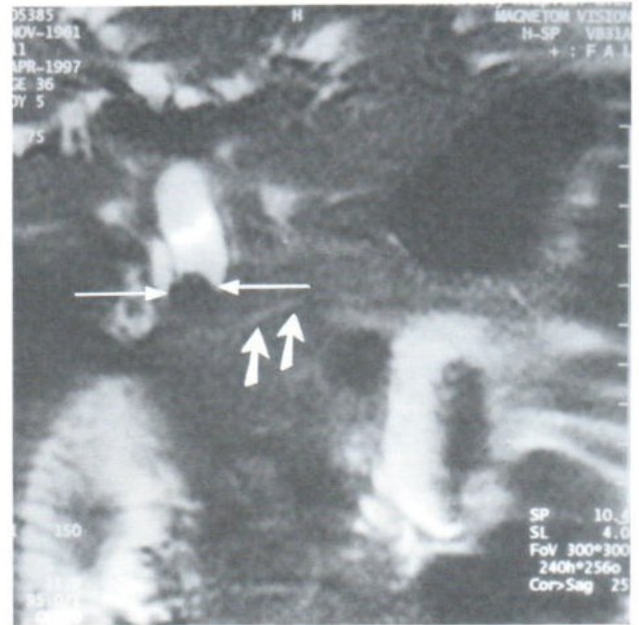
**Fig. 4A.** ERCP demonstrating a large gallstone in the distal common bile duct (straight arrow). Pancreatic duct (curved arrow) is normal.

**H.. SCAN TIMES**

All patients were scanned within 10 minutes including the time to position the patient as well as doing the scout images.

**DISCUSSION**

A significant proportion of pathology of the biliary and pancreatic ducts can be effectively demonstrated by the use of ultrasound, CT and MRI. There are however a subset of patients who would require the use of more invasive procedures like ERCP or PTC to help in making a definite diagnosis though not always for intervention.



**Fig. 4B.** MRCP demonstrating the same finding of a gallstone (long thin arrow) in the distal common bile duct. Normal pancreatic duct (thick straight arrows).

These procedures are not without the risk of small but serious complications of perforation, pancreatitis, infection, biliary leak and bleeding as well as the technical failures. There is the additional cost to the diagnostic work-up of these patients.

MRCP is a rapidly evolving efficient technique for imaging the biliary and pancreatic tree. Projectional images similar to ERCP or percutaneous transhepatic cholangiography (PTC) can be obtained without the use of contrast medium. The images are acquired using long T2

values which gives the bile and pancreatic fluid a high signal. Fluid within the spinal column, gastrointestinal tract lumen (including the consistent demonstration of mucosal detail) and the urinary tract will also be visualised. MRCP shows the calibre of the ducts at rest and therefore may not correlate precisely with the ERCP findings in which over- or underfilling commonly occur. The anatomical spatial resolution however does not match that of ERCP as well as the inability to perform intervention.

Numerous different methods have been reported by different authors to perform MR. Initially a 2-D T2 weighted gradient echo sequence using the steady state free precession (SSFP) during a breath-hold was used to produce images of the biliary ducts.<sup>26</sup> This was subsequently optimised to a 3-D volume acquisition.<sup>11</sup> 3-D MR imaging has been used because of the 3-dimensional nature of the biliary tree and the need for localisation and diagnosis. MRCP has evolved from the use of 3 dimensional breath-hold gradient echo in the steady state precession sequences (CE-FAST, SSFP)<sup>10-12</sup> to breath-hold thick slab RARE acquisition.<sup>13</sup> The former sequences despite being able to detect the presence of biliary obstruction suffered from a low signal to noise ratio, field inhomogeneity with susceptibility effects from bowel gas and surgical clips as well as the presence of blurring due to respiration. Takehara et al<sup>20</sup> developed a 2-D turbo-spin echo which was less susceptible to local inhomogeneities but suffered from breath-holds of 45-60 seconds. This was followed by the use of a respiratory-triggered three dimensional T2 weighted turbo spin-echo sequences.<sup>18</sup> This resulted in long scan times of about 11-16 minutes depending on the respiratory rate. Breath-hold thick slab RARE (rapid acquisition with repeated echoes) acquisition sequence with its breath-holding<sup>13</sup> (less than 16 seconds) have been able to overcome the artefacts due to respiration and achieve a higher signal to noise ratio. The limitation of this method of MRCP has been the inability to view any separate slices where the presence of any fluid filled structure within the imaging volume would generate signal and result in overlap. The presence of ascites would also be problematic since this fluid around

the extra-hepatic biliary tree would obscure the CBD and CHD.

This major problem with the use of thick slab breath-hold MRCP has been overcome by the use of the individual multi-slices in our study and other studies (23,28) in addition to the MIP images where we have had no false positives or negatives. Unlike a study by Regan et al<sup>23</sup> who used 2 sets of images in each axial, coronal and oblique sagittal. The use of this method of MRCP has not been fully explored. We did not evaluate the use of axial images in most of the patients but in several patients the additional conventional MR images done did not take much additional time. These could also be acquired using breath-hold sequences of less than 20 seconds each. Even though MIP images had to be generated from the thin-slice MRCP images this did not take much additional time, in fact the presence of individual slices allowed confirmation of the presence of obstruction, dilatation or filling defects with the MIP images providing an overall impression of the biliary and pancreatic tree rather being used for diagnosis most of the time.

HASTE is a half-Fourier acquisition single shot spin-echo technique.<sup>23</sup> It has been applied to MR urography, MR myelography and MR hysterosalpingography. An average of 13 slices/breath-hold / This yields heavily T2 weighted images. HASTE has low magnetic susceptibility to artefacts from bowel gas/respiration or surgical clips. This is a modification of the RARE sequence where the longitudinal magnetisation of the fully relaxed spin system is used.<sup>23</sup> Each slice image is acquired following a single excitation where slightly more than half the lines of K-space are acquired, with the remainder being extrapolated using a half-Fourier reconstruction. The signal drops by approximately 30%. Up to 128 echoes can be generated after a single excitation with each echo being individually phase encoded.

There was excellent suppression of background tissue with the use of frequency selective fat suppression on the breath-hold thin-slice MRCP sequences. The use of the individual slices also overcome the problem of volume

averaging with the use of breath-hold thick-slab sequences. The ability to use three different slabs as well as the ability to orientate the slabs in any direction allows one to ensure that the imaging volume is being sampled.

The reported accuracy of MRCP is difficult to compare with ERCP since there have been numerous different sequences used. In addition there has been ongoing software developments with shorter scan times. Good image quality, the number and location of biliary strictures, choledocholithiasis has been reported to be greater than 90%.<sup>1,5,6</sup> The sensitivity of classifying benign and malignant strictures is 50% and 80% respectively.<sup>1,3</sup> In our study the sensitivity and specificity of detecting biliary dilatation, strictures as well as intraductal filling defects was 100%. This may be due to the small sample size but we feel that the availability of the thin multi-slice images have been very helpful.

The presence of subcapsular fluid has not been previously reported. We have not been able to determine the cause of this appearance. This is not probably related to obstruction as there patients with and without biliary obstruction. This is not related to any intervention as the MRCP were done before ERCP. There was no evidence of hypoalbuminaemia or evidence of heart failure. We have also not noted this appearance during MR urography even in those patients with perinephric fluid. Further work needs to be done to ascertain the cause of these appearances.

The advantages of MRCP over ERCP are the total absence of invasiveness, ionising radiation, any form of contrast medium (which increases the safety as well as reducing the cost) or sedation as well as the shorter examination times. The procedure which we use can be completed within 10-15 minutes with the actual examination taking less than 5 minutes. MRCP is being carried out as an out-patient procedure without any preparation though in previous work patients were fasted<sup>23</sup> or were required to drink water to fill the duodenum.<sup>25</sup> No antiperistaltic drugs were used in our study,<sup>25</sup> but this has been used in a study by Laghi et al.<sup>25</sup> From the results

of our study we conclude that there is no real necessity for multiple acquisition as was done by Regan et al.<sup>23</sup> In addition the ability to perform conventional MRI studies at the same setting would obviate the need for any other form of imaging like CT or US. The cost of the MRCP at the University of Malaya Medical Center is approximately RM 300 compared to RM 1200 for a diagnostic ERCP since the procedure does not require the assistance of more than a single technician unlike ERCP. The demonstration of dilated ducts proximal to an obstruction may not always be well demonstrated with ERCP since this may result in an increased risk of infection.

Some of the reported potential problems with MRCP include those who are unsuitable for MRI e.g. pacemakers and claustrophobia. A major potential problem has inability of MRCP to differentiate stones from signal void due to aerobilia or mucus plugs.<sup>15</sup> Though it has not been reported there is the potential pitfall of haemorrhage or infection causing a change in the T2 values. The low spatial resolution of present MRCP methods do not allow for the visualisation of the smaller pancreatic ducts. This may therefore be a problem in the diagnosis of mild to moderate pancreatitis. However the ERCP features themselves do not correlate well with the actual clinical condition of pancreatitis.<sup>14</sup>

In our study the vast majority of patients were able to breath-hold for the duration of the scans despite some of them being elderly and quite unwell. We attribute this to proper instructions prior to the examination and some hyperventilation. This however may be problem in the very sickly. The further reduction in scanning times e.g. echo-planar imaging may reduce this problem. The use of single shot fast spin echo sequences where a single slice is acquired at a time within a second may also reduce the risk of respiratory misregistration.

Similar to a study by Beracraft et al<sup>13</sup> we found that the presence of fluid in the second part of the duodenum helpful in determining the position of ampulla and confirmation that the entire CBD had been visualised. However we

found that not fasting the patients prior to the MRCP did not obscure the ampulla or CBD due to the thin slices and may have been in fact been better. We feel that the lack of preparation may be another advantage of this breath-hold thin slice MRCP method.

A recognised limitation of this study was the there was a delay in the MRCP after ERCP but this was due purely due to logistical reasons. We however feel that this should not have made a difference since any interventions would resulted in decompression of the biliary tree any a loss of sensitivity of MRCP but on the other hand the injection of iodinate water soluble contrast medium in ERCP should resulted in false positives due to distension of the biliary tree. This was not the case in our study.

MRCP was able to diagnose accurately both the presence and level of biliary obstruction. In addition the demonstration of filling defects was also accurate. In the one patient despite the respiratory motion, diagnostic quality images were acquired. This compares with both a failure and complication of ERCP in one patient. In our 2 patients with pancreatic pathology MRCP and ERCP concurred in the detection of strictures, dilatations and filling defects.

The current status of MRCP may therefore reduce the need of ERCP in those patients with normal ducts and allow planning of the therapeutic ERCP by demonstrating the level and level of obstruction. The cause of dilatation can also be demonstrated. ERCP cannot be carried out in patients who have had had previous gastric surgery, gastric outlet obstruction, tight strictures of the biliary and pancreatic ducts.<sup>16,18,19</sup> There have also been suggestions that MRCP may be performed prior to laparoscopic<sup>17</sup> surgery to detect significant anatomical variants. MRCP may also have a role in the follow-up screening test in patients with suspected abnormality of the biliary and pancreatic duct system.<sup>21</sup>

## CONCLUSION

Breath hold thin slice Half Fourier turbo

spin echo (HASTE) MRCP has the ability to demonstrate both normal and abnormal biliary and pancreatic ducts. It's accuracy is equal if not better than ERCP without the risk and at a lower cost. In addition MRCP is able to evaluate the liver, pancreas and other abdominal organs cross-sectionally if so desired with very little increase

in the scanning times. We conclude that MRCP will be the non-invasive imaging modality of choice in the assessment of biliary and pancreatic duct pathology. It be the first line of investigation in these patients prior to proceeding to ERCP.

## REFERENCES

1. Hintze RE, Adler A, Vetzke W et al. Clinical significance of MRCP compared to ERCP. *Endoscopy* 1997;29:182-187
2. Metha SN, Reinhold C, Barlum AN. Magnetic Resonance Cholangiopancreatography. *Gastrointestinal Endoscopic Clinics of North America* 1997;7:247-270
3. Ng KK, Wan YL, Lui KW et al. Three-dimensional Magnetic Resonance Cholangiopancreatography for evaluation of obstructive jaundice. *Journal of Formosa Med. Assoc.* 1997;96:586-592
4. Pavone P, Laghi A, Catalano C et al. Non-invasive evaluation of the biliary tree with MRI: onital experience. *Ital J. Gastroenterol* 1996;28:63-69
5. Guibaud L, Bret PM, Reinhold C et al. Bile duct obstruction and choledocholithiasis: diagnosis with MR cholangiography. *Radiology* 1995;197:109-115
6. Soto JA, Barish MA, Yucel EK et al. MR cholangiography: comparison with ERCP. *Gastroenterology* 1996;110:589-797
7. Axon ATR. Endoscopic retrograde cholangiopancreatography in chronic pancreatitis. Cambridge classification. *Radiological Clinics of North America* 1989;27:39-50
8. Cotton PB, Lehman G, Vennes J et al. Endoscopic sphincterotomy complications and their management: an attempt at consensus. *Gastrointestinal Endoscopy* 1991;37:383-393

9. Lo SK, Chen J. The role of ERCP in choledocolithiasis. *Abdominal Imaging* 1996;21: 120-132
10. Wallner BK, Schumacher KA, Weidenmaier W et al. Dilated biliary tree. Evaluation with MR cholangiography with T2 weighted contrast enhanced fast sequence. *Radiology* 1991;181:805-808
11. Moritomo K, Shimoi M, Shirakawa T et al. Biliary obstruction: evaluation with three dimensional MR cholangiography. *Radiology* 1992;183:578-580
12. Hall-Craggs MA, Allen CM, Owens CM et al. MR cholangiography: clinical evaluation in 40 cases. *Radiology* 1993;189: 423-427
13. Bearcroft PW, Gimson A & Lomas DJ. Non-invasive Cholangio-pancreatography by breath-hold magnetic resonance imaging: preliminary results. *British Journal of Radiology* 1997;52:345-350
14. Freeny PC. Classification of pancreatitis. *Radiologic Clinics of North America* 1989;27:1-3
15. Jones SN, Lees WR, Frost RA. Diagnosis and grading of chronic pancreatitis by morphological criteria derived from ultrasound and pancreatography. *Clinical Radiology* 1988;39:43-48
16. Soto JA, Yucel EK, Barish MA et al. MR cholangiopancreatography after unsuccessful or incomplete ERCP. *Radiology* 1996;199:91-98
17. Taourel P, Bret PM, Reinhold C et al. Anatomic variants of the biliary tree: Diagnosis with MR cholangiopancreatography. *Radiology* 1996;199:521-527
18. Soto JA, Yucel EK, Barish MA et al. Pancreatic duct: MR cholangiopancreatography with a three dimensional fast spin-echo technique. *Radiology* 1995;196: 459-464
19. Bret PM, Reinhold C, Taourel P et al. Pancreas divisum: Evaluation with MR cholangiopancreatography. *Radiology* 1996;199: 99-103
20. Takehara Y, Ichijo K, Tooyama N et al. Breath-hold MR cholangiopancreatography with a long-echo-train fast spin-echo sequence and a surface coil in chronic pancreatitis. *Radiology* 1994;123:73-78
21. Ishizu H, Takahashi M, Kondo Y et al. The role of Magnetic Resonance cholangiopancreatography after resection of the pancreas. *Surgery Today* 1997;27:285-287
22. Gore RM, Levine MS, Laufer I. *Textbook of Gastrointestinal Radiology* 1<sup>st</sup>. ed. Philadelphia. Saunders 1984:1587
23. Regan F, Fradin J, Khazan R et al. Cholelithiasis: evaluation with MR cholangiography. *Am J Radiology* 1996;167: 1441-1445
24. Soto JA, Barish ME, Yucel K et al. MR cholangiopancreatography: findings on 3D fast spin-echo imaging. *Am J Radiology* 1995;165:1397-1401
25. Laghi A, Pavone P, Catalano C et al. Magnetic Resonance Cholangiopancreatography : Technique and clinical results. *Asian Ocenian J Radiology* 1997;1:11-16
26. Wallner BK, Schumacher KA, Weidenmaier W et al. MR cholangiography with T2 weighted contrast-enhanced fast sequence. *Radiology* 1991;181:805-808
27. Hirohashi S, Hirohashi R, Uchida H et al. MR cholangiopancreatography and MR urography: improved enhancement with a negative oral contrast agent. *Radiology* 1997;203:281-285.



---

## MR IMAGING OF AN EXTRAABDOMINAL DESMOID TUMOR OF THE SUPRACLAVICULAR AREA

Chate SIVASOMBOON, MD.

### ABSTRACT

Extraabdominal desmoids are benign but locally aggressive tumors, some of which have the appearance on MRI as malignant neoplasm. A case of a pathologically-proven extraabdominal desmoid of the left shoulder involving left levator scapulae muscle is presented with discussion of MRI features of the lesion that may help in preoperative radiological diagnosis, along with a review of literature.

### INTRODUCTION

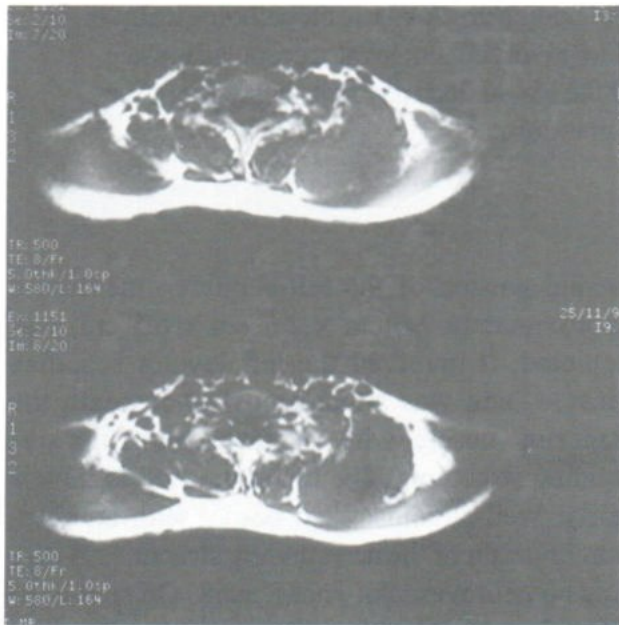
Extraabdominal desmoids are rare benign but locally invasive fibrous tumors. One of their common locations is the supraclavicular region. MR imaging is useful for their evaluation. Although MRI appearances vary, some MRI features may help to differentiate them from other neoplasms. The extent of local invasion is best shown by MRI, even though it might not be fully depicted. We present the MRI findings of a patient with an extraabdominal desmoid of the levator scapulae muscle which had some MRI features that strongly suggested the diagnosis and turned out to have an unsuspected involvement of the adjacent muscles at surgery.

### CASE REPORT

A 39-year-old male patient had had left shoulder pain for a few days, and he had noticed a lump in his left shoulder 4 to 5 months previously. Physical examination revealed a mass in the medial portion of his left shoulder, approximately 5cm. in diameter. There were no overlying skin changes and no signs nor symptoms of neurovascular involvement were detected. There was no limitation of the movement of the left shoulder. On MRI, a large mass in the left lower neck and

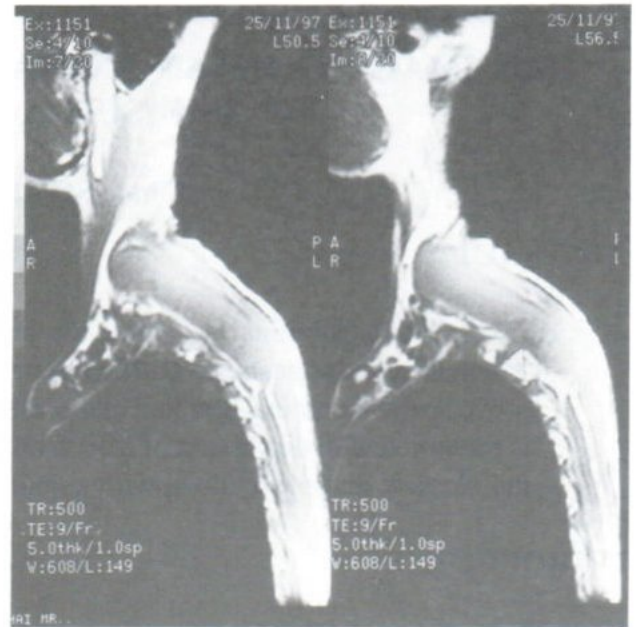
medial portion of the left shoulder, measuring approximately 9.6 cm x 2.5 cm x 6.5 cm, was depicted. It involved the left levator scapulae muscle and was situated just underneath the trapezius muscle, with displacement of the surrounding structures. The tumor seemed to have a fairly well-circumscribed border with no obvious invasion of the surrounding structures. There was no neurovascular encasement. On spin-echo T1-wt. images, it had low T1 signal intensity similar to muscle, with a small stellate dark area in the posterior inferior portion of the mass (fig. 1,2). Overall it had bright T2 signal intensity on T2-wt. Images, which were acquired with a fast-spin-echo sequence with fat saturation. A stellate dark area corresponding to the one seen on T1-wt. images was conspicuous on T2-wt. images and additional small stellate and reticular areas of dark T2 signal intensity were evident in the superior portion of the mass (Fig 3,4). After 10 ml. of gadolinium injection, most of the lesion showed a strong enhancement, except the dark unenhanced stellate area, seen on the above T1- and T2-wt. Images (fig. 5, 6). The total extent of the mass was clearly depicted on both T2-wt. and contrast-enhanced T1-wt. images.

A wide excision was performed with the finding that the tumor also involved the adjacent trapezius and supraspinatus muscles. The histopathological diagnosis was aggressive fibromatosis or extraabdominal desmoid and the margins of the resected specimen were clear of tumor cells. No recurrence was detected after a year of follow-up by physical examinations.

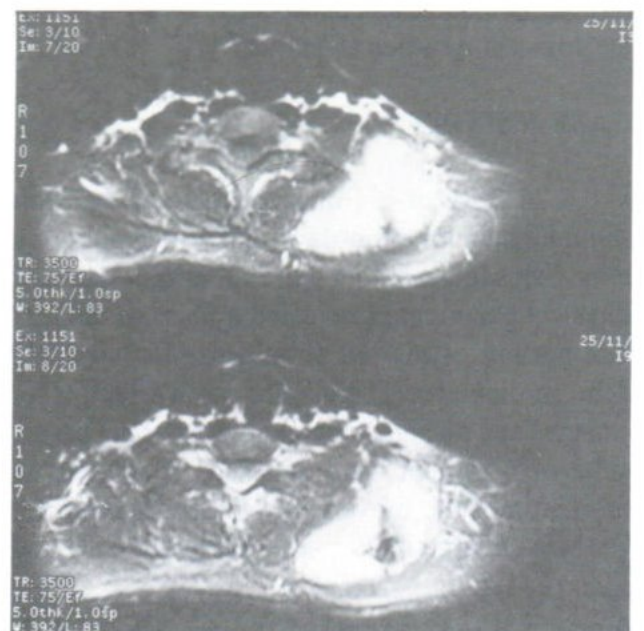


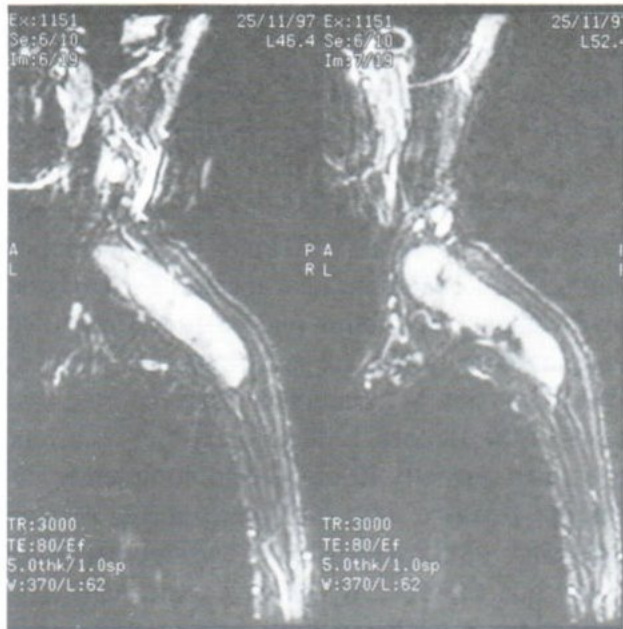
**Fig 1.** Axial spin-echo T1-wt. images (TR/TE: 500/8) of the supraclavicular regions show a large oval mass in the left supraclavicular region with a signal intensity similar to that of skeletal muscle and containing a stellate T1-hypointense area in the posterior portion (arrowhead).

**Fig 3.** Axial FSE T2-wt. images with fat saturation (TR/TE/ETL: 3500/75/8) in the same locations as the axial T1-wt. images depict a T2-hyperintense mass with a fairly well-defined margin and a prominent stellate dark area in the posterior portion, corresponding to the one noted on the axial T1-wt. images.

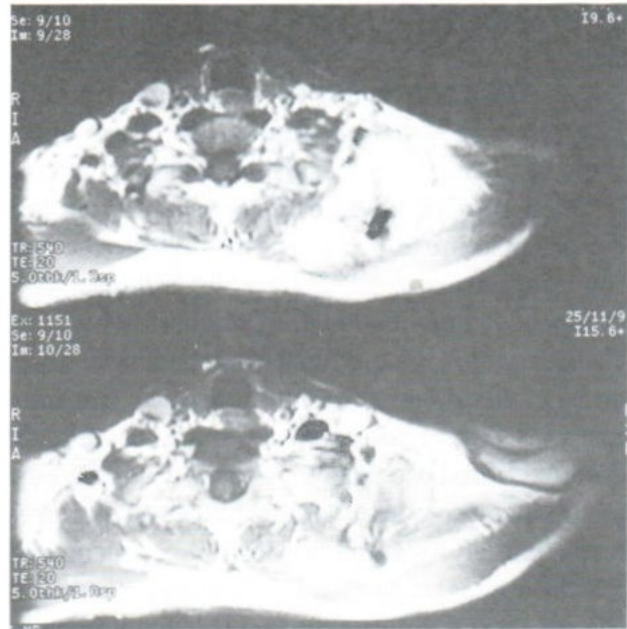


**Fig 2.** Sagittal spin-echo T1-wt. images (TR/TE: 500/8) of the left supraclavicular region show an elongated mass with well-defined border beneath the trapezius muscle. A dark stellate area is seen in the inferior portion (arrowhead).

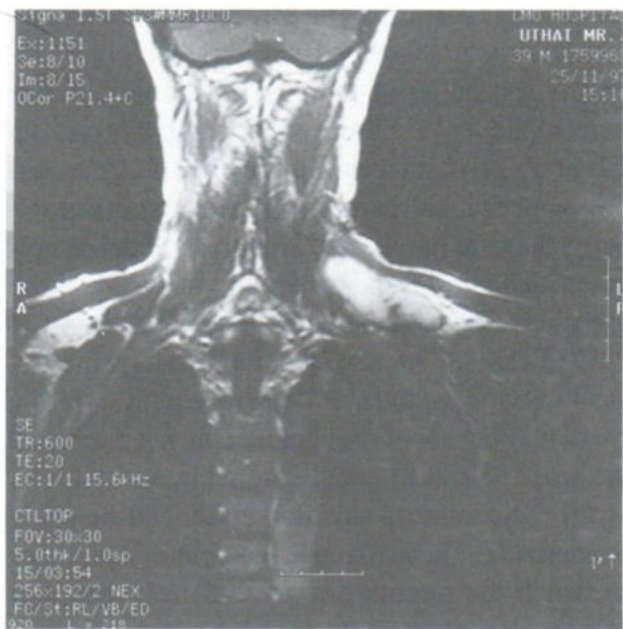




**Fig 4.** Sagittal FSE T2-wt. images with fat saturation (TR/TE/ETL : 3000/80/8) corresponding to the sagittal T1-wt. images demonstrate a T2-hyperintense mass with a dark stellate area inferiorly and reticular dark areas superiorly. The mass is well-defined.



**Fig 5.** Axial postcontrast T1-wt. images (TR/TE: 540/20) show that the mass in the left supraclavicular region is strongly enhanced with an unenhanced dark area in the posterior portion corresponding to the one seen on the T1- and T2-wt. images.



**Fig 6.** Coronal postcontrast T1-wt. image shows the location of the mass in the supraclavicular region, beneath the trapezius muscle. Note the normal levator scapulae muscle on the contralateral side.

## DISCUSSION

Desmoid tumors or aggressive fibromatoses are rare soft tissue tumors which are histologically benign but locally aggressive, arising from connective tissue of muscle, overlying fascia or aponeuroses, and tend to involve the surrounding structures.<sup>1,4,5</sup> They are a subset of a group of lesions called fibromatoses which are classified into (1) superficial (fascial) fibromatoses and (2) deep (musculoaponeurotic) fibromatoses.<sup>2,3,5</sup> Extra-abdominal desmoids or extraabdominal fibromatoses belong to the second group, which also includes two other types of fibromatoses, namely: abdominal desmoids (abdominal fibromatoses) and intraabdominal desmoids (intraabdominal fibromatoses).<sup>2,5,7</sup> Histologically, the tumors show an infiltrative growth pattern and comprise of proliferating fibroblast cells within a matrix of variable amounts of collagen and ground substance, without evidence of cellular anaplasia.<sup>3,4,5</sup>

The incidence of these tumors was previously estimated to be from 3 to 4 per 1,000,000 people per year; they were thought to be much rarer than abdominal desmoids.<sup>7</sup> However, data from large pathological series have shown that the overall incidence of extraabdominal desmoids in various anatomical locations is the same as that of abdominal desmoids.<sup>5,6</sup> Seventy percent of the patients are between 25 to 45 years old<sup>5</sup> with female subjects predominating slightly.<sup>6</sup> They are found in every part of the body<sup>6</sup> but usually in the lower limb or pelvic girdle and the shoulder region.<sup>4</sup> The tumors most commonly arise in the intramuscular or intermuscular compartments, but they also occur rarely in the subcutaneous and juxtacortical locations.<sup>4</sup> Multicentricity is rare and usually the tumors are located in the same extremities, oriented along their long axes.<sup>1,3,4</sup> Due to their invasiveness, they tend to recur after resection, recurrence rates being as high as to 65%-70%,<sup>1,4</sup> and these recurrent tumors tend to be more aggressive

than the primary ones.<sup>4,5</sup> Some tumors may regress<sup>2,4</sup>; sarcomatous degeneration is very rare.<sup>3</sup>

Their MRI appearances and signal intensities vary, sometimes with invasion of surrounding soft tissue, neurovascular encasement and bone involvement, resembling malignant lesions.<sup>1</sup> The margins of the tumors are sometimes well-defined, sometimes not. Many authors have reported that most of the tumors, both primary and recurrent ones, had partially ill-defined to completely ill-defined margins with high percentages of surrounding soft tissue invasion,<sup>1,2,4</sup> while others have found that the majority of their cases had well-defined tumors,<sup>5,7,8</sup> including the recurrent ones.<sup>5</sup> The tumors usually appear fairly homogenous on T1-wt. images and heterogenous on T2-wt. images.<sup>2,4</sup> On T1-wt. spin echo images, they have a signal intensity ranging from much lower than muscle or equal to fat,<sup>7</sup> but generally the tumors are isointense or slightly hyperintense relative to skeletal muscle.<sup>1,2,4,7</sup> On T2-wt. spin echo images, the predominant signal intensity is typically intermediate between skeletal muscle and subcutaneous fat or isointense with fat, but their signal intensity can be equal to or lower than muscle or higher than fat.<sup>1,2,4,7</sup> Areas of hypointensity on both T1- and T2-wt. images may be present in the central or peripheral parts of the lesions; histologically, they are correlated with areas of dense collagen deposition and hypocellularity.<sup>1,4,5</sup> These areas have been reported to be present in 40 to 90% of cases.<sup>1,5</sup> Most of the tumors show moderate to strong gadolinium enhancement, while a small number show slight or no enhancement, and the areas of low T1 and T2 signal intensity found within the tumors are not enhanced at all.<sup>2,4</sup> Romero et al.<sup>5</sup> have found that in four of their cases in which the tumors did not enhance, they also had low signal intensity on T2-wt. images, probably due to the presence of dense collagen tissues. Although the MRI appearances of the tumors vary,

the presence of these unenhanced low T1 and T2 signal intensity areas within the tumors strongly suggests desmoid tumors or fibromatoses.<sup>1,8</sup> Other malignant tumors such as fibrosarcomas may contain areas of low signal intensity on T2-wt. images, but these areas may not be detected on T1-wt. images and their T2 signal intensity is not as low as it is in desmoid tumors.<sup>1</sup> In case of a recurrent desmoid, it must be differentiated from a post-surgical scar and hematoma.<sup>1,4</sup>

The MRI findings in our case were typical of extraabdominal desmoids or fibromatoses, having well-circumscribed border, T1 isointensity with the muscle, T2 hyperintensity, a strong gadolinium enhancement and a low intralesional T1 and T2 signal area which did not enhance. However, on T2-wt. images, the signal intensity could not be compared with that of fat because of the use of a fast-spin-echo technique with fat saturation. Even though the tumor appeared well-circumscribed, invasion of the adjacent muscles was found at an excision, reflecting the infiltrative growth pattern of the tumor. The patient was also in the common age range and the tumor was located at one of the common sites.<sup>2</sup>

Pathogenesis of the tumors is unclear; there are some factors that may contribute to it, including previous trauma, surgery, radiotherapy and some hormonal factors related to pregnancy.<sup>3,4,5</sup> While intraabdominal desmoids are associated with Gardner Syndrome,<sup>5</sup> extraabdominal desmoids have been reported with melorheostosis.<sup>9</sup> In juvenile patients with desmoid tumors, an increased frequency of connective tissue anomalies has been noted and these tumors tend to be more aggressive than those occurring in adult patients.<sup>5</sup> The best treatment is en-bloc resection of the tumors, but involvement of important neurovascular structures can prevent complete surgical resection, and recurrence rates of subtotal resection may be as high as 70%.<sup>2,3</sup> Radiation therapy or adjuvant medical therapy may have a role in treating these tumors.<sup>3</sup>

## REFERENCES

1. Hartman ET, Berquist TH, Fetsch JF. MR Imaging of Extraabdominal Desmoids: Differentiation from Other Neoplasms. *AJR* 1992;158:581-585.
2. O'Keefe F, Kim EE, Wallace S. Magnetic Resonance Imaging in Aggressive Fibromatosis. *Clinical Radiology* 1990;42:170-173.
3. Garant M, Remy H, Just N. Aggressive Fibromatosis of the Neck: MR Findings. *AJNR* 1997;18:1429-1431.
4. Vandevenne JE, De Schepper AM, De Beuckeleer L, Van Marck E, Aparisi F, Bloem JL. New concepts in understanding evolution of desmoid tumors: MR imaging of 30 lesions. *Eur. Radiol.* 1997; 7:1013-1019.
5. Romero JA, Kim EE, Kim CG, Chung WK, Isiklar I. Different Biologic Features of Desmoid Tumors in Adult and Juvenile Patients: MR Demonstration. *J Comput Assist Tomogr* 1995;19:782-787.
6. Kransdorf MJ. Benign Soft-Tissue Tumors in a Large Referral Population: Distribution of Specific Diagnoses by Age, Sex, and Location. *AJR* 1995;164:395-402.
7. Quinn SF, Erickson SJ, Dee PM, Walling A, Hackbarth DA, Knudson GJ, Moseley HS. MR Imaging in Fibromatosis: Results in 26 Patients with Pathologic Correlation. *AJR* 1991;156:539-542.
8. Kransdorf MJ, Jelinek JS, Mose RP jr, Utz JA, Judson TM, Neal J, Berrey BII. Magnetic resonance appearance of fibromatosis: A report of 14 cases and review of the literature. *Skeletal Radiol* 1990;19: 495-499.
9. Ippolito V, Mirra JM, Motta C, Chiodera P, Bonetti MF. Case report 771: Melorheostosis in association with desmoid tumor. *Skeletal Radiol* 1993;22:284-288.



EDUCATION

## Asian-Oceanian Seminars on Diagnostic and Interventional Radiology

1 9 9 9

### Abdominal Imaging

**February 12-13**

Dhaka, Bangladesh

Programme Leader:

**A.S.Q. Md. Sadeque**

### Musculo-Skeletal Radiology and Mammography

**April 17-18**

Singapore

Programme Leader:

**J. Hoe**

### Chest Radiology

**September 18-19**

Seoul, Korea

Programme Leaders:

**D.S. Kang**

**J.G. Im**



For further information please contact:  
Huntington Communications Pte Ltd  
47 Hill Street #07-03  
S.C.C.I. Building  
Singapore 179365  
Tel: ++65-339 2883  
Fax: ++65-339 2272  
E-mail: [hcompr@singnet.com.sg](mailto:hcompr@singnet.com.sg)

<http://www.bracco.com>

## FIBROLIPOMATOUS INFILTRATION OF THE MEDIAN NERVE

NITINAVAKARN Benjaporn, MD.<sup>1</sup>, JATUPARISUTHI Piyawan, MD.<sup>2</sup>,  
MITCHAI Chumpon MD.<sup>3</sup>.

### ABSTRACT

A case of fibrolipomatous infiltration of the median nerve is presented. A male patient, 19 year-old presented with a mass at his left thumb and palm with gradual enlargement for 5 years. He had numbness of the hand while playing his guitar.

On physical examination, the mass was soft, had an ill-defined border and covered with normal skin. The provisional diagnosis was hemangioma.

Imaging studies including plain film and MRI with MRA which showed an enlarged median nerve with fibrolipomatous infiltration (hamartoma). No soft tissue calcification or abnormal vasculature was seen, so a hemangioma was excluded. Surgery was done to release a "carpal tunnel syndrome" and a biopsy was taken. The histologic diagnosis was compatible with the MRI study.

This is a rare benign lesion. The diagnosis is easy and made possible by MRI imaging and eliminates an invasive angiogram study. We present a case of fibrolipomatous infiltration of the median nerve with a characteristic MRI finding.

**Key Words:** Fibrolipomatous infiltration, Hamartoma, Median nerve.

### INTRODUCTION

Fibrolipomatous infiltration of the median nerve is a rare benign condition. It is a hamartoma. It is easily diagnosed by MRI imaging which shows characteristic finding.

### CASE REPORT

A 19 year-old man presented with a mass along the thenar eminence of the left palm and thumb region for 5 years. This was gradually and slowly enlarging. While playing the guitar, he felt numbness of his palm, which subsided after he stop playing. No history of trauma and no skin

lesions were noted.

On physical examination ; a palpable subcutaneous mass, soft consistency, with an ill-defined border, filling the mid palm extending from the wrist joint to ulnar side of thumb was detected. Tinel sign was positive at the wrist joint. The covering skin was normal. No signs of inflammation were evident.

### IMAGING STUDIES

Plain film of the left hand showed a soft

<sup>1</sup> Department of Radiology

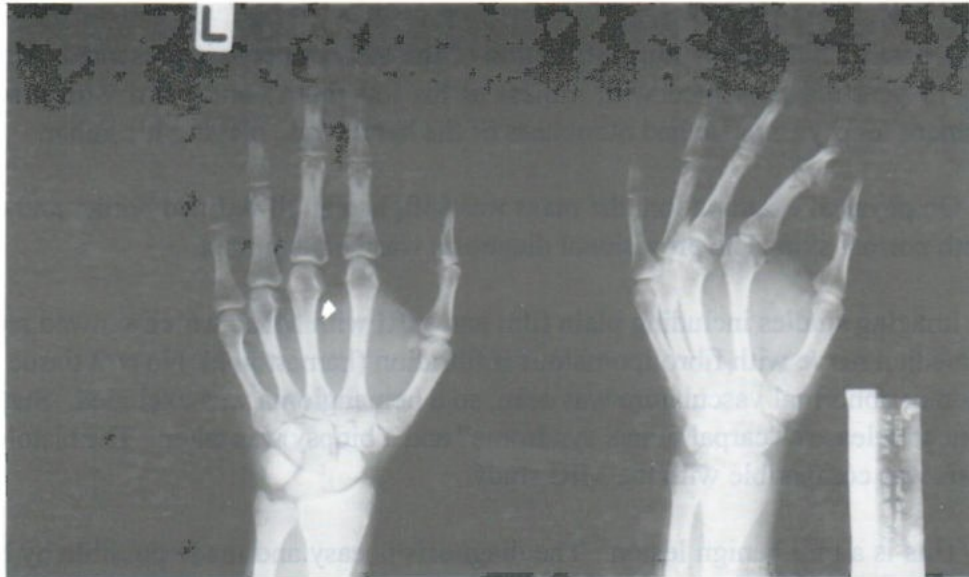<sup>2</sup> Department of Orthopedic Surgery

<sup>3</sup> Department of Pathology, Srinakarind Hospital, Khon Kaen University, Khon Kaen, Thailand, 40002.

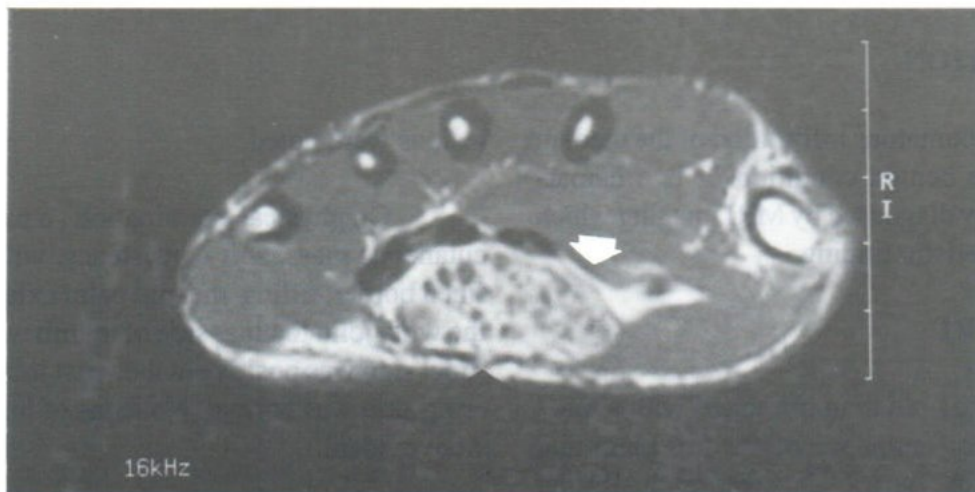
tissue density mass lesion without calcification at thenar region (Fig 1 a, b). Otherwise normal bony structures were observed.

MRI imaging (Fig 2, 3) was requested to rule out hemangioma.

It demonstrates a markedly enlarged median nerve (arrows) with heterogeneous signal intensity consisting of tubes of signal void (nerve fascicles and epi-and perineural fibrosis) and fat signal.

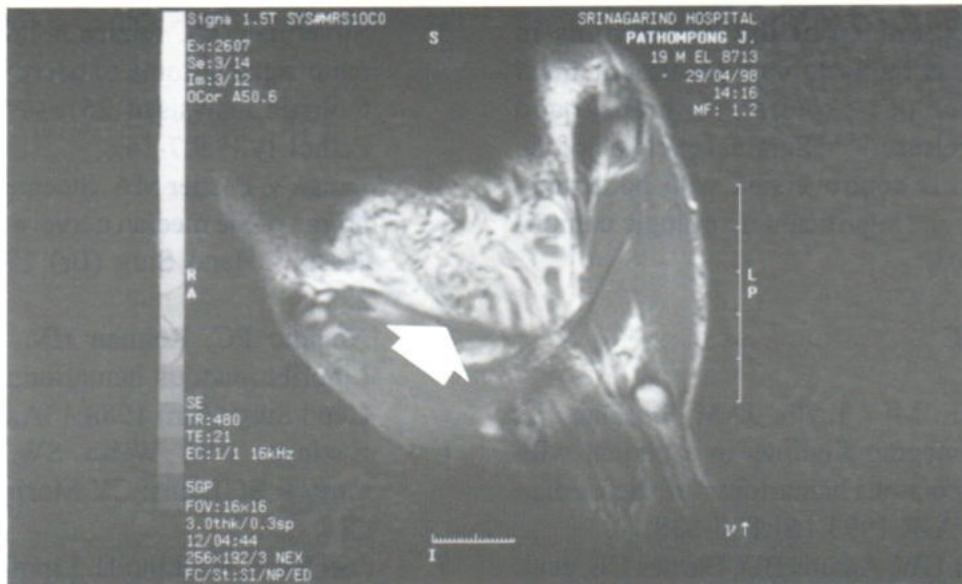

**Fig 1A, 1B** Plain films of left hand in PA and oblique view showed a mass lesion of soft tissue density without calcification in the thenar region (straight arrows) and thumb (curve arrow).



**Fig. 2** Transverse T1W spin echo MR image (TR/TE : 800/21) obtained at the level of carpal tunnel revealing a large mass (arrow) in the median nerve that crowded the flexor tendons dorsally.





**Fig. 3** Coronal T1W spin echo MR image showed longitudinal cylindrical regions of low signal (nerve fascicles) interspersed with high signal intensity (fat) in the volar aspect of hand and wrist.

## DIAGNOSIS

Fibrolipomatous infiltration of the median nerve.

He was operated to release the carpal tunnel syndrome by flexor retinaculum lysis and a biopsy was taken. Post operative course was uneventful. Pathological diagnosis was compatible with MRI findings.

## DISCUSSION

Fibrolipomatous infiltration of the nerve (hamartoma) is a rare benign lesion that involves the median nerve in 80% of cases.<sup>1-6</sup> Tumor involvement of the ulnar and radial nerves and dorsum of the foot has been reported.<sup>1,3,5,7</sup> This entity is most commonly encountered in infants and less commonly in children and young adults.<sup>1,6</sup> Early signs and symptoms are often absent or minimal. Later findings of nerve compression are evident, with pain, motor deficit, and paresthesia<sup>1</sup> alone. With involvement of the median nerve, signs and symptoms of carpal tunnel syndrome may be evi-

dent. Macroductyly of the involved body part may be present in nearly two-thirds of cases.<sup>1,3,5</sup>

The tumor is seen as a rubbery, yellowish tan mass within the nerve sheath. Characteristic histologic findings include abundant perineural and epineural fibrosis and infiltration of mature fat cells in the inter-fascicular connective tissue.<sup>1</sup> Atrophy of nerve fibers has been reported as a late finding. The tumor demonstrates a characteristic appearance on MRI.<sup>1,2</sup> The longitudinally oriented cylindrical regions of signal void seen on all pulse sequences are thought to represent the nerve fascicles and accompanying epineural and perineural fibrosis. Between these structures are areas of high signal on T1-weighted spin-echo images reflective of infiltrating mature fat cells in the inter-fascicular connective tissue.

The differential diagnosis of this entity includes intraneural lipoma, ganglion cyst, traumatic neuroma, and vascular malformations in which the signal voids on MRI could potentially

mimic the appearance of the signal voids in fibrolipomatous hamartoma.<sup>1</sup> Treatment most frequently includes exploration, biopsy, and carpal tunnel release.<sup>1,3,4,6</sup> Surgical excision of the primary lesion is controversial, with both satisfactory results and significant neurologic complications reported.

#### REFERENCE

1. Cavllaro MC, Taylor JAM, Gorman JD, et al. Imaging findings in a patient with fibrolipomatous hamartoma of the median nerve. *AJR* 1993;161:837-838.
2. Walker CW, Adams BD, Barnes CL, et al. Case report 667. *Skeletal Radiol* 1991;20:237-239.
3. Silverman TA, Enzinger FM. Fibrolipomatous hamartoma of nerve: a clinicopathologic analysis of 26 cases. *Am J Surg Pathol* 1985;9:7-14.
4. Langa V, Posner MA, Steiner GE. Lipofibroma of the median nerve: a report of two cases. *J Hand Surg (Br)* 1987;12B:221-223.
5. Amadio PC, Reiman HM, Dobyms JH. Lipofibromatous hamartoma of nerve. *J Hand Surg (Am)* 1988;13A:67-75.
6. Enzinger FW, Wise SW. *Soft tissue tumors*. St. Louis: CV Mosby; 1988:332-334.
7. Jacob RA, Buchino JJ. Lipofibroma of the superficial branch of the radial nerve. *J Hand Surg (Am)* 1989;14A:704-706.

---

## RUPTURE OF RADIOPAQUE TIP OF TORCON NB CATHETER

Komgrit TANISARO

### ABSTRACT

Radiopaque Tip Polyethylene diagnostic catheter was used when selecting the superior mesenteric artery before transarterial chemoembolization in hepatocellular carcinoma patient. A breaking of the catheter at the junction between the radiopaque tip and its shaft was noted. The broken tip was retrieved using 3-F vascular retrieval forcep and surgical cutdown. It was claimed that opacification of the tip could reduce contrast consumption and fluoroscopy time. The use of the radiopaque tip "Torcon NB" catheter requires a high concern regarding possible catheter rupture.

**Keyword:** complication of angiography, catheter complication

Complications of Angiography can generally be divided into three categories: systemic complications, complication related to the puncture site, and complication related to catheter and guidewire. Intravascular foreign bodies due to catheter, guidewire or other equipments and their transluminal retrieval techniques have been occasionally reported.<sup>1-6</sup> Regarding the broken diagnostic catheter, majority of complications have dealt with the fracture of venous catheter, however they are less frequent in the arterial system. Recently, radiopaque-tip "Torcon NB" diagnostic catheter (COOK®, Australia) has been released on the market. We report a catheter complication which may be due to a defect to the structural design of that kind of catheter.

### CASE REPORT

A 62 year-old male with hepatocellular carcinoma was sent for transarterial chemoembolization. A resident was assigned to perform a diagnostic angiography before intervention. Using the 5-F (C2) cobra-shaped "Torcon NB" ra-

diopaque-tip catheter (COOK®, Queensland, Australia) that will accept 0.035 inch or 0.038 inch guidewire, the resident selected the coeliac artery first and a complete angiography was done without technical or anatomical problems. Then she tried to catheterize the SMA to see the replaced hepatic artery or minor feeding artery. After multiple gentle manipulations, she could not select the SMA and decided to change the catheter type. During insertion of the 0.035 inch, Teflon-coated floppy guidewire (Terumo, Japan) the guidewire passed through the tip of the catheter into the aorta. The resident then noticed that the catheter tip was completely broken near the junction between the tip and its shaft.

We were consulted o the angiographic suite. By using a standard angiographic technique, the 3-French vascular retrieval forceps (COOK®, Bloomington,IN,USA) was introduced into the abdominal aorta via the guiding catheter and out the distal end. Under fluoroscopic control, thebroken tip was grasped and retrieved into the right common iliac artery but could not be removed

---


Department of Radiology Hospital of Prince of Songkla University Hatyai, 90110, Thailand

**Correspondence to:** Komgrit Tanisaro, MD

telefax: 074-212900 telephone: 074-212070 e-mail: tkomgrit@ratree.psu.ac.th

through the 8-F vascular sheath after multiple attempts. A vascular surgeon was consulted immediately. The broken fragment was surgically removed via cutdown under local anesthesia.

We examined the removed tip and shaft of the catheter and found that all parts were removed completely without any residual part.(figure-1) The catheter was broken near the junction between radiopaque tip and shaft where the stainless steel braid ends. No immediate complication or distal embolization occurred after the radiological and surgical procedures.



**Fig. 1** Rupture of the catheter near the junction between the radiopaque tip (without metallic core) and its shaft (with metallic core)

## DISCUSSION

The most common iatrogenic foreign bodies are broken through-the-needle polyethylene and diagnostic catheter fragments. Other common objects include a guidewire and guidewire fragments, inferior vena cava filter, intravascular metallic stents and vascular sheaths.<sup>8</sup> Several authors have reported techniques in intravascular retrieval of iatrogenic foreign bodies.<sup>2-6</sup> The tools and techniques must be chosen in accordance with individual circumstances.<sup>7</sup>

For better visualization of diagnostic catheter tip, the Torcon MR or NB catheter (COOK®) was designed and released on the market in 1995. This kind of polyethylene catheter is constructed of two different materials. The shaft is made of a stainless steel core. The tip is a more pliant structure without metallic braid. So, the junction or connection between the two materials provides a weak point where the catheter could fragment. Paul et al.,<sup>9</sup> reported a rupture of this kind of catheter during abdominal angiography in the same way we found.

Recently, highly flexible retrieval devices have been introduced to practical uses. Most devices are specially designed for, but not limited to, intravascular retrieval.<sup>(10,11)</sup> They are smaller and less traumatic than their predecessors.<sup>8</sup> The device we used in this report is arat-tooth forcep which has two diametrically opposed jaws that both contain a single distal tooth.

We can not prove scientifically that a rupture of this kind of catheter is due to structural defect but this is the second report which raises the hypothesis. In conclusion, even it was claimed that opacification of tip could reduce contrast consumption and fluoroscopy time, the use of radiopaque tip "Torcon NB" catheter requires a high concern regarding possible catheter rupture.

## REFERENCES

1. Flisher RG, Ferreyro R. Evaluation of current techniques for non surgical removal of intravascular foreign bodies. *AJR* 1978; 130:541
2. Egglin TK, Dickey KW, Rosenblatt M et al., Retrieval of intravascular foreign bodies: experience in 32 cases. *AJR* 1995; 164:1259
3. Yang FS, Ohta I, Chiang HJ et al., Nonsurgical retrieval of intravascular foreign body: experience of 12 cases. *Eur J Radiol* 1994;18:1
4. Weiele JB, Sheline ME, Cope C. Expandable intravascular catheter: percutaneous use for endoluminal retrieval. *Radiology* 1992;185:604
5. Dondelinger RF, Lepoutre B, Kurdziel JC. Percutaneous vascular foreign body retrieval: experience of an 11 years period. *Eur J Radiol* 1991;12:4
6. Ulflacker R, Lima S, Melichar AC. Intravascular foreign bodies: percutaneous retrieval. *Radiology* 1986;160:731
7. Baum S, Pentecost MJ. *Abrams' Angiography-Percutaneous vascular and nonvascular foreign body retrieval*. Boston: Little, brown; 1997, pp.959
8. Savader SJ, Trerotola SO. *Venous Interventional Radiology with clinical perspectives foreign body retrieval*. New York: Thieme; 1996, pp.459
9. Paul L, Villar R, Sanchez A. Rupture of Radiopaque Tip of the Torcon MR Catheter (letter). *JVIR* 1997;8:300
10. Chomyn JJ, Graven WM, Groves BM et al., Percutaneous removal of a Gianturco coil from the pulmonary artery with use of intravascular forceps. *JVIR* 1991;2:105
11. Selby JB, Tegtmeyer CJ, Bittner GM. Experience with new retrieval forceps for foreign body removal in the vascular, urinary and biliary systems. *Radiology* 1990; 176:535



## SPINAL CORD-SUBARACHNOID SPACE RATIO AT CERVICAL REGION IN NORMAL THAI PEOPLE.

Pichest METARUGCHEEP M.D.

### ABSTRACT

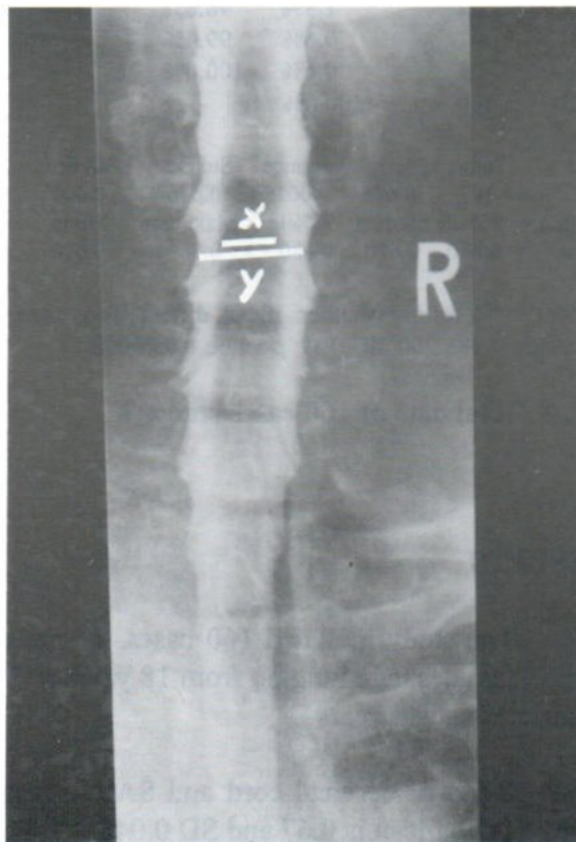
Measurement of transverse diameter of cervical cord & subarachnoid space between C4-C6 region was performed. The ratio between them was analysed in 160 cases of patients suffering from low back without neck symptom and submitted to water soluble myelogram. The normal spinal cord – subarachnoid space ratio (C/SAS) is in the range of 0.57-0.79, mean is 0.67 and SD 0.046. This can be used as the indicator of abnormal size of the spinal cord in myelographic interpretation if the ratio is under 0.57 or above 0.77. (mean + 2SD.)

### INTRODUCTION

Even though, at present, there is modern equipment such as MRI that can be used to investigate the spinal cord, non invasively. But due to the high cost of MRI, spinal cord investigation with contrast (Myelogram) still be necessary. Myelographic picture at cervicothoracic region which is the cervical cord normal enlargement is hard to differentiated form abnormal enlargement from any intrinsic pathology. This is due to no normal value for comparison. So, this come to the study of normal value by measurement of the width of cervical cord and the SAS at same level and by using the ratio of the width of cervical cord and SAS for normal indicator.

### MATERIALS AND METHODS

Data of this study is from the patients that come to investigate by lumbar myelogram and no neck symptom from 1991 to 1996. Addition cervical myelogram was done followed by measurement of the spinal cord width and SAS at C4 to C6 level. The AP view is the standard picture. (Fig. 1) All data are submitted to be analysed and interpreted statistically. (Fig.2 & Fig.3 & Fig.4)



**Fig. 1** Cervical myelogram of normal patient with C/SAS ratio (X/Y) = 0.68

| C/SAS | Freq | Percent | Sum    |
|-------|------|---------|--------|
| 0.57  | 5    | 3.1%    | 3.1%   |
| 0.58  | 6    | 3.8%    | 6.9%   |
| 0.59  | 5    | 3.1%    | 10.0%  |
| 0.60  | 2    | 1.3%    | 11.3%  |
| 0.61  | 4    | 2.5%    | 13.8%  |
| 0.62  | 3    | 1.9%    | 15.6%  |
| 0.63  | 6    | 3.8%    | 19.4%  |
| 0.64  | 10   | 6.3%    | 25.6%  |
| 0.65  | 12   | 7.5%    | 33.1%  |
| 0.66  | 15   | 9.4%    | 42.5%  |
| 0.67  | 29   | 18.1%   | 60.6%  |
| 0.68  | 24   | 15.0%   | 75.6%  |
| 0.69  | 12   | 7.5%    | 83.1%  |
| 0.70  | 3    | 1.9%    | 85.0%  |
| 0.71  | 2    | 1.3%    | 86.3%  |
| 0.72  | 5    | 3.1%    | 89.4%  |
| 0.73  | 3    | 1.9%    | 91.3%  |
| 0.74  | 4    | 2.5%    | 93.8%  |
| 0.75  | 4    | 2.5%    | 96.3%  |
| 0.76  | 2    | 1.3%    | 97.5%  |
| 0.77  | 2    | 1.3%    | 98.8%  |
| 0.78  | 1    | 0.6%    | 99.4%  |
| 0.79  | 1    | 0.6%    | 100.0% |
| Total | 160  | 100.0%  |        |

| Total   | Sum    | Mean   | Variance | Std Dev | Std Err |
|---------|--------|--------|----------|---------|---------|
| 160     | 107    | 0.666  | 0.002    | 0.046   | 0.004   |
| Minimum | 25%ile | Median | 75%ile   | Maximum | Mode    |
| 0.570   | 0.640  | 0.670  | 0.680    | 0.790   | 0.670   |

Student's "t", testing whether mean differs from zero.  
 T statistic = 185.200. df=159 p-value = 0.00000

Fig. 2 Total data of 160 cases study.

**RESULTS**

The study included 160 cases, 77 males and 83 females, age ranging from 18 years to 75 years, average 46 years.

Ratio of cervical cord and SAS is from 0.57 to 0.79, mean is 0.67 and SD 0.046.

C/SAS in male is 0.57 to 0.76, mean 0.66.

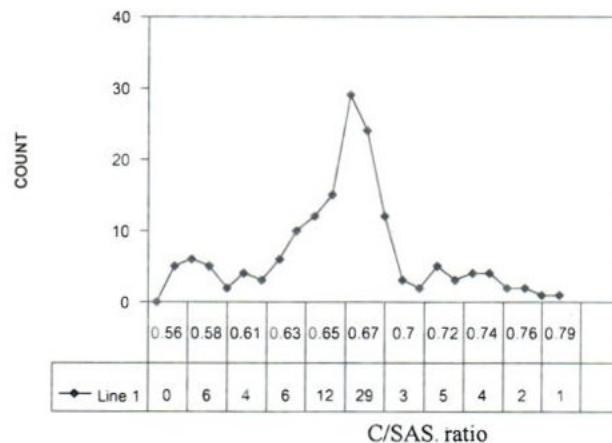


Fig. 3 Graph shows relationship between amounts of the patient and C/SAS ratio.

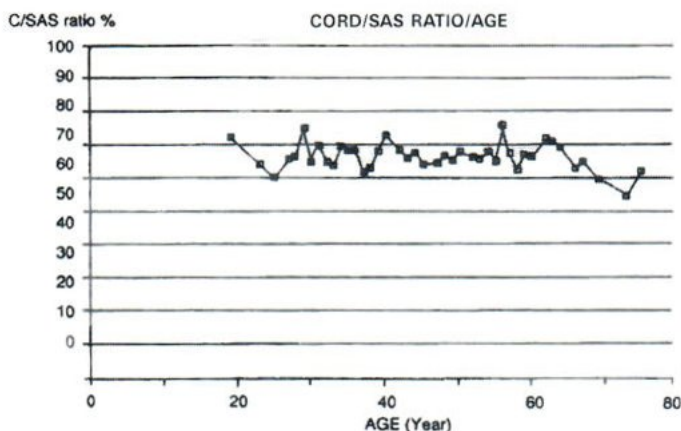


Fig. 4 Graph show relationship between age and C/SAS ratio.

C/SAS in female is 0.57 to 0.79, mean 0.68.

C/SAS as correlated with age is shown by linear graph (Fig.4) and there is no significant change on aging.



## COMPARATIVE STUDY

### CASE 1

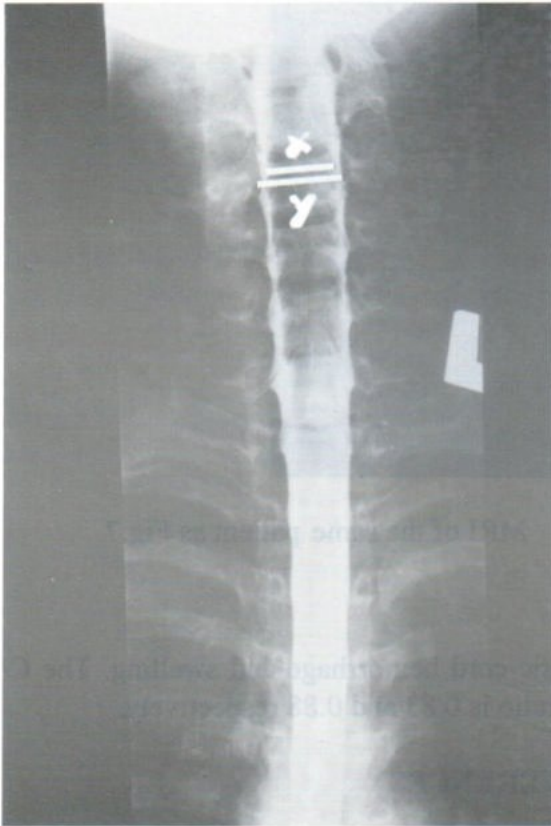A 22 years old female presented with numbness of both hands for 5 months, progressive from hand to arm.

PE : Suspension sensory loss up to C5.,

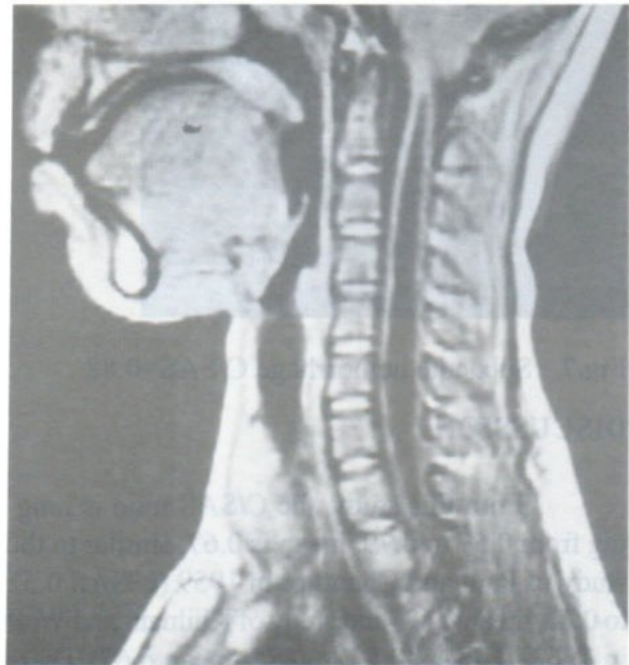
Spastic both legs.

Myelogram : Fusiform enlargement of the cervical cord with C/SAS ratio 0.83.

MRI : Syringomyelia C1 to C7 level. (Fig.5 & Fig.6)



**Fig. 5** Syringomyelia C/SAS = 0.83

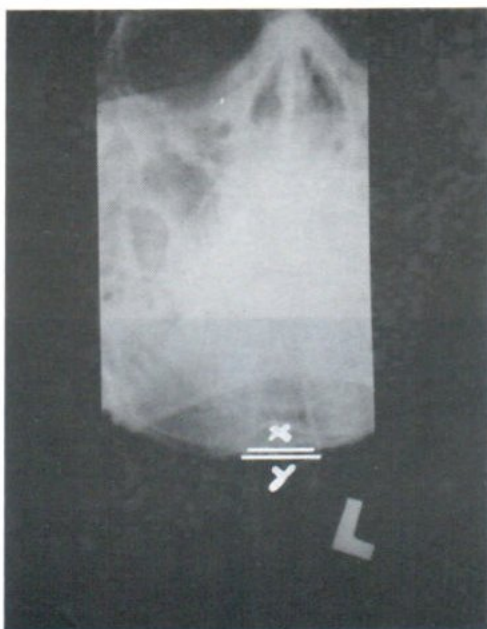


**Fig.6** MRI of the same patient as Fig.5

**CASE 2**

A 29 years old male presented with neck pain especially on extension, left extremity weakness and numbness of right side of the body, progressive for the past 2 months.

Myelogram : Focal fusiform enlargement



**Fig.7** Subacute hemorrhage C/SAS=0.88

**DISCUSSION**

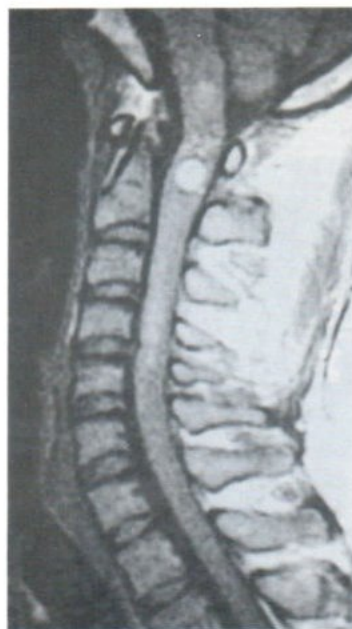From this study, the C/SAS ratio is ranging from 0.57 to 0.79, mean is 0.67, similar to the study of Paul and Chandler in 1959 (C/SAS 0.52 to 0.73, mean 0.63) and study of Khilnani and Wolf in 1963. (C/SAS 0.53 to 0.78, mean 0.67) There is no significant difference of C/SAS ratio in two genders, as well as, in aging.

The ratio of C/SAS is abnormal if it is under 0.57 or above 0.77 (mean + 2SD)

For comparative study, we have shown 2 cases of abnormal enlargement of the spinal cord. One is due to Syringomyelia and another one,

of the upper cervical cord with C/SAS ratio 0.88.

MRI : Subacute hemorrhage at upper cervical cord size about 9 mm. in diameter with mild perifocal cord edema. (Fig.7 & Fig.8)



**Fig.8** MRI of the same patient as Fig.7

intrinsic cord hemorrhage and swelling. The C/SAS ratio is 0.83 and 0.88 respectively.

**REFERENCES**

1. Paul LW, Chandler A. Myelography in expanding lesions of the cervical spinal cord. Exhibit at 45<sup>th</sup> Annual Meeting of the Radiological Society of North America, Chicago: Nov. 1959:15-20.
2. Khilnani MT, Wolf BS. Transverse diameter of cervical spinal cord on pantopaque myelography. J Neurosurg 1963; 20: 660-1.

---

**PROGNOSTIC VALUE OF THE RATIO THYROGLOBULIN  
TO I-131 UPTAKE AFTER THYROIDECTOMY BEFORE  
ABLATIVE RADIOIODINE THERAPY IN  
WELL- DIFFERENTIATED THYROID CANCER**

Sunanta CHIEWVIT, M.D.<sup>1</sup>

Wanna TRIVITAYARATANA, M.D., M.Sc. (Biostatistics)<sup>2</sup>

Busara SATAYABAN, M.Sc.<sup>1</sup> Ruentip TIPPAROJ, B.Sc.<sup>1</sup>

Vipa BOONNAMSIRI, Ph.D.<sup>1</sup>

**ABSTRACT**

Before I-131 treatment, serum Tg is not a reliable tumor marker since it can also be originated from remnant thyroid tissue or postsurgery trauma. We evaluated serum Tg and I-131, 24 hours uptake before the first I-131 treatment in 214 patients with well-differentiated thyroid cancer (74 papillary/140 follicular). The highest value of the ratio serum Tg to I-131, 24 hours uptake in tumor-free patients (Group A) was 12.81 ng/ml/%. Therefore the ratio higher than 12.81 ng/ml/% was indicative of metastasis or later recurrence. The sensitivity for lymph node metastases, distance metastases and late recurrence were 41.38%, 88.37%, 76.47%, respectively. The Tg/I-131 uptake ratio might be used as a prognostic value for well-differentiated thyroid cancer patients after thyroidectomy and before I-131 treatment.

Serum Thyroglobulin (Tg) is a suitable tumour marker for differentiated thyroid cancer after total thyroidectomy by surgery and I-131 ablation or treatment. In these cases serum Tg is a very reliable marker for the local recurrence of thyroid cancer, lymph node metastases and distance-site metastases. Unfortunately, immediately after surgical ablation, serum Tg can be of limited value and elevated serum Tg levels are particularly evident after incomplete thyroidectomy.<sup>1</sup> Surgical ablation could be expected to increase serum Tg by disruption of the thyroid structure. With remnant thyroid tissue, serum Tg could be expected to be originated from the normal remnant plus tumor masses. In remnant with no tumor burden, serum Tg would be low and directly correlated to the mass of the thyroid remnant. It

was hypothesized that the ratio of serum Tg to I-131 uptake could be used to correct Tg value for variations in the remnant tissue. The purpose of study was undertaken to evaluate the hypothesis that the ratio of serum Tg to I-131 24 hours uptake in the thyroid bed could be used during postsurgery conditions and before I-131 treatment to detect thyroid cancer (distance metastasis or late recurrence).

**MATERIALS AND METHODS**

This study was the retrospective data of 343 well-differentiated thyroid cancer patients treated with I-131 at Division of Nuclear Medicine, Siriraj Hospital since 1990- 1997. Two hundred and fourteen patients were studied (74 papil-

---

<sup>1</sup> Division of Nuclear Medicine, Department of Radiology, Faculty of Medicine, Siriraj Hospital, Mahidol University, Bangkok 10700, Thailand.

<sup>2</sup> Department of Radiological Technology, Faculty of Medical Technology, Mahidol University, Bangkok 10700, Thailand

lary 140 follicular ) with Tg and I-131 24 hours uptake in thyroid bed before I-131 therapy. One hundred and twenty nine patients were excluded because positive Tg-specific auto-antibodies or Tg and I-131 uptake were not obtained pre-radioiodine treatment. The patients were evaluated in four groups by following criteria.

- Group A** = disease-free, no local recurrence or metastases.
- Group B** = lymph node metastases
- Group C** = distant metastases with or without lymph node involvement
- Group D** = late recurrence at lymph node or distance site.

**THYROGLOBULIN MEASUREMENT**

Unfortunately, Tg could not be measured using the same technique in all patient. Serum Tg measurement before 1997 was performed by RIA technique and Serum Tg measurement since 1997 was performed by IRMA technique.

**RESULTS**

**Table 1.** Data of 214 well-differentiated thyroid cancer patients

| Patients              | Group A | Group B | Group C | Group D |
|-----------------------|---------|---------|---------|---------|
| Number                | 96      | 58      | 43      | 17      |
| Mean of age (Years)   | 42.75   | 46.72   | 51.60   | 51.63   |
| Cell type - papillary | 40      | 9       | 21      | 4       |
| - follicular          | 56      | 49      | 22      | 13      |
| Sex -male             | 12      | 23      | 12      | 5       |
| -female               | 81      | 35      | 31      | 12      |

**Table 3.** Number of patients in Group A, B, C, and D which Tg/ I-131 uptake ratio more than 12.81 ng/ml/% (positive result) and less than 12.81 ng/ml/% (negative result )

| Group of patients | Tg/ I-131 uptake ratio ≤12.81 ng/ml/% | Tg/ I-131 uptake ratio ≥ 12.81 ng/ml/% | total of patients |
|-------------------|---------------------------------------|--|-------------------|
| A                 | 96                                    | 0                                      | 96                |
| B                 | 34                                    | 24                                     | 58                |
| C                 | 5                                     | 38                                     | 43                |
| D                 | 4                                     | 13                                     | 17                |

**24 HOURS I-131 UPTAKE MEASUREMENT**

Iodine-131 uptake in the thyroid bed was measured by Gamma Spectrometer with flat field collimator after 24 hours oral administration of 10 µCi I-131

**STATISTICAL ANALYSIS**

Tg/ I-131 uptake ratio were calculated for all patients. The histogram of the ratio Tg to I-131 uptake revealed non-normal distribution of the data. Initially Mann-Whitney U test was used to test four groups of patients and the results were significant differences between all groups as describe in the result (Table 2). The use of maximum Tg/ I-131 uptake ratio in patients group A is 12.81 ng/ml/% to identify high probability of metastasis or late recurrence. We used the value of Tg/ I-131 uptake ratio more than 12.81 ng/ml/% as positive results in patients groups B, C, and D.

**Table 2.** Tg/ I-131 24 hours uptake ratio (ng/ml/% ) in patients Group A, B, C, and D

|                             | Group A | Group B | Group C | Group D |
|-----------------------------|---------|---------|---------|---------|
| No of patients              | 96      | 58      | 43      | 17      |
| Mean                        | 2.5     | 23.7    | 79.5    | 80.3    |
| Range                       | 12.8    | 394.3   | 611.6   | 737.7   |
| Maximum                     | 12.81   | 394.33  | 613.96  | 739     |
| Minimum                     | 0.02    | 0.05    | 2.39    | 1.29    |
| 25 <sup>th</sup> percentile | 0.6     | 2.8     | 15.5    | 12.7    |
| 75 <sup>th</sup> percentile | 3.5     | 23.8    | 96.3    | 75.5    |

**Table 4.** Sensitivity, Specificity, Predictive value of negative, Predictive value of positive, Accuracy of patients in Group B, C and D ( the Threshold of Tg/ I-131 uptake ratio is 12.81ng/ml/%)

|                              | Group B | Group C | Group D |
|------------------------------|---------|---------|---------|
| Sensitivity                  | 41.38%  | 88.37%  | 76.47%  |
| Specificity                  | 100%    | 100%    | 100%    |
| Predictive value of negative | 73.85%  | 86.49%  | 96%     |
| Predictive value of positive | 100%    | 100%    | 100%    |
| Accuracy                     | 77.92%  | 88.93%  | 96.46%  |

**Table 5.** The use of Tg/ I-131 uptake ratio threshold of 12.81 ng/ml/% to identify new patients from 1998 (not included in this study)

| Group of patients | Tg/ I-131 uptake ratio<br>≥ 12.81 ng/ml/%(case,%) | Tg/ I-131 uptake ratio<br>≤ 12.81 ng/ml/% (case) |
|-------------------|---|--|
| A                 | 8 (100%)  | 0 ( 0% )   |
| B                 | 2 (33.33%)  | 4 ( 66.67% )                                     |
| C                 | 0 ( 0% )  | 3 ( 100% )                                       |

## DISCUSSION

Thyroglobulin is a large homodimeric glycoprotein molecule. Three factors determine serum Tg concentration in most clinical situations: thyroid cell mass,<sup>2,3</sup> 1. physical damage to the thyroid caused by biopsy,<sup>4</sup> surgery,<sup>5</sup> hemorrhage,<sup>6</sup> radioiodine administration,<sup>7</sup> or 2. inflammation<sup>8</sup> and 3. activation of TSH-receptors by either TSH, chorionic gonadotropin (hCG)<sup>9</sup> or thyroid-stimulating antibodies (TSAb).<sup>10</sup> Tg is present in most differentiated thyroid carcinomas and some anaplastic thyroid carcinomas.<sup>11,12</sup> Among patients with thyroid carcinoma, serum Tg concentration is usually higher in those with follicular carcinoma than in those with papillary carcinoma, probably because follicular carcinoma are more advanced at the time of diagnosis.

The treatment of choice for differentiated thyroid cancer ( papillary or follicular carcinoma) is total or near total thyroidectomy. In most of this is followed by radioactive iodine treatment and thyroxine (T4) therapy. I-131 therapy has been

used for ablation of any remaining thyroid tissue and treatment of metastatic thyroid carcinoma. Serum Thyroglobulin (Tg) and I-131 whole body scintigraphy are suitable tumour markers for differentiated thyroid cancer after total thyroidectomy by surgery and I-131 ablation or treatment to identify residual tumor, metastases or late recurrence. Before the first I-131 treatment Tg is not a reliable marker since it can also be originated from remnant tissue, thyroid surgery or residual tumor. The pre-treatment total body scan with I-131 for detection of metastasis has limited value because even 5-mCi dose was sufficient to reduce the uptake of a therapeutic dose by 54%<sup>13</sup> and low dose may not be possible to detect distant metastasis while during the patient had residual thyroid tissue. The treatment dose of I-131 is dependent on status of the patient. Early detection of lymph node metastasis, distant metastasis or late recurrence before I-131 treatment are important for optimal treatment dose of I-131. The sensitivity is relatively low for lymph node metastasis (41.38%). Low

Tg/ I-131 uptake ratio can be influenced by low serum Tg level or high I-131 uptake. Patients with lymph node metastasis (Group B) had slightly high Tg level as compare with distance metastases and high I-131 uptake. However most of lymph node metastasis was detected by pathological tissue section. The sensitivity for distance metastases and late recurrence are 88.37%, 76.47%, respectively. The result of this study show that Tg/ I-131 24 hours uptake ratio might serve as a prognostic marker immediately after thyroidectomy but before radioiodine therapy to identify high risk patients such as distance metastases or late recurrence.

## CONCLUSION

Tg/ I-131 24 hours uptake ratio might be useful for evaluation of the patients status after thyroidectomy before ablative radioiodine therapy, so that the patients will receive optimal treatment doses of radioactive iodine.

## REFERENCES

1. Tourniaire J, Bernard MH, Ayzae L et al. Serum thyroglobulin assay after total unilateral lobectomy for differentiated thyroid carcinoma. *Press Med* 1990;19:1309-12.
2. Rasmussen NG, Hornnes PJ, Hegedus L, Feldt-Rasmussen U. Serum thyroglobulin during the menstrual cycle, during pregnancy, and post partum. *Acta Endocrinol* 1989;121:168-73.
3. Glinoe D, De Nayer P, Bourdoux P, et al. Regulation of maternal thyroid during pregnancy. *J Clin Endocrine Metab* 1990; 71(2):276-87.
4. Bayraktar M, Ergin M, Boyacioglu A, Demir S. A preliminary report of thyroglobulin release after fine needle aspiration biopsy of thyroid nodules. *J Int Med Res* 1990;18(3):253-5.
5. Tegler L, Erisson UB, Gillquist J, Lindvall R. Basal and thyrotropin-stimulated secretion rates of thyroglobulin from the human thyroid gland during surgery. *Thyroid* 1993; 3(3):213-7.
6. Kawamura S, Kishino B, Tajima K, Mashita K, Tarui S. Elevated serum thyroglobulin as a manifestation of acute haemorrhage into the thyroid gland. *Clin Endocrinol* 1984;20(2):213-9.
7. Van Herle AJ, Demeester-Mirkine N, Van Heuverswyn B, Dumont J. The effect of I-131 for diagnostic purposes on serum thyroglobulin (hTg) levels in subjects with thyroid disorders. *J Endocrinol Invest* 1981;4(1):107-20.
8. Madeddu G, Casu AR, Costanza C, et al. Serum thyroglobulin levels in the diagnosis and follow-up of subacute "painful" thyroiditis. *Arch Intern Med* 1985;145(2): 243-7.
9. Kraiem Z, Sadeh O, Blithe DL, Nisula BC. Human chorionic gonadotropin stimulates thyroid hormone secretion, iodide uptake, organification, and adenosine 3',5'-monophosphate formation in cultured human thyrocytes. *J Clin Endocrinol Metab* 1994; 79(2):595-9.
10. Filetti S, Belfiore a, Amir SM, et al. The role of thyroid stimulating antibodies of Graves' disease in differentiated thyroid cancer. *N Engl J Med* 1988;318(12):753-9.
11. Drall H, Schwarzrock R, Lang W, et al. Comparison of histology and immunohistochemistry with thyroglobulin serum level and radioiodine uptake in recurrences and metastases of differentiated thyroid carcinomas. *Acta Endocrinol* 1985;108(4):504-10.
12. Heldin NE, Westermark B. The molecular biology of the human anaplastic thyroid carcinoma cell. *Thyroidology* 1991;3(3): 127-31.
13. Jeevanran RK, Shah DH, Sharma SM, et al. Influence of initial large dose on subsequent uptake of therapeutic radioiodine in thyroid cancer patients. *Nucl Med Biol* 1986;13:277-279.

---

**THE ADVANTAGE OF DOUBLE PHASE <sup>99m</sup>Tc-MIBI SCINTIGRAPHY OVER DUAL-TRACER SUBTRACTION METHOD IN TERTIARY HYPERPARATHYROIDISM WITH SICK EUTHYROID SYNDROME**

**Supatporn TEPMONGKOL, M.D. Kanaungnit KINGPETCH, M.D.  
Supot BOONVISUT, M.D.**

**ABSTRACT**

Pre-operative parathyroid scintigraphy can be performed by 2 major means, dual-tracer subtraction method and double-phase <sup>99m</sup>Tc-MIBI method. Although, the sensitivities of both techniques are similar, many types of patient cannot be studied using the former one. Here is a case of tertiary hyperparathyroidism in chronic renal failure who has co-existing sick euthyroid syndrome causing no uptake of <sup>99m</sup>Tc-pertechnetate. The double-phase <sup>99m</sup>Tc-MIBI technique in this type of patient is proven to be more useful.

**Key words:** Sick euthyroid syndrome, parathyroid scintigraphy, tertiary hyperparathyroidism; chronic renal failure

**INTRODUCTION**

Tertiary hyperparathyroidism develops from secondary hyperparathyroidism in which the parathyroid glands turn to be autonomous function. Some studies have proven that preoperative localization of parathyroid glands decreased the time required for surgery and lowered the incidence of complications.<sup>1</sup> Parathyroid scintigraphy using dual-tracer <sup>99m</sup>Tc-pertechnetate/<sup>99m</sup>Tc-MIBI (methoxyisobutyl isonitrile) subtraction method has proven to be a bit more sensitive than double-phase <sup>99m</sup>Tc-MIBI imaging.<sup>2</sup> However, in patient with chronic disease, parathyroid scintigraphy using dual-tracer subtraction method will be less useful.

This paper presents a case of patient with tertiary hyperparathyroidism in chronic renal failure and the superiority of using double phase <sup>99m</sup>Tc-MIBI scintigraphy over subtraction method in this type of patient.

**CASE REPORT**

A 22 year old female patient underlying chronic renal failure for 7 years was treated by chronic ambulatory peritoneal dialysis (CAPD) for 5 years. Four months ago she had pelvic pain and was treated by oral vitamin D. She was referred

---

Division of Nuclear Medicine, Department of Radiology, Faculty of Medicine, Chulalongkorn University

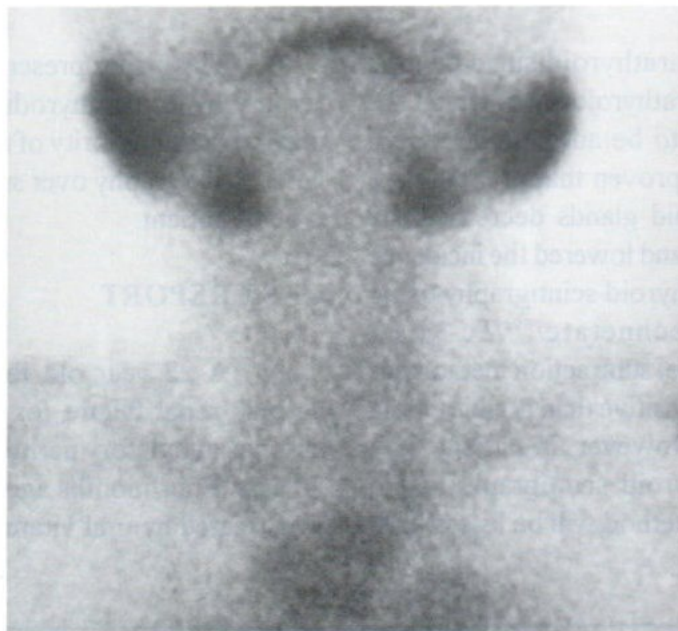
All correspondences and reprint requests should be addressed to: **Supatporn Tepmongkol, M.D.**, Division of Nuclear Medicine, Department of Radiology, Faculty of Medicine, Chulalongkorn University, King Chulalongkorn Memorial Hospital, Rama IV road, Bangkok 10330, Thailand. Tel (66 2)2564283-4, Fax (66 2)2564162, Email: [supatporn@hotmail.com](mailto:supatporn@hotmail.com)

for parathyroidectomy. On physical examination, the patient looked chronically ill without other abnormal findings. Laboratory evaluation for PTH level is 1400 pg/ml (normal= 10-60), alkaline phosphatase = 3224 u/L (normal=98-279), serum calcium = 11.3 mg/dl (normal=9-10.5), serum phosphate = 7.7 mg/dl (normal=3-4.5). Ultrasonography of neck showed enlargement of bilateral superior parathyroid glands, size 0.95x1.44x0.48 cm on the right and 0.80x1.26x0.52 cm on the left, suggestive of adenomas. Parathyroid scintigraphy was then performed to confirm ultrasound diagnosis and to seek for other abnormal parathyroid glands. Two techniques were employed sequentially, the dual-tracer  $^{99m}\text{Tc}$  pertechnetate/ $^{99m}\text{Tc}$  MIBI subtraction technique and double phase  $^{99m}\text{Tc}$  MIBI technique. In the first technique (Fig. 1), the thyroid failed to take up  $^{99m}\text{Tc}$ -pertechnetate.  $^{99m}\text{Tc}$  MIBI was then injected to do the double phase technique (Fig. 2). The first phase obtained immediately after injection of  $^{99m}\text{Tc}$ -MIBI showed thyroid gland uptake with 2 foci of increased uptake in upper pole of both lobes and 2 other foci in

lower neck area outside the thyroid gland. The late phase at 2 hr showed washout of radioactivity from the thyroid gland but remaining radioactivity in all 4 abnormal foci seen in early phase. This finding is suggestive of four parathyroid glands enlargement. There was neither positive history of high iodide intake or drugs that may cause poor  $^{99m}\text{Tc}$ -pertechnetate uptake nor positive physical examination of thyroid hypofunction or thyroiditis. The blood test for T3 was 77 ng/dl (normal= 80-180 ng/dl), T4=4 mg/dl (normal=6-12 mg/dl), TSH = 0.2 IU/ml (normal=0.5-4 IU/ml).

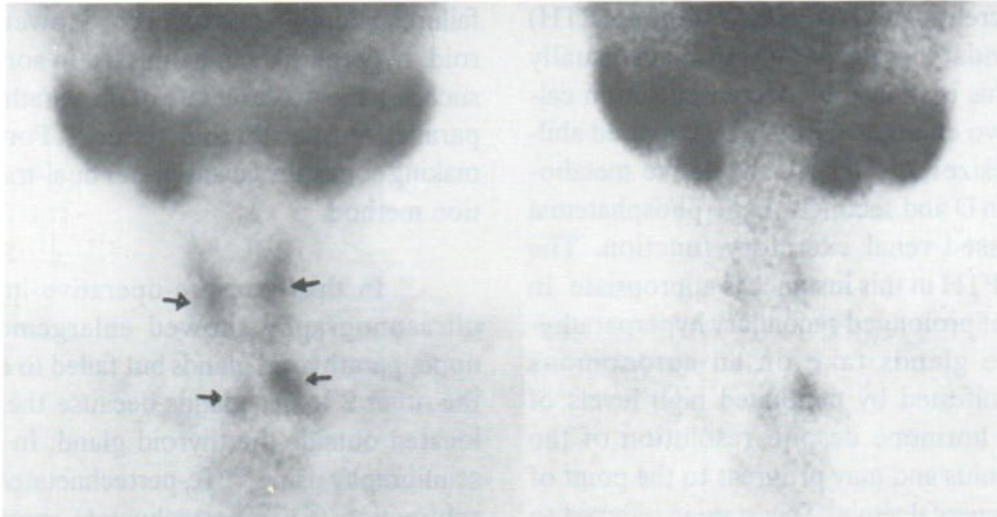
At surgery, enlargement of 4 parathyroid glands were found and 3 ½ glands were resected. The histopathologic examination reveals nodular hyperplasia of all parathyroid glands.

Four months later, repeat thyroid scan with  $^{99m}\text{Tc}$ -pertechnetate (Fig. 3) showed improvement of uptake in both thyroidal lobes compared to the first study. The blood test for T3=74 ng/dl, T4=8 mg/dl, TSH=9 IU/ml, FT4=0.7 ng/dl (normal=0.65-2)

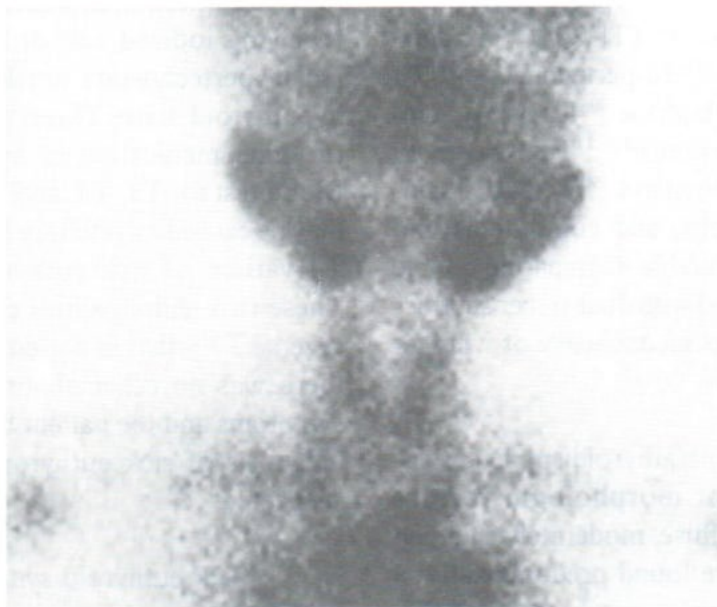

**Fig.1** In the dual-tracer  $^{99m}\text{Tc}$ -pertechnetate/ $^{99m}\text{Tc}$ -MIBI subtraction technique,  $^{99m}\text{Tc}$ -pertechnetate scintigraphy which was performed first showed no uptake in the thyroid gland. This caused failure of the subtraction technique.





**Fig.2** Double-phase  $^{99m}\text{Tc}$ -MIBI scintigraphy: The immediate post injection scintigraphy (left) showed uptake in both the thyroid gland and parathyroid glands (arrows). The delayed 2-hour after injection scintigraphy (right) showed washout of radioactivity from the thyroid with remaining activity in 4 parathyroid glands.



**Fig.3**  $^{99m}\text{Tc}$ -pertechnetate thyroid scintigraphy 4 months later showed faint but improved uptake in both lobes of thyroid gland.

## DISCUSSION

In patients with chronic renal failure, increased secretion of parathyroid hormone (PTH) called secondary hyperparathyroidism usually develops. This is caused by decreased serum calcium from two etiologies. Firstly by impaired ability to synthesize  $1,25(\text{OH})_2\text{D}$ , the active metabolite of vitamin D and secondly, hyperphosphatemia from decreased renal excretory function. The response of PTH in this instance is appropriate. In some cases of prolonged secondary hyperparathyroidism, the glands take on an autonomous function manifested by continued high levels of parathyroid hormone despite resolution of the original stimulus and may progress to the point of producing hypercalcemia. This state is referred to as tertiary hyperparathyroidism.<sup>3,4</sup>

Before surgery, localization of parathyroid glands can be done by many means. Comparison have been made among ultrasonography, computed tomography, dual-tracer ( $\text{Tl-201}/^{99\text{m}}\text{Tc}$ -pertechnetate,  $^{99\text{m}}\text{Tc}$ -MIBI/ $^{99\text{m}}\text{Tc}$ -pertechnetate,  $^{123}\text{I}$  /  $^{99\text{m}}\text{Tc}$  MIBI), and double-phase  $^{99\text{m}}\text{Tc}$ -MIBI scintigraphy with varying results.<sup>3,5,6,7</sup> The sensitivity and specificity of double phase  $^{99\text{m}}\text{Tc}$ -MIBI scintigraphy, ultrasonography, and computed tomography seem to be comparable. Comparing double phase  $^{99\text{m}}\text{Tc}$ -MIBI method with dual-tracer subtraction method, the result is inconclusive of whether which modality is better.

In tertiary hyperparathyroidism, hyperplasia is the predominant morphologic feature accounting for 95%.<sup>8</sup> Diffuse, moderately enlarged hyperplastic glands were found predominantly in patients with renal transplants, whereas nodular, markedly enlarged hyperplastic parathyroids were observed more frequently in patients treated by dialysis as seen in this case. Four gland parathyroid enlargement is a frequent finding.<sup>9</sup>  $^{99\text{m}}\text{Tc}$ -MIBI, which use different washout rate of thyroid and parathyroid, is able to identify more than 80%

of hyperplastic parathyroid glands in renal failure patients in one report<sup>10</sup>. However, parathyroid hyperplasia can be missed in some instances such as if the washout rate of the parathyroid glands parallel normal thyroid tissue.<sup>11</sup> For this reason making some physicians prefer dual-tracer subtraction method.

In this case pre-operative imaging with ultrasonography showed enlargement of both upper parathyroid glands but failed to demonstrate the other 2 lower glands because the lower ones located outside the thyroid gland. In parathyroid scintigraphy using  $^{99\text{m}}\text{Tc}$ -pertechnetate/ $^{99\text{m}}\text{Tc}$ -MIBI subtraction ( $^{99\text{m}}\text{Tc}$ -pertechnetate should be taken up by thyroid and  $^{99\text{m}}\text{Tc}$ -MIBI should be taken up by both thyroid and parathyroid), thyroid did not take up  $^{99\text{m}}\text{Tc}$ -pertechnetate but took up  $^{99\text{m}}\text{Tc}$ -MIBI making it unable to perform subtraction. This raises the question of whether the patient had been receiving iodized salt or other medication that inhibit pertechnetate uptake, or the patient is in hypothyroid state. There was no positive history of either medication or hypothyroid symptoms. Blood test for T3, T4, and TSH were all low. This may be caused by pituitary hypothyroidism or low-T4 variant of sick euthyroid syndrome (SES). These two abnormalities can be differentiated by reverse T3<sup>12</sup> that is not currently available. Since there was no other abnormal pituitary signs or symptoms and the patient has chronic disease, the diagnosis of sick euthyroid syndrome was then suspected.

Sick euthyroid syndrome is an abnormality that is caused by severe illness which induce changes in thyroid hormone economy. Abnormalities in SES include alterations in the peripheral transport and metabolism of thyroid hormones; the regulation of TSH secretion; and in some cases changes in thyroid function itself. These lead to changes in the concentrations of the circulating

thyroid hormones<sup>12</sup>. SES in this patient was proven later by repeating thyroid scan with <sup>99m</sup>Tc-pertechnetate and thyroid hormone test when the patient condition improved. The repeat scan reveals improvement of uptake of <sup>99m</sup>Tc-pertechnetate and the blood test also improved.

The other question is why thyroid in sick euthyroid patient doesn't take up <sup>99m</sup>Tc-pertechnetate but does take up <sup>99m</sup>Tc-MIBI. This may be explained by the mechanism of uptake. Pertechnetate is trapped by the thyroid in the same manner as iodide but is not organified<sup>13</sup>. Since trapping is stimulated by TSH, lack of TSH can cause impair in <sup>99m</sup>Tc-pertechnetate uptake. Whereas for <sup>99m</sup>Tc-MIBI the uptake is neither mediated by iodide trapping mechanism<sup>14</sup> nor related to TSH control<sup>15</sup>. In cultured mouse fibroblasts, <sup>99m</sup>Tc-MIBI uptake and retention were determined by both mitochondrial content and plasma membrane potentials.<sup>16</sup> This can be concluded that the hyperparathyroid patients in whom chronic disease is the problem such as in chronic renal failure, the technique using double-phase <sup>99m</sup>Tc-MIBI scintigraphy might be better than dual-tracer subtraction methods.

## REFERENCES

1. Lundgren E, Gillott A, Weiseman J, Beck J. The role of preoperative localization in primary hyperparathyroidism. *Am Surg* 1995;61:393-6.
2. Chen CC, Holder LE, Scovill WA, Tehan AM, Gann DS. Comparison of parathyroid imaging with technetium-99m pertechnetate/sestamibi subtraction, double-phase technetium-99m-sestamibi and technetium-99m-sestamibi SPECT. *J Nucl Med* 1997;38(6):843-9.
3. John T, Potts JR. Diseases of the parathyroid gland and other hyper- and hypocalcemic disorder. In: Wilson JD, Braunwald E, Isselbacher KJ, et al, eds. Principles of internal medicine. 12<sup>th</sup> ed. New York: McGraw-Hil, 1991: 1902-21.
4. Mallette LE. The functional and pathologic spectrum of parathyroid abnormalities in hyperparathyroidism. In: Bilezikian JP, Marcus R, Levine MA, eds. The parathyroids: Basic and clinical concepts. 1st ed. New York: Raven Press, 1994: 423-55.
5. Mazzeo S, Caramella D, Lencioni R, et al. Comparison among sonography, double-tracer subtraction scintigraphy, and double-phase scintigraphy in the detection of parathyroid lesions. *Am J Roentgenol* 1996; 166(6):1465-70.
6. Neumann DR, Esselstyn CB Jr, Go RT, et al. Comparison of double-phase <sup>99m</sup>Tc-sestamibi with <sup>123I</sup>-<sup>99m</sup>Tc-sestamibi subtraction SPECT in hyperparathyroidism. *Am J Roentgenol* 1997;169(6):1671-4.
7. Krubsack AJ, Wilson SD, Lawson TL, et al. Prospective comparison of radionuclide, computed tomographic, sonographic, and magnetic resonance localization of parathyroid tumors. *Surgery* 1989; 106(4):639-46.
8. Krause MW, Hedenger CE. Pathologic study of parathyroid glands in tertiary hyperparathyroidism. *Hum Pathol* 1985; 16(8):772-84.
9. Kilgo MS, Pirsch JD, Warner TF, Starling JR. Tertiary hyperparathyroidism after renal transplantation: surgical strategy. *Surgery* 1998; 124(4):677-83.
10. Chesser AM, Carroll MC, Lightowler C, et al. Technetium-99m methoxy isobutyl isonitrile (MIBI) imaging of the parathyroid glands in patients with renal failure. *Nephrol Dial Transplant* 1997;12(1):97-100.

11. Chen EM, Mishkin FS. Parathyroid hyperplasia may be missed by double-phase Tc-99m sestamibi scintigraphy alone. *Clin Nucl Med* 1997;22(4):222-6.
12. Wartofsky L, Ingbar SH. Disease of the thyroid. In: Wilson JD, Braunwald E, Isselbacher KJ, et al, eds. *Principles of internal medicine*. 12<sup>th</sup> ed. New York: McGraw-Hil, 1991:1692-1712.
13. Mettler FA Jr., Guiberteau MJ. Thyroid and parathyroid. In: *Essentials of Nuclear Medicine* (ed 3). Philadelphia, W.B. Saunders, 1991:75-94.
14. Civelek AC, Durski K, Shafique I, et al. Failure of perchlorate to inhibit Tc-99m isonitrile binding by the thyroid during myocardial perfusion studies. *Clin Nucl Med* 1989;16(5):358-61.
15. Vattimo A, Bertelli P, Burrioni L. Effective visualization of suppressed thyroid tissue by means of baseline 99mTc-methoxyisobutyl isonitrile in comparison with 99mTc-pertechnetate scintigraphy after TSH stimulation. *J Nucl Biol Med* 1992;36(4):315-8.
16. Chiu ML, Kronauge JF, Piwnica-Worms D. Effect of mitochondrial and plasma membrane potentials on accumulation of hexakis(2-methoxyisobutylisonitrile) technetium (I) in cultured mouse fibroblasts. *J Nucl Med* 1990;31(10):1646-53.

---

## OPTIMUM FIELD SEPARATION IN ADJACENT FIELDS OF ELECTRON BEAM THERAPY

TUNTIPUMIAMORN L.<sup>1</sup>, M.Sc POLWATSATIEN V.<sup>1</sup>, B.Sc  
SUTUD NA AYUTHAYA B.<sup>2</sup>, B.Sc SAINET S.<sup>2</sup>, B.Sc

### ABSTRACT

Due to the scattering properties of electrons, the problem of positioning of multiple electron fields is more complicated than in the case of photon beam. In this study we investigated the dose uniformity at the junction region of adjacent electron fields in different field separations for several cone sizes and beam energies with a particular closed-sided applicator by using film dosimetry. Optimum field separation found in this study depends on applicator cone size and beam energy combination.

### INTRODUCTION

Treatment with high energy electron beam plays an important role for superficial lesion because of its advantage in sparing normal critical structures. Since there is a limitation in applicator size, the treatment of extended areas of electron requires the use of two or more adjacent fields. Unlike photon, problem of field positioning in electron cannot be solved by empirical technique or using simple geometric divergence correction because the scattering characteristic of electron results in constriction of the higher value isodoses and bulging out in the lower value isodoses.<sup>1</sup> Therefore, abutting of two electron fields may lead to significant dose inhomogeneities along the junctional region. In this study, we proposed to investigate the dose uniformity in the junction region of electron adjacent fields in different field separations, several applicator sizes and beam energies in the Mitsubishi ML-15 MIII Linear Accelerator to obtain the optimum field separation for being used in our clinical practice.

### MATERIAL & METHOD

Film dosimetry was chosen to study the relative dose distribution of electron beam by its advantage in having a high spatial resolution and short measurement time. Type of film using were Kodak ready pack X-Omat TL that the sensitometric curve was already obtained prior to the measurement procedure. Measurement was performed by the film being sandwiched in a polystyrene phantom with the film plane paralleled to the beam central axis. Then the experimental data were taken for various closed-sided electron applicators (10 cm x 10 cm, 10 cm x 18 cm, 14cm x 14 cm, and 18cm x 10 cm) with the 8, 10, 12 and 15 MeV electron in different field separations, 1.0 cm, 0.5 cm, 0.25 cm overlaps and 0.0 cm, 0.25 cm, 0.5 cm gaps. The field separation here was specified to the edge of the light field. After processing, all the films were read by X-Rite 301 Black and White Densitometer having an aperture diameter of 1 mm.

Data was analyzed using parameter "Depth Dose Ratio", DDR, as suggested by

---

<sup>1</sup> Division of Radiation Oncology, Department of Radiology, Faculty of Medicine, Siriraj Hospital, Mahidol University, Bangkok-10700, THAILAND

<sup>2</sup> Department of Radiological Technology, Faculty of Medical Technology, Mahidol University, Bangkok-10700, THAILAND

Bagne.<sup>2</sup> The DDR is defined as the ratio of dose at the depth on mid separation axis to the average dose at the same depth on the central axis of both fields. Thus,

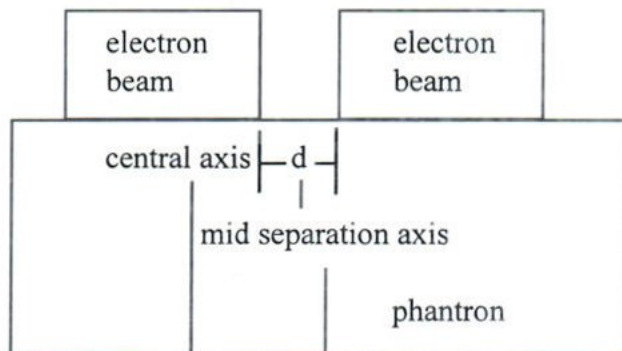
$$DDR = \frac{\text{Percentage Depth Dose at depth } d \text{ at the mid separation axis}}{\text{Average percentage depth dose at depth } d \text{ on the central axis of both fields}}$$

Ideally, if the dose in the junction region is uniform, the DDR should equal to 1. In practice, we used a criterion in determining the optimum field separation by examining the DDR value into two regions. First is the depth between 0.5 cm below surface and the depth of dose maximum for shallow lesion, and second the depth

between dose of maximum ( $D_{max}$ ) and the 80<sup>th</sup> percentile of dose ( $R_{80}$ ) for deep tumor and required that the DDR be within 0.9 and 1.1

**RESULTS**

The DDR parameter for electron beam abutted fields at the standard SSD (100 cm) as a function of depth was determined for electron beam energies 8,10,12 and 15 MeV using 10 cm x 10 cm, 10 cm x 18 cm, 14 cm x 14 cm, and 18 cm x 10 cm fields. Results are presented in Figure 2- Figure 5



**Fig 1.** Geometry of experimental setting-up, d= field separation

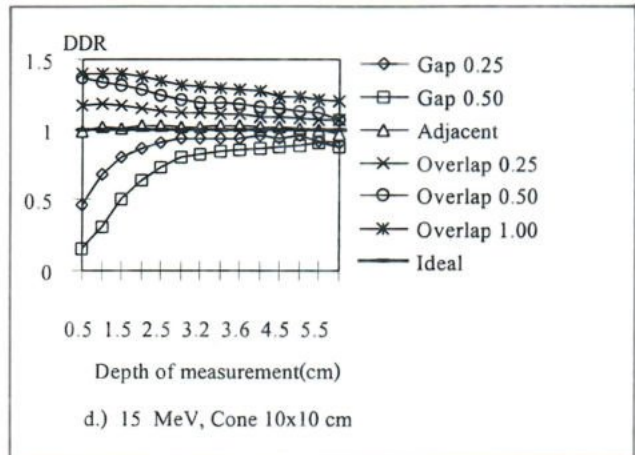
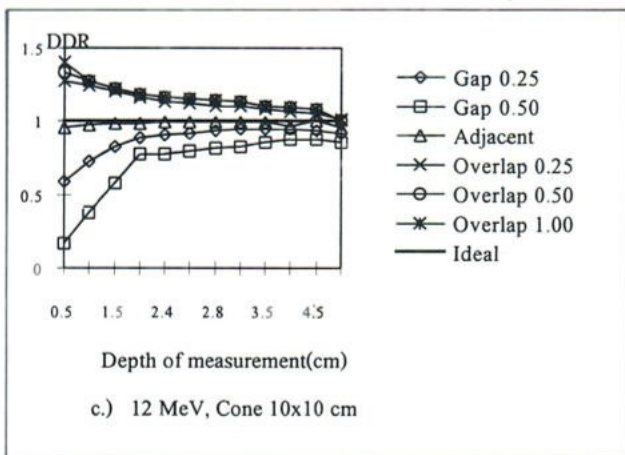
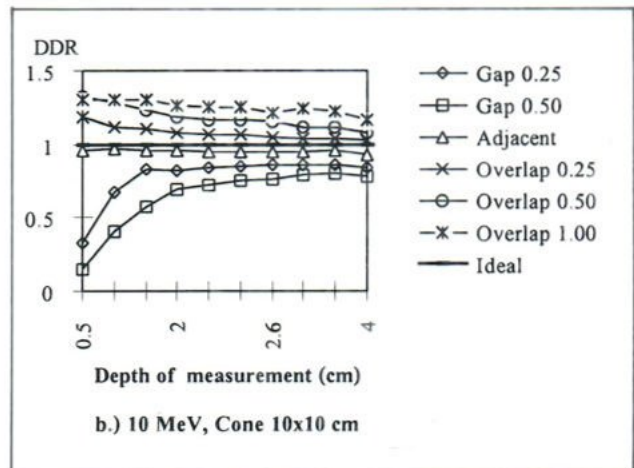
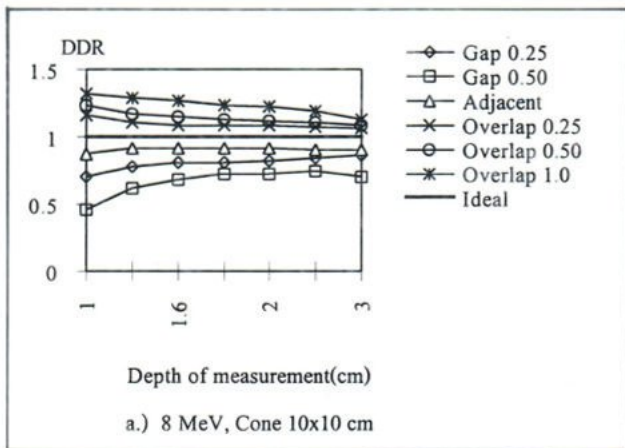
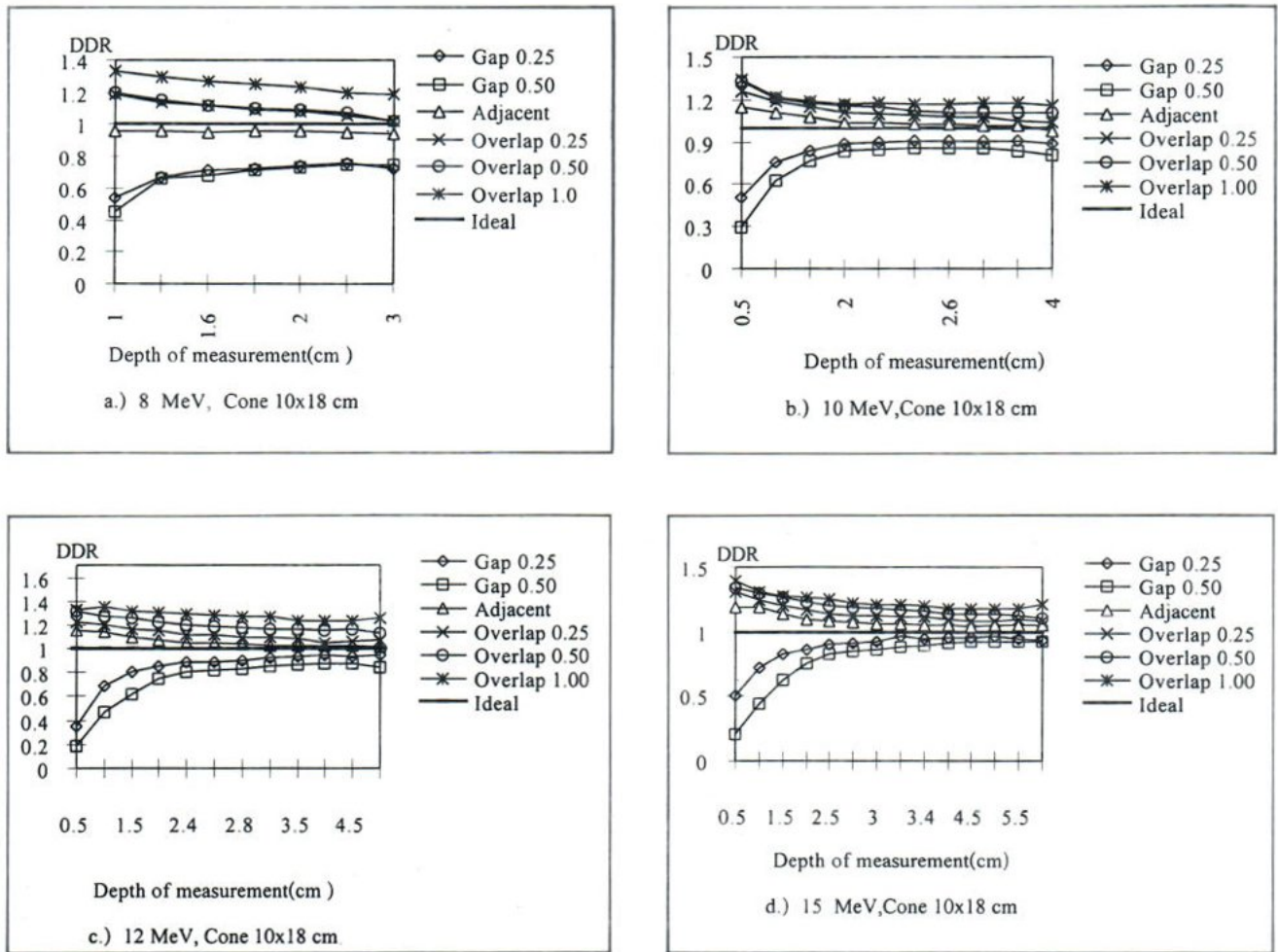
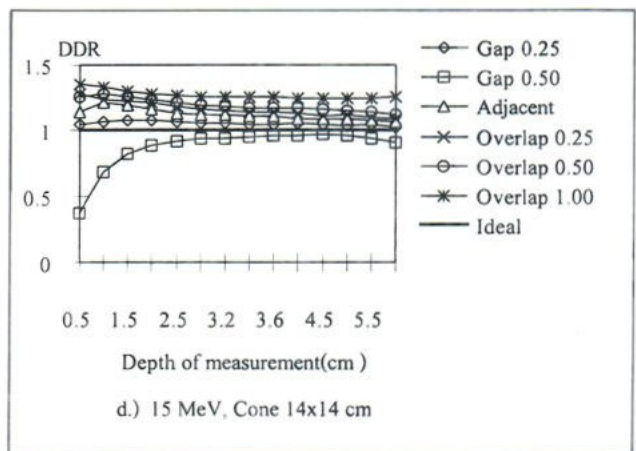
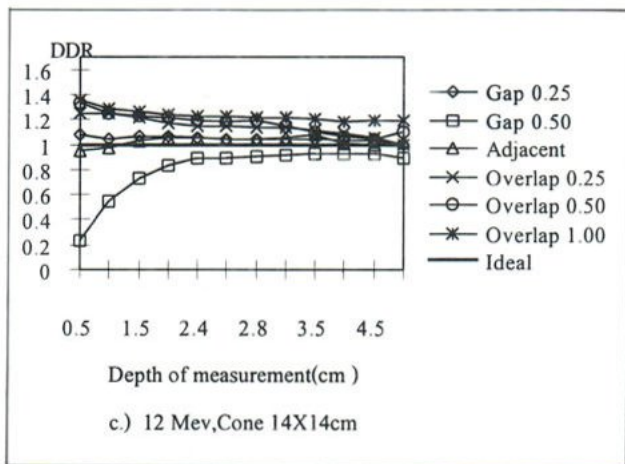
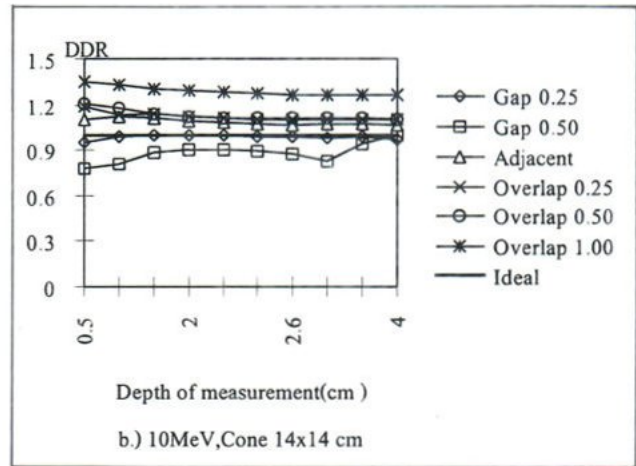
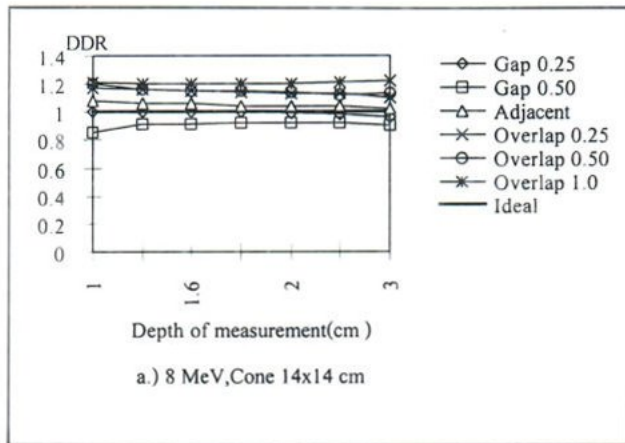


Fig. 2 Depth dose ratio (DDR) as a function of depth for 10cmx10cm applicator, 100 cm SSD, with a 1.0 cm , 0.5 cm, 0.25 cm overlaps and 0.0 cm,0.25 cm,0.5 cm gaps

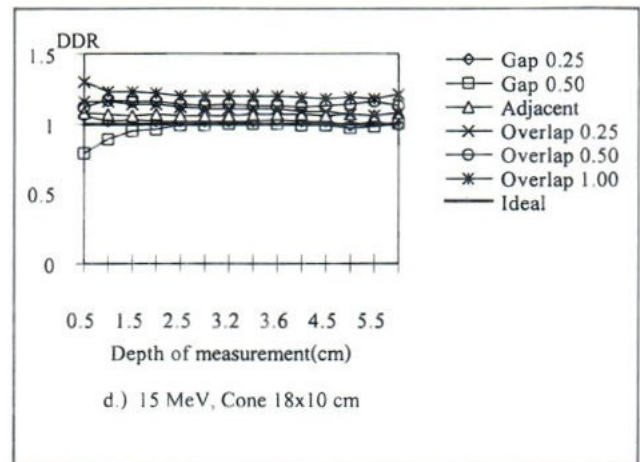
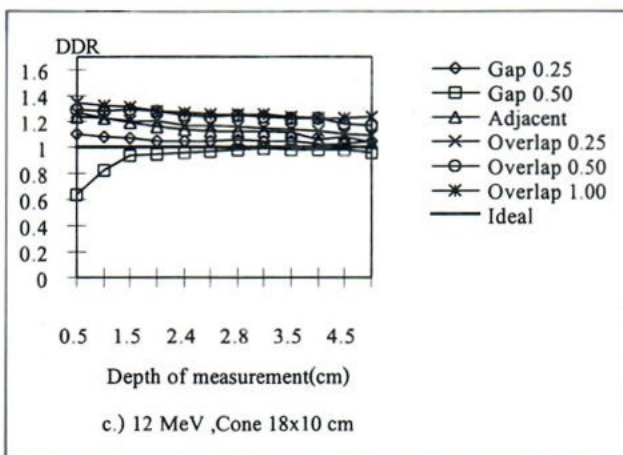
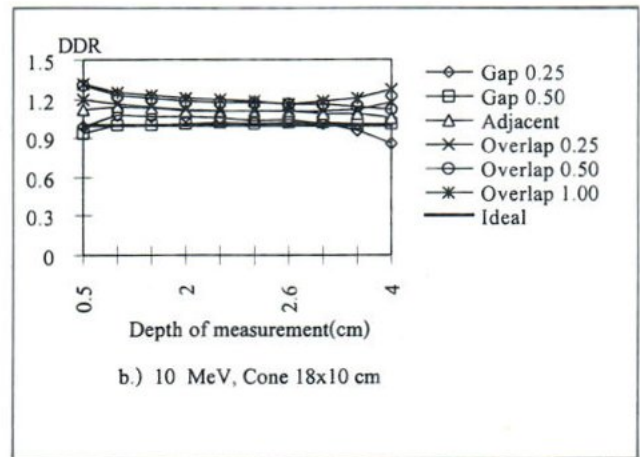
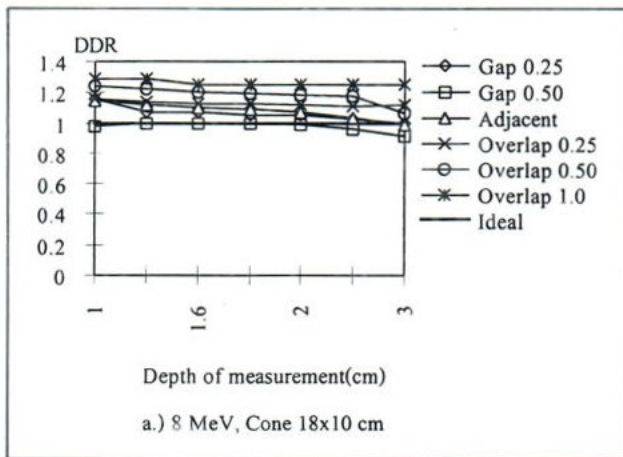


**Fig. 3** Depth dose ratio (DDR) as a function of depth for 10 cm x 18 cm applicator, 100 cm SSD, with a 1.0 cm, 0.5 cm, 0.25 cm overlaps and 0.0 cm, 0.25 cm, 0.5 cm gaps





**Fig. 4** Depth dose ratio (DDR) as a function of depth for 14 cm x 14 cm applicator, 100 cm SSD, with a 1.0 cm, 0.5 cm, 0.25 cm overlaps and 0.0 cm, 0.25 cm, 0.5 cm gaps



**Fig. 5** Depth dose ratio (DDR) as a function of depth for 18 cm x 10 cm applicator, 100 cm SSD, with a 1.0 cm , 0.5 cm, 0.25 cm overlaps and 0.0 cm, 0.25 cm, 0.5 cm gaps

From the above data, surface field separations that provided DDR value of 0.9 to 1.1 in the region between depth of dose maximum ( $D_{max}$ )

and the depth of 80<sup>th</sup> percentile of dose ( $R_{80}$ ) for the four energies and field sizes are shown in Table 1.

**Table. 1** Optimum separation for abutted electron fields at standard SSD 100 cm for the depth between  $D_{max}$  -  $R_{80}$

| Energy (MeV) | Field Size (cm)                    |                                    |                     |                     |
|--------------|------------------------------------|------------------------------------|---------------------|---------------------|
|              | 10X10                              | 10X18                              | 14X14               | 18X10               |
| 8            | 0.0 cm gap<br>0.25 cm overlap      | 0.0 cm gap<br>0.25 cm overlap      | 0.0,0.25,0.5 cm gap | 0.0,0.25,0.5 cm gap |
| 10           | 0.0 cm gap<br>0.25 cm overlap      | 0.0,0.25 cm gap<br>0.25 cm overlap | 0.0,0.25,0.5 cm gap | 0.0,0.25,0.5 cm gap |
| 12           | 0.0,0.25 cm gap<br>0.25 cm overlap | 0.0,0.25 cm gap<br>0.25 cm overlap | 0.0,0.25,0.5 cm gap | 0.0,0.25,0.5 cm gap |
| 15           | 0.0,0.25 cm gap<br>0.25 cm overlap | 0.0,0.25 cm gap<br>0.25 cm overlap | 0.0,0.25,0.5 cm gap | 0.0,0.25,0.5 cm gap |

In some clinical situations if the shallow tissues are at risk, these data may not be clinically acceptable. Therefore, optimum separation of

abutted electron fields in shallow depth region (depth 0.5 cm below surface to  $D_{max}$ ) are also presented in Table. 2

**Table. 2** Optimum separation for abutted electron field in depth between 0.5 cm- $D_{max}$

| Energy (MeV) | Field Size (cm) |            |             |             |
|--------------|-----------------|------------|-------------|-------------|
|              | 10x10           | 10x18      | 14x14       | 18x10       |
| 8            | *               | 0.0 cm gap | 0.25 cm gap | 0.5 cm gap  |
| 10           | 0.0 cm gap      | *          | 0.25 cm gap | 0.5 cm gap  |
| 12           | 0.0 cm gap      | *          | 0.25 cm gap | 0.25 cm gap |
| 15           | 0.0 cm gap      | *          | 0.25 cm gap | 0.25 cm gap |

- \* = No gap gave DDR between 0.9 and 1.1 throughout the region from depth 0.5 cm below surface to depth of dose maximum

## DISCUSSION AND CONCLUSION

Several techniques have been proposed for matching electron adjacent fields in order to obtain an acceptable dose distribution in the junction region.<sup>3-7</sup> Among them, the simplest technique is to optimize the skin gap between the two electron beam edges. The dose uniformity along the junction region produced by gapping and overlapping of electron fields can be simply evaluated using the parameter DDR. One shortcoming of the DDR is that it provided only the doses along the junction region that perpendicular to the phantom surface, but not the specification of the volume of the high or low dose region caused by the abutments. However, because of its simplicity make it the most suitable technique in obtaining the data.

It clearly showed from the study that the surface field separation strongly influenced on the dose uniformity in the junction region of all energies studied and could be seen more prominently in the region of shallow depth and small applicator size. Overlapping electron fields by only 0.25 cm produced hot spots of 110-130% of the dose at the field center while 0.25 cm gapping caused underdose region (30-94%). Deviation from the optimum value may result in the serious high and low dose areas in the junction region.

In contrast, the dose uniformity in depth between  $D_{max}$  to  $R_{80}$  was not affected by the field separation as strongly as the region of shallow depth was. Optimum separations found in this depth of treatment, in large applicator size of all energies, could be either 0.0 cm, 0.25 cm or 0.5 cm gaps. While in smaller field width (10x10 cm, 10x18 cm) at each energy, optimum separations were 0.0 cm, 0.25cm gaps and 0.25 cm overlap. Except only the 8 MeV electron in small field that gapping 0.25 cm could produce low dose region. Choosing which optimum separation being used in clinical practice should be based on an emphasis of reducing any setting-up error.

As the results presented, it could be pointed out that the optimum separation in electron adjacent fields could not be calculated from the basic knowledge of beam divergence as in the case of photon. And with the fact that, the beam characteristics of the electron strongly depend on how the field is flattened and the collimator system used, therefore no single standard field separation could be used universally. Optimum field separations found in this study depend on field width, beam energy and depth of treatment.

## REFERENCES

1. Khan FM. Electron beam therapy. In: The physics of radiotherapy. 2<sup>nd</sup> ed. Williams & Wilkins: Baltimore, USA, 1994:361-365
2. Bagne F. Adjacent field of high energy x-rays and electrons: Flat surface. *Phys. Med. Biol*, 1978;23(6):1186-1191
3. Able CM, Mills MD, McNeese MD, Hongstrom KR. Evaluation of a total scalp electron irradiation. *Int J Radiat Oncol Biol Phys*, 1991;21:1063-1072
4. Kalend AM, Zwicker RD, Wu A, Sternick ES. A beam - edge modifier for abutting electron fields. *Med Phys.*, 1985;12:793-798
5. Kurup RG, Wang S, Glasglow GP. Field matching of electron beams using plastic wedge penumbra generators. *Phys. Med. Biol*, 1992;37:145-153
6. Zavgorodni SF, Beckham WA, Roos DE. A method for producing uniform dose distribution in the junction regions of large hinge angle electron fields. *Int J Rad Oncol Biol Phys*, 1996;35(4):765-770
7. Harms WB, Purdy JA. Abutment of high energy electron field. *Int J Rad Oncol Biol Phys*, 1991;20(4):853-858

**Message from**  
**Professor Dr. Kawee Tungsubutra**  
**Editor-in-Chief, The Asean Journal of Radiology**

---

Dear Friends ,

This is the 2nd Number of Vol V of the Asean Journal of Radiology. There is only another one, the Number III of Vol V to reach the goal of 5 years of regular publication of the AAR Journal of Radiology. Unfortunately I had the by-passed operation for my heart in July 1998. My health is a bit run down. My term of the presidency of the Royal College of Radiologists of Thailand will come to an end in April 1999. Some body has to take over the position. This Vol V Number II will be the last issue that I will produce as the Editor-in-Chief. There will be another 8 months for the next Editor-in-Chief to produce and publish the Vol V Number III to achieve the regularity for publication of a Medical Journal within a period of 5 years. I hope the new Editor-in-Chief can continue to publish this AAR journal to be considered for the acceptance to be included in the Index Medicus.

I would like to take this opportunity to bid farewell to all my friends both in Thailand and in the Asean Countries who had recieved these journals. Good-bye and Good luck !!



**Kawee Tungsubutra**  
**May - August 1999.**

1. The AAR Journal of Radiology publishes the papers on Radiological Sciences, such as research work, review articles, case reports, innovations in Medical Sciences related to all branches of Radiology, and letters to the editor. The aforementioned materials can be written in English only.

2. The authors have to submit 2 copies of the manuscript and a diskette: **to Prof. Dr. Kawee Tungsubutra**, 318 Kaweevej Hospital, Taksin Road, Dhonburi, Bangkok 10600, Thailand. **or to the Associate Editors** at the Radiological Society of Malaysia, Indonesia, Philippines, Singapore and Brunei. The names and addresses of the Associate Editors in each country were published in the front page of this Journal.

3. The original copy to be submitted must be typed in a double space on one side of the page of 8.1/2"x 11.1/2" paper.

4. The format of the article must include :

- a. Title page and address of the author (s)
- b. Abstract
- c. Introduction (Background)
- d. Material and Method
- e. Results and discussion (Tables and Illustrations)
- f. Acknowledgement (if any)
- g. References (Follow the Vancouver style developed by ICMJE)

5. We will provide 20 copies of reprints for the author (s) who submit (s) an article for publication in the AAR Journal.

6. The illustrations and tables must be clearly prepared with legends in English as they are the art works to be reproduced.

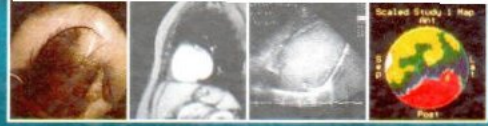
7. The authors are responsible for the contents of the article as to its facts and findings.

8. Ethics.

Paper reporting studies which might be interpreted as human experimentation (e.g. controlled trials) should conform to the standards of the Declaration of Helsinki (see British Medical Journal 1964:2:177) and should indicate that, approval that such studies may proceed, has been granted by the local or hospital Ethics Committee.

When reporting experiments on animals indicate whether the institution's or the National Research Council's guide for, or any national law on, the care and use of laboratory animals was followed.

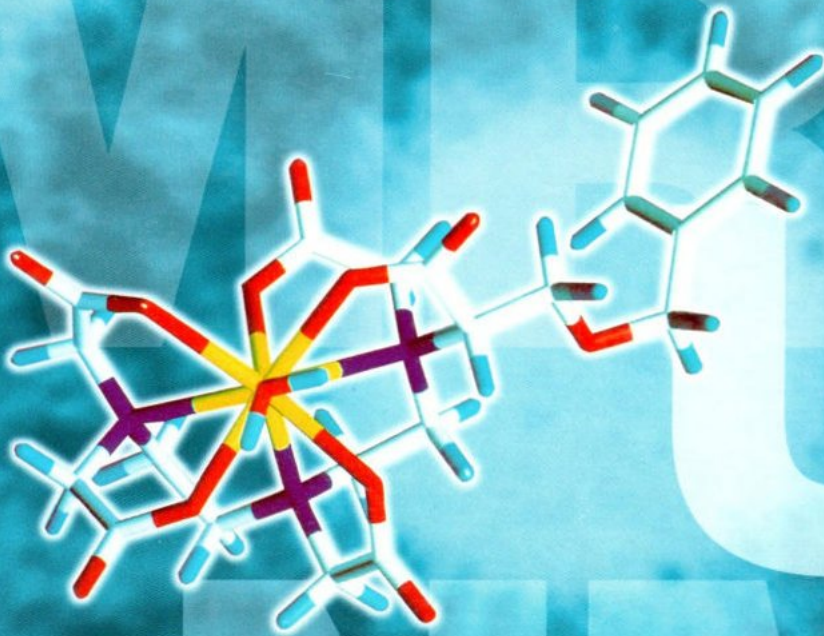




Keeping an eye on imaging

# X-ray

Magnetic  
Resonance  
Imaging



Ultrasound

Nuclear  
Medicine



BRACCO IMAGING

Harmony in contrast

