

ASEAN Movement in Radiology

Tuberculosis: Important lessons from AOCR 2023, Bangkok, Thailand

Mini Pakkal, M.D.⁽¹⁾

Bushra Johari, M.D.⁽²⁾

Jin Mo Goo, M.D., Ph.D.⁽³⁾

Ki Yeol Lee, M.D., Ph.D.⁽⁴⁾

Kushaljit Singh Sodhi, M.D.⁽⁵⁾

Murali Krishna, M.D.⁽⁶⁾

Wiwatana Tanomkiat, M.D.⁽⁷⁾

From ⁽¹⁾ University of Toronto, Department of Medical Imaging, Toronto General Hospital, Toronto, Canada,

⁽²⁾ Department of Radiology, Faculty of Medicine, Universiti Teknologi MARA, Sungai Buloh, Malaysia,

⁽³⁾ Department of Radiology, Seoul National University Hospital, Seoul, Korea,

⁽⁴⁾ Department of Radiology, Korea University Ansan Hospital, Asan, Korea,

⁽⁵⁾ Department of Radiodiagnosis and Imaging, Postgraduate Institute of Medical Education and Research, Chandigarh, India,

⁽⁶⁾ Department of Radiology and Imaging Sciences, Fortis Hospitals, Vadapalani, Chennai, India,

⁽⁷⁾ Department of Radiology, Faculty of Medicine, Prince of Songkla University, Hat-Yai, Songkla, Thailand.

Address correspondence to W.T.(email: twiwadha@hotmail.com)

Received 12 August 2023 ; accepted 12 August 2023
doi:10.46475/aseanjr.v24i2.871

Abstract

The Asian Symposia at the AOCR 2023 discussed the situation and role of radiology in tuberculosis. The scientific committee of the Asian Oceanian Congress of Radiology (AOCR) established the Asian Symposia in order to discuss important and relevant health topics with participating Asian radiological societies. At the AOCR 2023 Asian Symposia I: Situation and Imaging Innovation in Tuberculosis, different views, initiatives, and ideas were presented by representatives from various societies.

Keywords: Asian Symposia, Deep learning, Digital tomosynthesis, Epidemiology, Imaging, Low-dose computed tomography, Lung screening, MRI, National TB Eradication Program (NTEP), South-East Asia, Tracheobronchial stenosis, The International Union Against Tuberculosis and Lung Disease, Tuberculosis, Ultrasound.

Main messages:

- Tuberculosis (TB) is the world's top infectious killer and 50% of TB patients are seen in Asia.
- Understanding TB as a great mimicker, radiologists play a key role in early detection of the disease.
- Tracheobronchial stenosis is an important complication of active TB necessitating a multidisciplinary approach to treatment. It is diagnosed primarily by CT as chest radiographs may be normal in 20% of the cases.
- It is important to differentiate latent from active TB from a treatment perspective. Radiologists play an active role in differentiating between these two entities.
- A chest radiograph is the first test for diagnosing tuberculosis in patients with respiratory symptoms, but its accuracy is about 49%. Disadvantages of CT are radiation exposure and expensive examination. New imaging modalities, such as mediastinal ultrasound (US), ultralow dose CT, dual-energy subtraction digital radiography, digital tomosynthesis, MRI and tuberculosis diagnosis using deep learning, are also being used.
- Malaysia is committed to the vision of the National Strategic Plan for TB Control, for Malaysia to be a TB-free country by 2035.
- The latest National TB Eradication Program (NTEP) from India is marching towards TB eradication by 2025 by translating high level political commitment to action and working with international agencies and projects.
- The Korea Disease Control and Prevention Agency implemented the 'Measures to Strengthen TB Prevention Management,' in 2019. Korea's goal is to eradicate TB by 2030.

Introduction

The Asian Symposia was established by the Asian Oceanian Congress of Radiology (AOCR) scientific committee with the aim of discussing current burning issues in important and relevant health topics pertaining to Asian countries. The symposia were held on the second day of AOCR 2023 and participation was by invitation only. Tuberculosis (TB) and Post-Covid Lung were two important topics that took the spotlight in the AOCR 2023 Asian Symposia. This article elaborates on the various national perspectives on tuberculosis.

The following societies delivered a presentation and subsequently submitted a written report summarizing the point of view of their respective country or region: the Asian Society of Thoracic Radiology (ASTR), the Korean Society of Thoracic Radiology (KSTR), the College of Radiology, Academy of Medicine of Malaysia (COR, AMM), the Asian Oceanic Society of Paediatric Radiology (AOSPR), and the Indian Radiological & Imaging Association (IRIA).

The situation in Malaysia

Bushra Johari, representing the COR, AMM, stated that the TB incidence in Malaysia in 2020 reduced to 72.4 per 100,000 people, compared to 79.0 per 100,000 people in 2015. However, TB mortality increased from 7.1 per 100,000 people in 2020 compared to 5.5 per 100,000 people in 2015. Nevertheless, Malaysia is committed to the vision of the National Strategic Plan for TB Control, for Malaysia to be a TB-free country by 2035 [1]. Malaysia acknowledges that many challenges remain in materializing this vision. The country still deals with delays in diagnosing smear-negative pulmonary TB, challenging extra-pulmonary TB cases, and treatment default and non-adherence. The programmatic management of latent TB infection (LTBI), also known as TB preventive treatment, was recently launched and will take time to mature and produce results [1].

The management of active TB differs from that of latent TB, and radiologists play an important role in delineating between active forms of TB and an indolent infection. The typical presentation of active pulmonary TB in Malaysia is comparable to the existing literature, including parenchymal disease, lymphadenopathy, pleural effusion, miliary disease and airway involvement [2].

In recent years, Malaysia has seen cases of tracheobronchial stenosis as a presentation or complication of active pulmonary TB, especially in the young adult population. The infection of the tracheobronchial tree exists in 10–40% of patients with pulmonary TB, with the complication of tracheobronchial stenosis occurring in more than 60% of the patients within six months of disease progression [3]. Tracheobronchial stenosis in TB warrants early detection and intervention. Regular Multidisciplinary Team (MDT) discussions between respiratory physicians, thoracic radiologists, interventional pulmonologists and thoracic surgeons focusing on the diagnosis of endobronchial tuberculosis and the best treatment option is essential. There is also an ongoing effort to educate primary care physicians, general practitioners, general physicians and radiologists to recognize this condition, as they remain the front liners dealing with patients at the initial disease presentation. Chest radiograph (CXR) remains the first imaging modality in patients suspected of airway tuberculosis. It can appear normal in approximately 20% of cases [4] with total lung collapse or lobar collapse manifesting on CXR when the obstruction to the airway lumen is significant. CT scans can exquisitely identify the presence of stenosis, with a full assessment of the stenotic site and features of complications from the stenosis (Figure 1). Other less common findings of active pulmonary TB seen in Malaysia include the and non-confluent and confluent clusters of micronodules (Figure 2) and the nodular reverse halo sign.

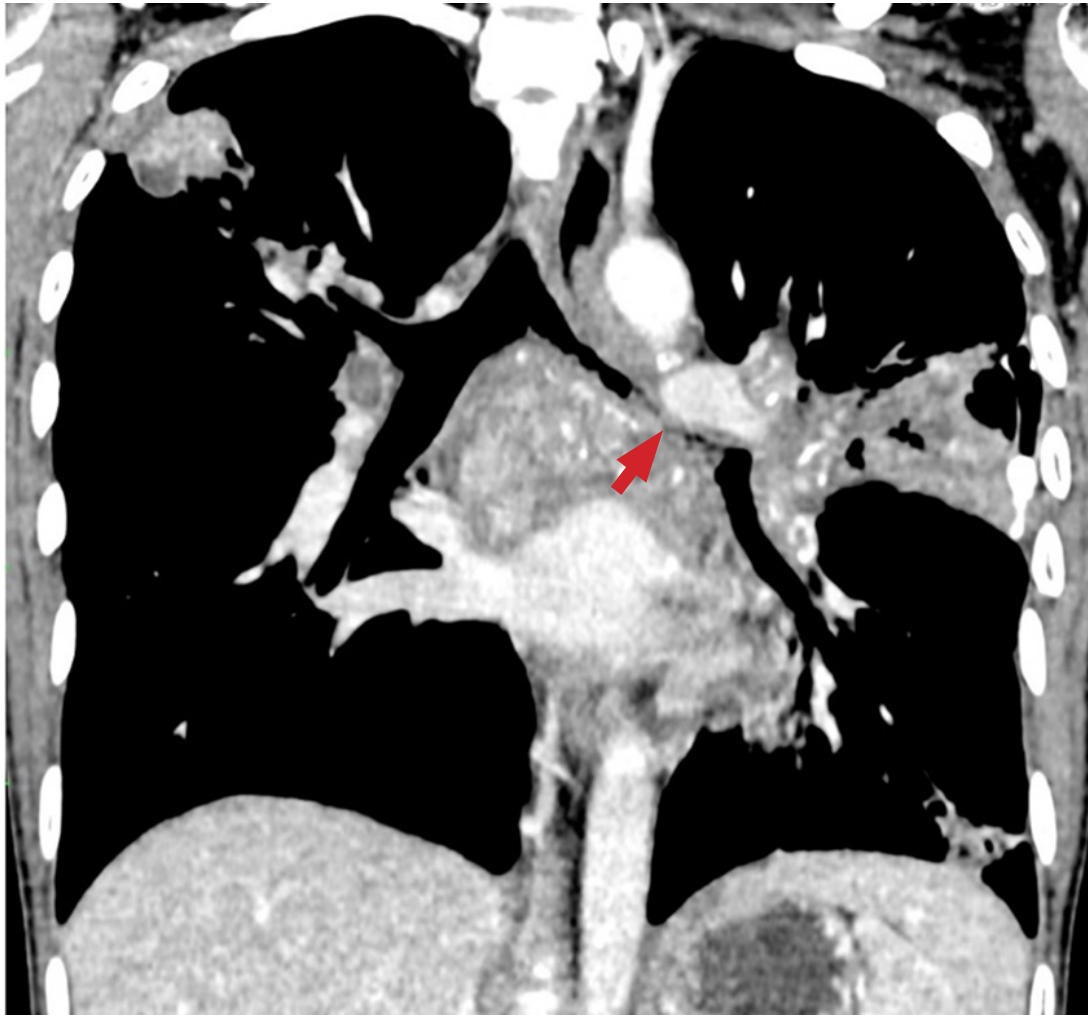

Figure 1. Coronal reconstruction of Contrast-Enhanced CT Thorax in mediastinal window demonstrates airway involvement in active pulmonary tuberculosis. There is significant narrowing of the left main bronchus compared to the right, with near total occlusion distally (arrow). The airway wall is thickened and irregular. There are multiple enlarged hypodense mediastinal and hilar lymph nodes which show calcification. Consolidation is also seen in the right and left lung.

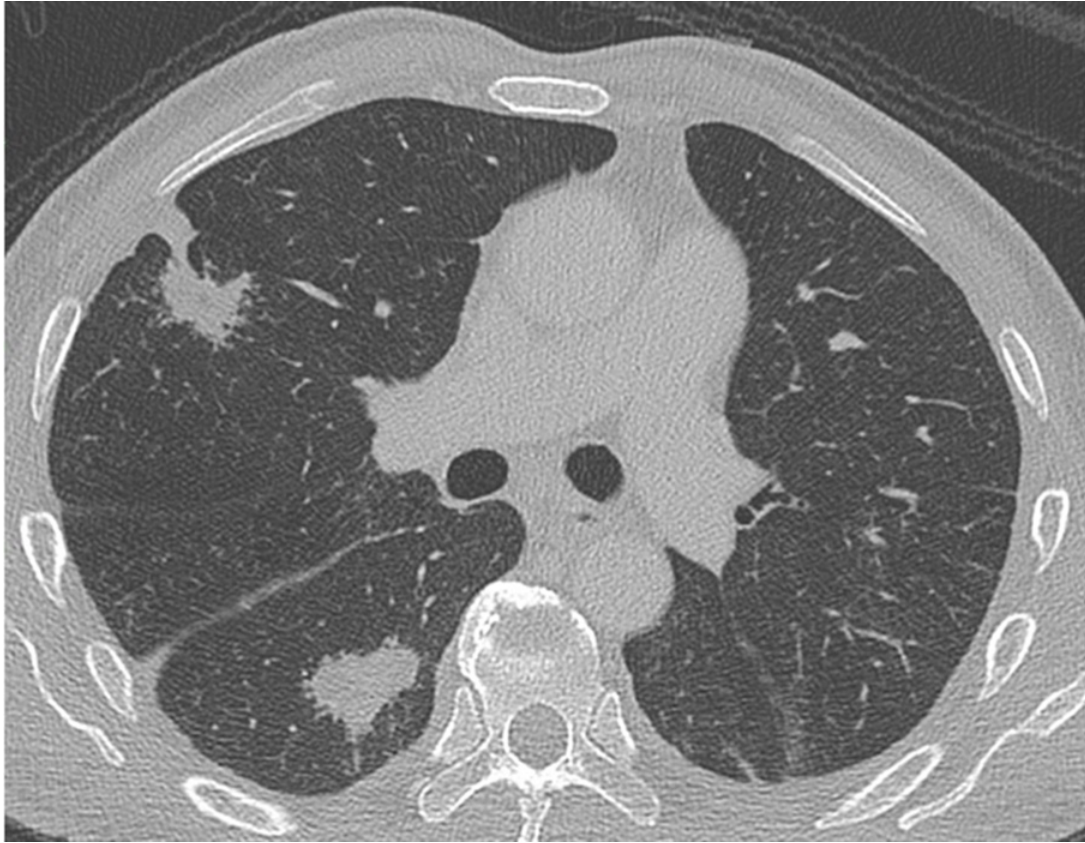


Figure 2. Axial CT Thorax in the lung window of a patient with active tuberculosis showing irregular lung lesions in the right upper and lower lobes. These macronodules were formed from the confluence of numerous tiny nodules, in keeping with the 'galaxy sign'.

Conclusion:

Malaysia recognizes that TB is still endemic and continues to be a significant public health concern. Efforts to reduce TB-related mortality and morbidity are still ongoing. Recognition of the spectrum of imaging findings of active TB is of utmost importance for us to achieve our goals and for a timely institution of treatment. Successful management of complicated active TB needs MDT discussion to ensure a good patient outcome.

General situation in India

Murali Krishna presented on behalf of the IRIA that TB is the top infectious disease killer in both India and the world alike. More than 1.9 million were affected by TB in the year 2021 [5]. The government of India had launched multiple programs to control the disease. The National TB Eradication Program (NTEP) with a goal to achieve rapid decline in the burden of TB, mortality and morbidity, while working towards the elimination of TB in India by 2025 [6].

Four strategic areas include detect, treat, prevent, and build pillars for universal coverage and social protection. The program provides various free of cost, quality tuberculosis diagnosis and treatment services across the country through the government health system. Pradhan Mantri TB Mukh Bharat Abhiyan (Prime Ministers TB Free India Program) was launched in India to provide additional nutritional support to those on TB treatment. Patients with TB would receive Rs 500 (\$8) a month for food.

The International Union Against Tuberculosis and Lung Disease (The Union) is the world's first scientific global health organization, founded in 1920, a leader in ending TB and HIV. The Union provides project implementation, operations research, technical support, and capacity building services.

The government of India has also undertaken multiple TB research projects and adopted Artificial Intelligence (AI) for improving the delivery of healthcare.

Conclusion:

India is marching towards a TB free India by 2025 through four strategies of detect, treat, prevent and build in collaborative government and private initiatives. Provision of free TB treatment, nutritional support and direct cash transfers have contributed enormously to the improvement of the situation. Constant research and innovation will contribute to the program expansion.

Situation in paediatric tuberculosis in India

Kushaljit Singh Sodhi presented on behalf of AOSPR, stated that as per the WHO estimates, every year, 10 million people fall ill with tuberculosis (TB) and nearly 1.5 million people die from TB each year, making it the world's top infectious killer [5].

The South and Southeast Asian regions have the highest number of TB estimates in the entire world, bearing nearly half of the global burden of TB disease [5]. It is now evident that five of the global high TB burdened countries are in these regions, which include India, Indonesia, Bangladesh, Myanmar and Thailand. They also account for the highest TB case fatality ratio, along with the African region. As per WHO 2022 report, 82% of global TB deaths among HIV-negative people occurred in the African and Southeast Asian regions.

A new imaging approach and future directions in TB imaging include the use of mediastinal ultrasound (US), Magnetic Resonance Imaging (MRI) and Artificial Intelligence (AI).

US imaging offers several advantages for the diagnosis of thoracic tuberculosis in children. It does not involve any radiation, is easily available, affordable, obviates need for sedation and can be performed at the bedside (portable). It is useful in the detection and characterisation of pleural effusion and in guiding aspiration and drainage procedures.

Mediastinal US has been proposed as an alternative to CXR in the detection of mediastinal lymph nodes, specifically in resource limited settings where US might be the only imaging modality [7]. A suprasternal approach or a parasternal approach can be performed. A study investigating children with pulmonary tuberculosis who had normal chest radiographs found mediastinal lymphadenopathy in 67% of children using US of the mediastinum. Limitations include operator dependence and subjectivity, but these can be overcome with experience and procedural standardization.

In paediatric TB, an enlarged abnormal lymph node is the key imaging finding in making correct and early diagnosis. MRI yields sensitivity, specificity and positive and negative predictive values of 100% for the detection of mediastinal lymph nodes >7 mm in size [8] (Figure 3).

MRI has also demonstrated perfect correlation with multidetector CT in the detection of pulmonary consolidation, nodules (>4 mm), cyst/cavity and pleural effusions [8] (Figure 4). Diffusion Weighted Imaging (DWI) - (restricted diffusion in infected lymph nodes) and contrast enhanced MRI, can demonstrate peripheral enhancement in caseating necrosis confirming the disease activity. Its use in daily clinical practice is limited by cost and availability, especially in low resource settings, but its use is advocated especially in a patient's follow-up at referral and academic centres, especially for a nodal disease.

AI would be especially useful in TB prevalent areas with limited access to radiologists. AI algorithms can be trained to recognize tuberculosis related abnormalities on chest radiographs. Various AI algorithms are available commercially today. Qin ZZ et al [9] evaluated TB detection from chest x rays for triaging in a high tuberculosis burdened setting and evaluated five AI algorithms. All five AI algorithms reduced the number of tests required by 50%, while maintaining a sensitivity above 90%. AI algorithms can be highly accurate and useful triage tools for tuberculosis detection in highly burdened regions, and potentially outperform a human reader.

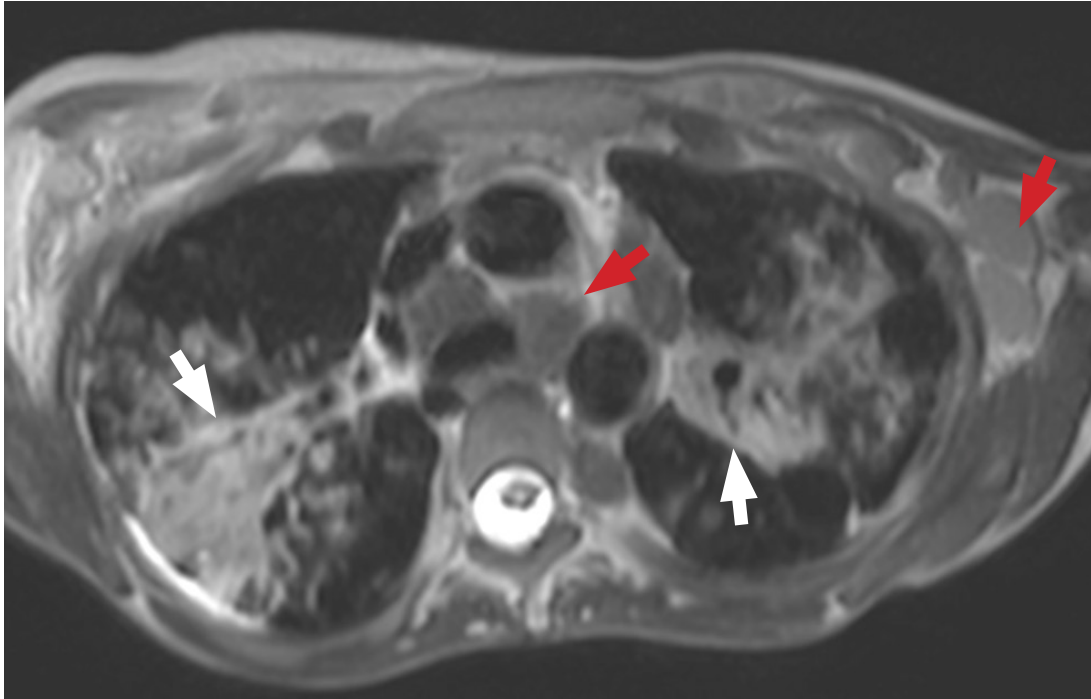


Figure 3. A 10-year-old girl with tuberculosis. Axial T2 TSE image shows areas of consolidation (white arrows) in bilateral lungs with coalescing centrilobular nodules on the right side. In addition, multiple enlarged mediastinal and axillary lymph nodes are also seen (red arrows).

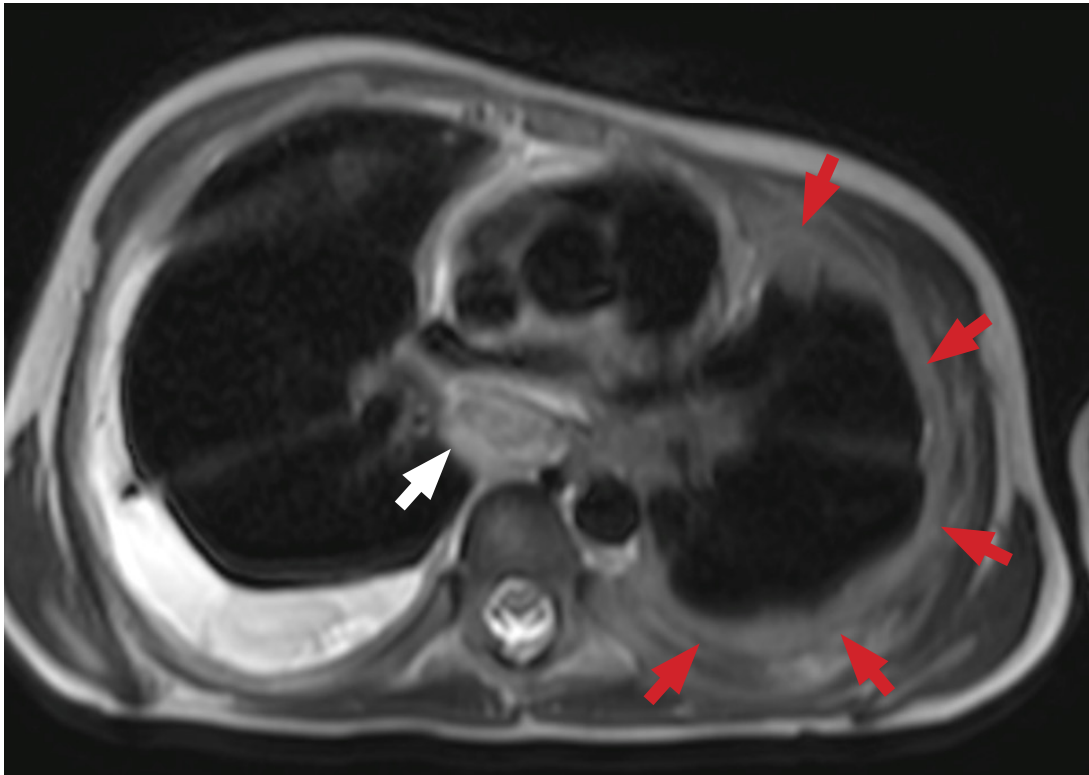


Figure 4. A 11-year-old boy with tuberculosis. Axial T2 TSE image shows a collection in the right pleural cavity. There is presence of an enlarged subcarinal lymph node seen (white arrow) with pleural thickening on the left side (red arrows).

Conclusion:

Tuberculosis still remains the most infectious global disease and fight against tuberculosis should include the optimal use of mediastinal ultrasound, MRI and Artificial Intelligence algorithms, so as to enable to detect and treat it at an earlier stage.

Situation in Korea

Ki Yeol Lee on behalf of the KSTR presented “Situation and Imaging Innovation in TB”.

TB is a serious health problem in the Republic of Korea. In 2021, among the 38 Organizations for Economic Cooperation and Development member countries (OECD), the Republic of Korea ranked highest in TB incidence (49 per 100,000 population) and third highest in TB mortality (3.8 per 100,000 population). The number of multidrug-resistant (MDR) TB cases dropped from 399 in 2020 to 371 in 2021. In 2022, to reduce the TB burden, the Korea Disease Control and Prevention Agency implemented the ‘Measures to Strengthen TB Prevention Management,’ which was established in 2019. To that end, Korea’s goal is to eradicate TB by 2030.

Latent Tuberculosis Infection (LTBI) has been used to define a state of a persistent immune response to stimulation by TB antigens through tests such as the tuberculin skin test (TST) or an interferon- γ release assay (IGRA) without clinically active TB. Recently, the WHO has suggested the removal of the word “latent”, leaving the term “TB infection” only [10, 11].

The spectrum from TB infection to TB disease includes uninfected individuals, TB infection, incipient TB, subclinical TB without signs/symptoms, subclinical TB with unrecognised signs/symptoms, and TB disease with signs/symptoms [11] (Figures 5-8).

A CXR is the first test for diagnosing tuberculosis in patients with respiratory symptoms, but its accuracy is about 49%. Disadvantages of CT are radiation exposure and expensive examination. New imaging modalities, such as ultralow dose CT, dual-energy subtraction digital radiography [12], digital tomosynthesis [13], MRI and tuberculosis diagnosis using deep learning, are also being used.

In 2021, the WHO published guidelines for the screening of TB disease. The new guidance states that among individuals aged 15 years and older in a population in which TB screening is recommended, CAD (computer-aided diagnosis) may be used in place of human readers for interpreting digital chest X-rays for screening and triage for TB disease. In addition, to automatically detect tuberculosis lesions, it is now possible to help determine the activity of pulmonary TB by scoring it [14].

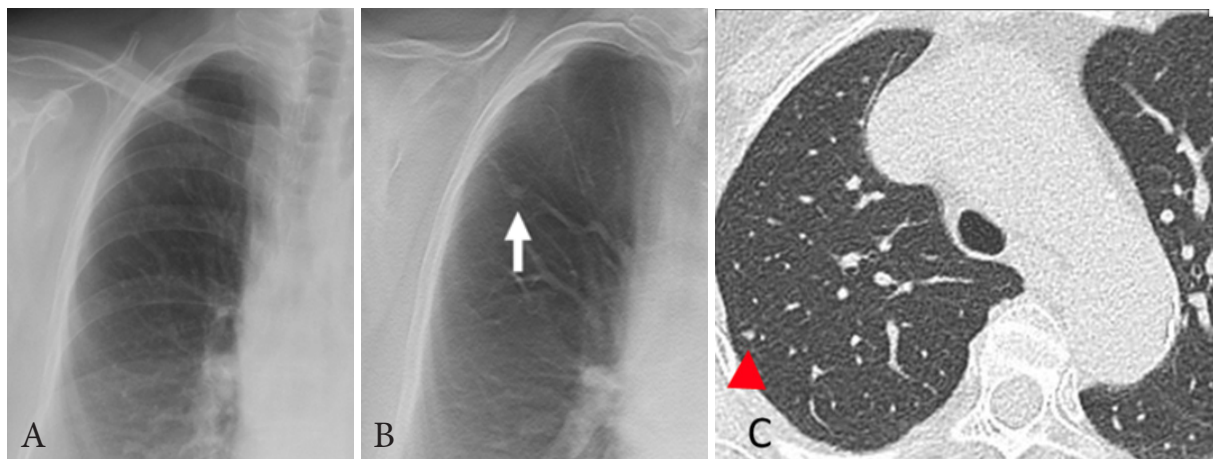


Figure 5. *A case showing tuberculosis spectrum: An asymptomatic 77-year-old female patient underwent contact screening. The chest radiograph is normal (A), but digital tomosynthesis (B) and a CT scan (C) show a small nodule on the right upper lobe. This patient tested positive on her IGRA test. In other words, she had evidence of tuberculosis infection, but she had no evidence of active TB disease clinically, bacteriologically, or radiologically. Therefore, she could be diagnosed with tuberculosis infection. She did not receive a treatment for TB infection because she was an elderly.*

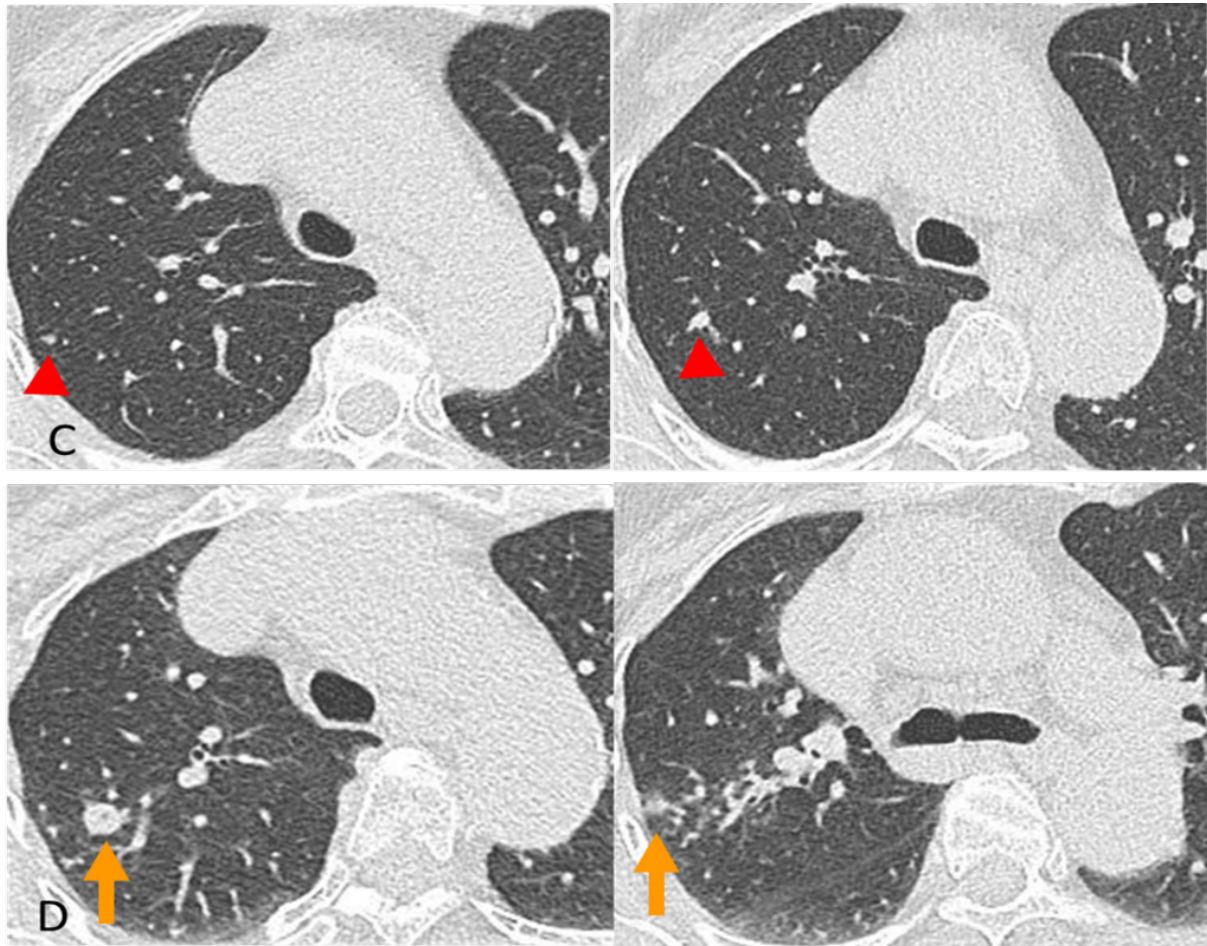


Figure 6. A case showing tuberculosis spectrum: An asymptomatic 77-year-old female patient underwent contact screening. On the CT scan performed 3 months later (D), the existing nodules of the right upper lobe enlarged, and centrilobular nodules and tree-in-bud are newly observed around the nodules of the right upper lobe. In the perspective of the new TB spectrum, this patient's condition can be considered as an incipient TB, in which, without intervention, it may develop into active TB disease in the near future. (Courtesy of Yeon Joo Jeong, Pusan National University Hospital, Korea).

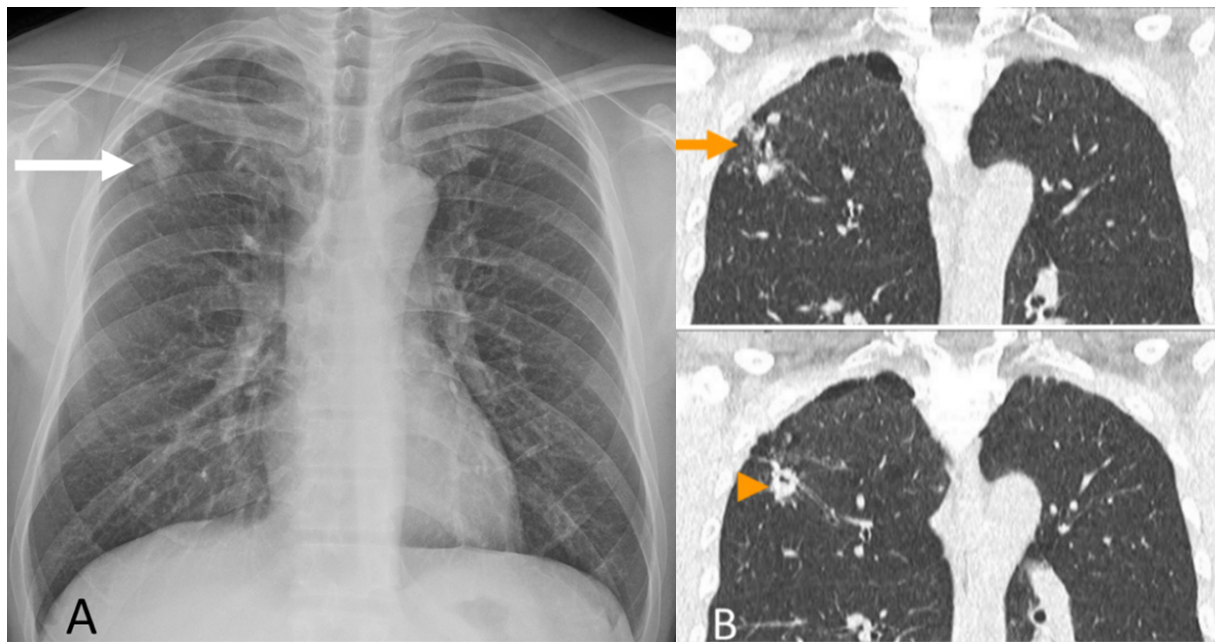


Figure 7. *Detection of subclinical tuberculosis on ultra-low dose CT: 51-year-old male patient diagnosed with rectal cancer and underwent ultra-low dose CT for metastasis work up. A chest radiograph shows ill-defined nodular opacities in the right upper lung zone (arrow, A). An ultra-low dose CT performed on the same day (B) shows small nodules in the right upper lobe (arrow) and a cavitary nodule (arrowhead). This case is subclinical tuberculosis, for which ultra-low dose CT is very useful for diagnosing early tuberculosis.*

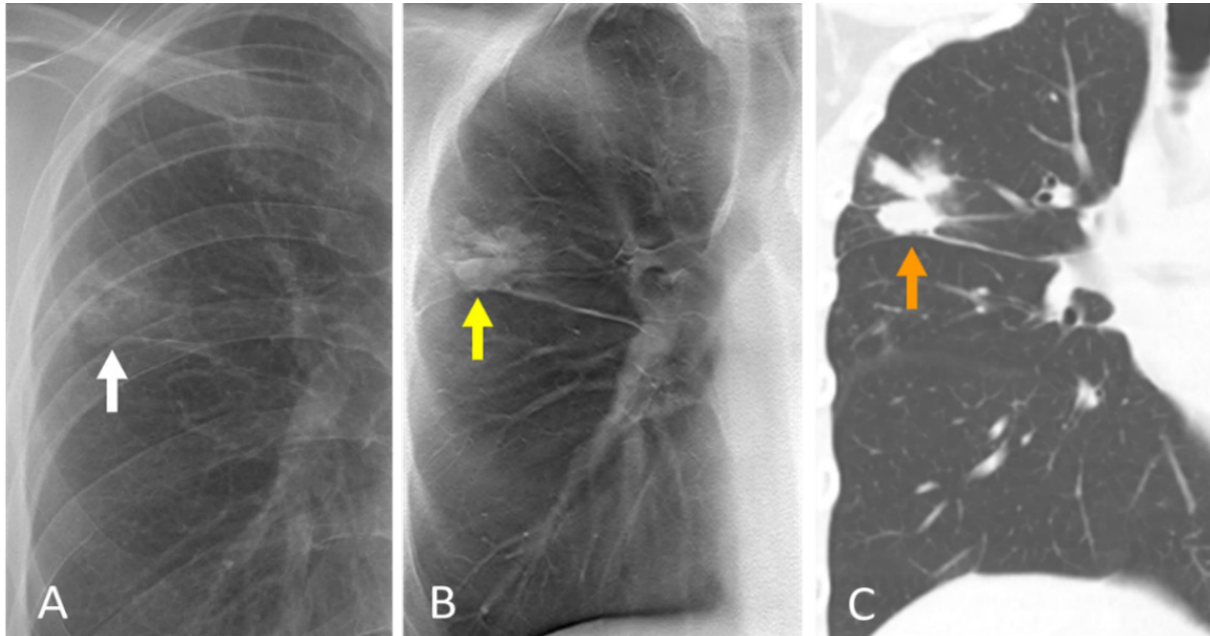


Figure 8. *Detection of patchy consolidation on digital tomosynthesis: a 27-year-old male patient diagnosed with MDR TB. Suspicious focal patchy consolidation is seen in the right upper lung zone on the chest radiograph (arrow in A). The patchy consolidation is more clearly visible on digital tomosynthesis (arrow in B) in the right upper lobe than in the chest radiograph. Coronal chest CT imaging on the same day confirms this lesion as a patchy air-space consolidation in the right upper lobe (C).*

Conclusion:

The evolution of the definition of “tuberculous infection” includes the continuum of stages, existing TB infection and diseases. Recently, the WHO has adopted the term “TB infection” to better denote “a continuum” in the process, which follows inhalation of bacilli and may lead to the clinically manifested TB disease.

Digital tomosynthesis has a promising role for improving the diagnostic accuracy of chest x-rays in the detection of TB. The clinical implementation of an optimized MRI protocol with the motion correction technique is feasible for imaging pulmonary TB. In addition, automated detection of TB in chest x-rays may facilitate screening and evaluation efforts in TB prevalent areas that are difficult to access by radiologists.

Acknowledgements

This paper was prepared by Professors Mini Pakkal and Jin Mo Goo, Chairperson(s) of the Asian Symposia Asian I: Situation and Imaging Innovation in Tuberculosis, with the support of Associate Professor Wiwatana Tanomkiat, scientific chair of AOCR2023 on the basis of the presentations and summary reports delivered at the symposia by:

- a. Professor Bushra Johari, representing the College of Radiology, Academy of Medicine of Malaysia (COR, AMM),
- b. Professor Kushaljit Singh Sodhi, Professor, Department of Radio diagnosis & Imaging, Post Graduate Institute of medical education & Research, Chandigarh, India represented the Asian Oceanic Society of paediatric radiology (AOSPR),
- c. Professor L Murali Krishna presented on behalf of the Indian Radiological & Imaging Association and
- d. Professor Ki Yeol Lee, Korea University Medicine on behalf of the Korean Society of Thoracic Radiology Ki Yeol Lee, M.D., Ph.D., Korea University Medicine on behalf of the Korean Society of Thoracic Radiology.

The paper was provided to the presenters for feedback. It was approved by Associate Professor Wiwatana Tanomkiat, scientific chair of AOCR on 14th August 2023.

References

1. Malaysian Health Technology Assessment Section (MaHTAS), Medical Development Division, Ministry of Health Malaysia. Clinical Practice Guidelines: Management of Tuberculosis. 4th ed. Putrajaya, Malaysia: Federal Government Administrative Centre; 2021 [cited 2023 Aug 15]. Available from: <http://www.moh.gov.my>.
2. Nachiappan AC, Rahbar K, Shi X, Guy ES, Mortani Barbosa EJ Jr, Shroff GS, et al. Pulmonary Tuberculosis: Role of Radiology in Diagnosis and Management. *Radiographics* 2017;37:52-72. doi: 10.1148/rg.2017160032.
3. Khvilivitzky K, Trivedi PN, McFadden PM. Tuberculous tracheobronchial stenosis: avoiding resection-when less is more. *J Thorac Dis* 2017;9:E779-82. doi: 10.21037/jtd.2017.08.104.
4. Neke NS. Endobronchial tuberculosis: an overview. *Ann Pak Inst Med Sci [Internet]*. 2013 [cited 2023 Aug 15];9:105-9. Available from: <https://www.pakmedinet.com/28727>.
5. The WHO Global Tuberculosis Report 2022 [Internet]. Geneva: WHO; 2023 [cited 2023 Aug 15]. Available from: <https://www.who.int/teams/global-tuberculosis-programme/tb-reports/global-tuberculosis-report-2022>.
6. Ministry of Health and Family Welfare, Government of India [Internet]. India TB Report 2022 . New Delhi: Central TB Division; 2022 [cited 2023 Aug 15]. Available from: <http://tbcindia.gov.in/WriteReadData/IndiaTBReport2022/TBAnnulReport2022.pdf>.
7. Bosch-Marcet J, Serres-Créixams X, Borrás-Pérez V, Coll-Sibina MT, Guitet-Juliá M, Coll-Rosell E. Value of sonography for follow-up of mediastinal lymphadenopathy in children with tuberculosis. *J Clin Ultrasound* 2007; 35:118-24. doi: 10.1002/jcu.20304.

8. Sodhi KS, Khandelwal N, Saxena AK, Singh M, Agarwal R, Bhatia A, et al. Rapid lung MRI in children with pulmonary infections: Time to change our diagnostic algorithms. *J Magn Reson Imaging* 2016;43:1196-206. doi: 10.1002/jmri.25082.
9. Qin ZZ, Ahmed S, Sarker MS, Paul K, Adel ASS, Naheyan T, et al. Tuberculosis detection from chest x-rays for triaging in a high tuberculosis-burden setting: an evaluation of five artificial intelligence algorithms. *Lancet Digit Health* 2021;3:e543-54. doi: 10.1016/S2589-7500(21)00116-3.
10. World Health Organization. WHO operational handbook on tuberculosis. Module 1: prevention . tuberculosis preventive treatment. Geneva: WHO; 2020.
11. Migliori GB, Ong CWM, Petrone L, D'Ambrosio L, Centis R, Goletti D. The definition of tuberculosis infection based on the spectrum of tuberculosis disease. *Breathe (Sheff)* 2021;17:210079. doi: 10.1183/20734735.0079-2021.
12. Sharma M, Sandhu MS, Gorski U, Gupta D, Khandelwal N. Role of digital tomosynthesis and dual energy subtraction digital radiography in detection of parenchymal lesions in active pulmonary tuberculosis. *Eur J Radiol* 2015; 84:1820-7. doi: 10.1016/j.ejrad.2015.05.031.
13. Mok J, Yeom JA, Nam SW, Yoo JM, Lee JW, Lee G, et al. Role of digital tomosynthesis in the context of tuberculosis contact investigation: comparisons with digital radiography. *Acta Radiol* 2022; 63:901-8.
14. Lee S, Yim JJ, Kwak N, Lee YJ, Lee JK, Lee JY, et al. Deep learning to determine the activity of pulmonary tuberculosis on chest radiographs. *Radiology* 2021;301:435-42. doi: 10.1148/radiol.2021210063.