



Case Report

Increased Muscle Uptake of Bone Seeking Agent in A Patient with Polymyositis: A Case Report

Pawana Pusuwan, MD.

Division of Nuclear Medicine, Department of Radiology, Faculty of Medicine Siriraj Hospital,

Mahidol University, Bangkoknoi, Bangkok 10700, Thailand.

Abstract

A 38-year-old male presented with fever, muscle pain, weakness and acute renal failure. Tc-99m methylene diphosphonate (MDP) bone scan showed increase uptake by muscles of the shoulders and hips. Biopsy of the deltoid muscle was compatible with myositis. On two consecutive follow-up scans, the degree of muscle uptake correlated well with the recovery of the disease.

Keywords: Bone scan; polymyositis; acute renal failure

Introduction

Tc-99m MDP bone scan, introduced by Subramanian and McAfee¹ in 1971, has become one of the most widely used investigations in nuclear medicine for a variety of benign and malignant skeletal conditions¹. The major mechanism of the tracer binding into the skeleton is chemisorption. Soft tissue uptake is an uncommon finding on bone scan.

Case Report

A 38-year-old male presented with progressive 5 weeks history of fever, pain and weakness in his proximal upper and lower extremities. Seven days before admission he had a difficulty in walking with swelling legs. There was no previous history of strenuous exercise or using alcohol or drugs. He had no family history of neuromuscular disorder.

Upon admission, laboratory values showed a serum BUN of 194 mg/dl, serum creatinine of 10.9 mg/dl, serum creatinine phosphokinase (CPK) of 49,506 U, calcium 4.5 mg/dl and phosphate 12 mg/dl. A Tc-99m MDP bone scan demonstrated increased radioactivity uptake in various muscles at bilateral shoulders and hips. Increased uptake in bilateral enlarged kidneys was noted (Fig.1). Small amount of faint activity in the urinary bladder was seen. Biopsy of the deltoid muscle was compatible with myositis. Acute renal failure from polymyositis with rhabdomyolysis was most likely.

After steroid therapy with hemodialysis, the patient's renal impairment and muscle strength gradually improved. Follow-up bone scan 2 weeks later showed only small amount of muscle uptake persistence at bilateral shoulders and hips (Fig.2). The last bone scan done one month later appeared unremarkable.

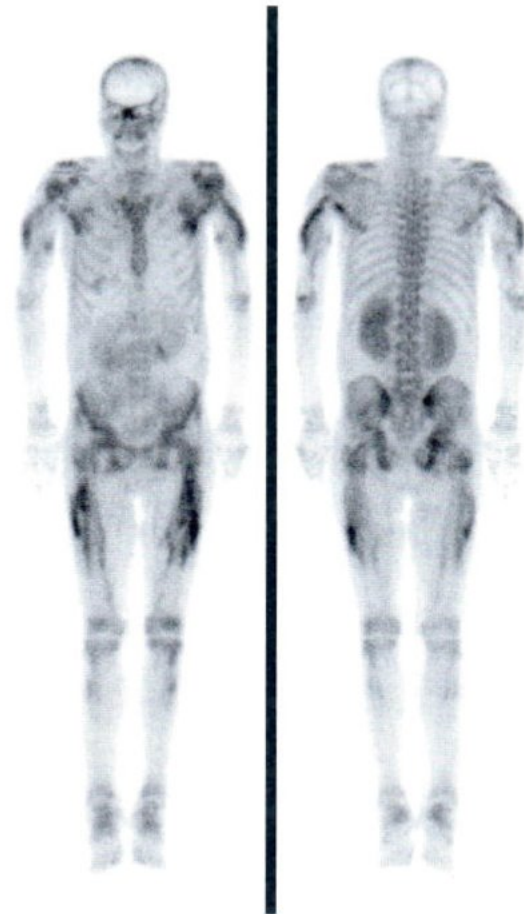


Fig.1 Tc-99m MDP bone scan shows increased radioactivity uptake in the muscles of shoulders and hips.

Discussion

Bone scan provides very sensitive information about the abnormalities of bone physiology. The most frequent nonosseous uptake on bone scan is related to the urinary system². Other nonbony structures can be demonstrated on the bone scan. The recognition of these extraosseous uptake is important for accurate interpretation of the scan although the main purpose of the study is to address the skeletal abnormalities.

The presence of diffuse skeletal muscle uptake on bone scan is rare. Increased uptake in

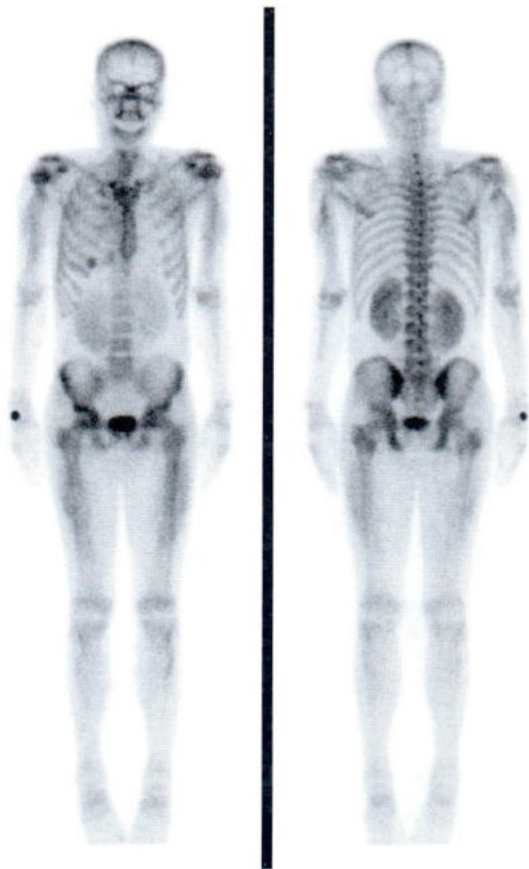


Fig.2 Follow-up bone scan 2 weeks after the first study shows diminished radioactivity uptake in the muscles.

the muscles of shoulders and hips with the clinical symptoms of muscle pain and weakness in this case lead to the suspicion of polymyositis which was confirmed by muscle biopsy. Polymyositis is reported as one of the principle cause for muscle uptake on bone scan³⁻⁵. It is a rare autoimmune disease characterized by progressive muscle inflam-

mation. This illness can lead to symmetric proximal muscle weakness of the extremities and severe disability. Spies DM, et al reported the first case of Tc-99m phosphate uptake in inflammatory muscle disease⁶. Other reported causes include rhabdomyolysis, dermatomyositis, muscular dystrophy, amyloidosis, overexertion, HIV-associated myositis, paraneoplastic syndrome and uremic myositis⁷.

Tc-99m MDP bone scan in a patient suspicious of polymyositis may be useful to confirm the diagnosis of inflammatory muscle and also localize the appropriate site for muscle biopsy.

References

1. Subramanian G, MacAfee JG. A new complex of 99mTc for skeletal imaging. *Radiology* 1971;99:192-6.
2. Loutfi I, Collier D, Mohammed AM. Nonosseous abnormalities on bone scan. *J Nucl Med Tech* 2003;31:149-53.
3. Yonker RA, Webster EM, Edwards NL, Katz P, Longley S, Petersen H, et al. Technetium pyrophosphate muscle scans in inflammatory muscle disease. *British J of Rheumatology* 1987;26:267-9.
4. Kim HW, Choi JR, Jang SJ, Chang YS, Bang BK, Park CW. Recurrent rhabdomyolysis and myoglobinuric acute renal failure in a patient with polymyositis. *Nephrol Dial Transplant* 2005;20:2255-8.
5. Niemir Z, Oleksa R, Czepczynski R, Sowinski J. Increased uptake of technetium-99m methylene diphosphonate in muscles in the course of polymyositis. *Nucl Med Review* 2005;8:153-4.
6. Spies SM, Swift TR, Brown M. Increased technetium-99m polyphosphate muscle uptake in a patient with polymyositis. *J Nucl Med* 1975;16:1125-7.
7. Datz FL. *Gamuts in nuclear medicine* (3rd edn). Mosby-Year Book, Inc. 1995.