

UTERINE FIBROID EMBOLIZATION(UAE): CHANGE IN VOLUME OF FIBROID AND THE UTERUS

Krisdee PRABHASAVAT, Pattamapun ANANTAPONG,
Chutakiat KRUATACHUE, Trongtum TONGDEE, Saowanee HOMSUD,
Weesak WONGTIRAPORN, Chanchai VANTANSIRI¹

ABSTRACT

Purpose: For evaluation the effectiveness of bilateral uterine arterial embolization, (UAE) in the treatment of fibroids, in aspect of changes in volume of fibroid and the uterus.

Material and Method: Retrospective study of pre and post UAE MRI in 8 Thai women, mean age 36 years who were to undergo bilateral UAE of uterine fibroids, from January, 2006-January, 2008. The follow up MRI was 15d, 1month, 3months(3 pts), 6months(2pts) and 2 yrs(1pt). Bilateral UAE was performed by injecting 500-700 micron polyvinyl alcohol (PVA) or 700-900 micron Beadblock. Two radiologists interpret MRI by consensus. The volume of fibroid and the uterus was calculated by the formula;lengthxdepthxwidth x 0.523. The signal intensity change in MRI after UAE was observed.

Result: Technical results Bilateral embolization of uterine arteries was accomplished in all patients(100%). Patients had multiple fibroids(range 1-6 lesions). 26 fibroids were noted. The volume of fibroids varied from 3.6-512.4 cm³(mean=94.1 cm³). The mean volume reduction of fibroids after bilateral UAE was 36.75%. The mean volume reduction of intramural lesions was 44.54%. The mean volume reduction of subserosal and submucosal lesions were 28%and 25% respectively. No major complication, no mortality was occurred.

Conclusion: Significant volume reduction of fibroid after bilateral uterine artery embolization for treatment of fibroid with good clinical outcomes.

UAE = Uterine Artery Embilization

pts = patients

Uterine fibroid is the most common gynecologic tumor in reproductive age, being symptomatic about 25-30% of women but present in as many as 70-80% of women by age 50. Uterine fibroids are caused by abnormal growth of sex steroid-responsive muscle cells in the myometrium. Although benign, fibroids can grow at very rapid rates and cause a constellation of symptoms, including menorrhagia (excessive menstrual bleeding), pelvic pressure,

infertility, pregnancy loss and abdominal distension. Symptomatic fibroids have generally been treated by hysterectomy. Other treatment including myomectomy, myolysis, cryoablation and hormone therapy have been used in selected cases. The common hysterectomy carries complications about 10-15% of surgery with several days of hospital stay and long recovery time. Myomectomy has similar associated risks and approximately 20-25% of women undergoing

¹ Radiology Dept, and OB-GYN Dept.. Siriraj Hospital Faculty of medicine, Mahidol University.

myomectomy will have a recurrence of symptoms, requiring further intervention. Myolysis and cryoablation both also require laparotomy or laparoscopy and general anesthesia, and reported results have been mixed. Hormonal therapy is effective for short-term control but requires continued medication and has associated side effect, such as hot flashes, mood swings, insomnia and dyspareunia.

Uterine arterial embolization (UAE), a recognized treatment of acute pelvic hemorrhage, has become accepted as an effective and safe treatment for fibroids. This minimally invasive procedure requires a recovery of days rather than weeks but has results similar to those of other uterine-saving therapy.

The purpose of the study is to evaluate the effectiveness of bilateral uterine arterial embolization in the treatment of fibroids, in aspect of change in volume of fibroid and the uterus.

MATERIAL AND METHOD

Retrospective study of MRI of 12 consecutive women, age ranged 27-41 years (mean age, 36 years) who were to undergo bilateral UAE of uterine fibroids, from January, 2006-January, 2008.

8 patients were Thai women and the other 4 patients were foreigners. We studied only the imagings and clinical informations of Thai patients.

Every patients underwent MRI of lower abdomen before and after bilateral UAE, by using 3 T system (Achieva, Phillips). The MRI included sagittal T2W/TSE, coronal SSH/TSE, axial T2W/TSE/SPAIR, axial T2W/TSE, axial T1FFE/Inphase and THRIVE/GD/FS.. The follow up MRI was 15d, 1 month, 3 months (3 pts), 6 months (2pts) and 2 yrs (1pt).

Embolization was performed via unilateral femoral approach. Bilateral uterine arteries were selective catheterized in all cases. We used Robert pre-shape uterine catheter or 4 F. cobra-head guiding catheters. Embolization was achieved by injecting 500-700 micron polyvinyl alcohol (PVA) or 700-900 micron Beadblock into each uterine artery until the flow had ceased before refluxing of contrast media into anterior division of internal iliac artery.

Conscious sedation with combination of narcotics (morphine sulfate, fentanyl citrate, or both) and benzodiazepines (midazolam hydrochloride) was used in all patients.

The volume of fibroid and the uterus was calculated by the formula; lengthxdepthxwidth x 0.523. The signal intensity change in MRI after UAE was observed. The signal intensity of fibroid was compared to myometrium.

Two radiologists interpreted all MRI by consensus. Statistic analysis was performed using average value.

RESULT

Technical results:

Bilateral embolization of uterine arteries were accomplished in all patients(100%)

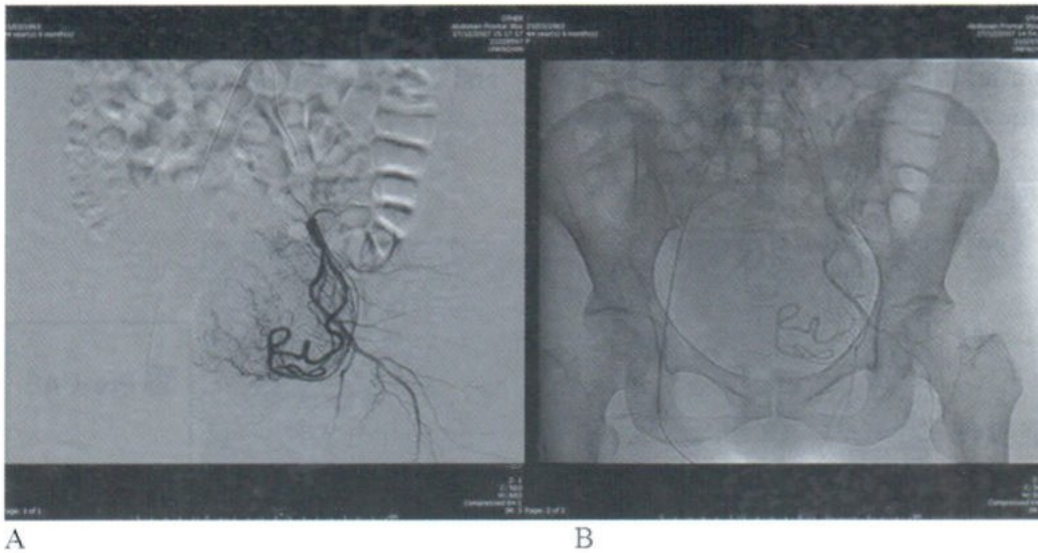


Fig.1 Uterine arteriogram of a patient, presented with a feeling of having a big mass in the pelvis. A. Pre-UAE arteriogram revealed tortuous enlarged Lt. uterine artery with hypervascular mass at Lt. side of uterus. B. After Lt. uterine artery embolization with 500-700 micron PVA, disappearance of hypervascular mass and cessation of blood flow of ascending part of Lt. uterine artery was seen.

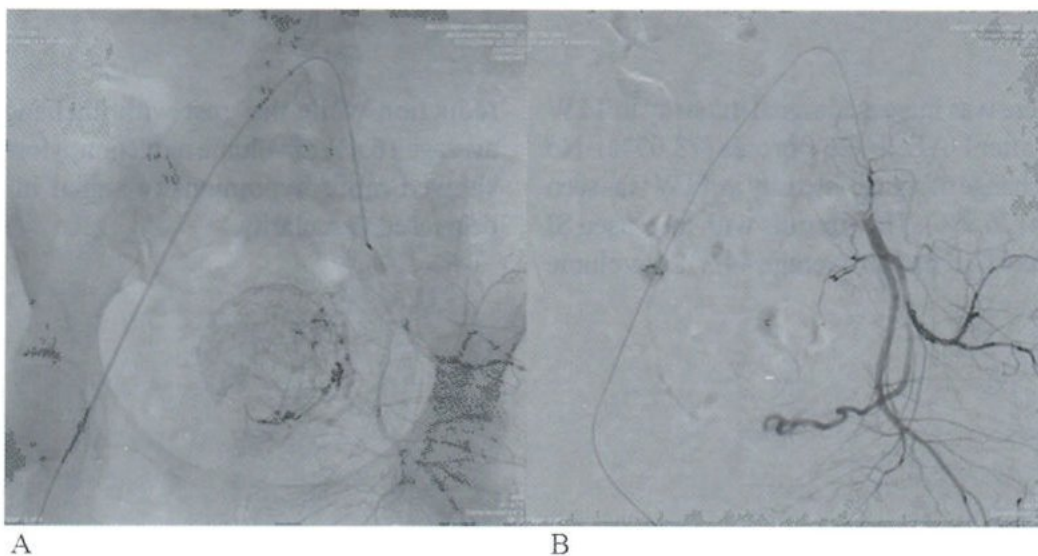


Fig.2 Lt. uterine arteriogram of patient presentation with menorrhagia. A. Pre-UAE arteriogram revealed diffuse hypervascularity area at Lt. lateral fundus. B. After Lt. uterine embolization with 500-700 micron PVA, disappearance of hypervascularity was noted.

Imaging Follow up:

Patients had multiple fibroids(range 1-6 lesions). 26 fibroids were noted. 15 intramural, 7 subserosal and 4 submucodal fibroids were identified. The volume of fibroids varied from 3.6-512.4 cm³ (mean = 94.1 cm³). 24 of 26 fibroids (92.3%) showed volume reduction. The mean volume reduction of fibroids after bilateral UAE was 36.75%. The mean volume reduction of intramural lesions was

44.54%. The mean volume reduction of subserosal and submucosal lesions were 28%and 25% respectively. The fibroid with intermediate-high signal intensity in T1W before UAE were 41.07% reduction of volume after UAE. Those lesions with pre-UAE isointensity and hypointensity in T1W showed 31.8% and 34.5% of volme reduction.

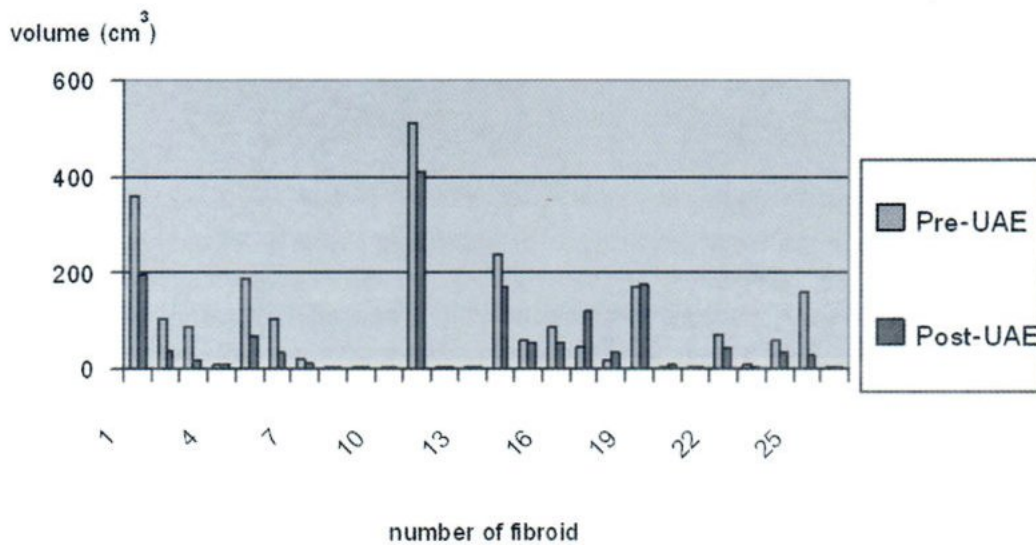


Fig.3 Graph illustrates a comparison of fibroid volume before and after bilateral UAE

There was increased signal intensity in T1W of fibroids after UAE, 24/26 fibroids (73.07%). No significant change of signal intensity in T1W was seen in 7 lesions (26.9%). The fibroids with increased SI in T1W after UAE had an average 44.3% of volume

reduction while the rest with unchanged SI had average 16.4% of volume reduction. Most of fibroids showed more hypointensity signal in T2W and decreased vascularity.

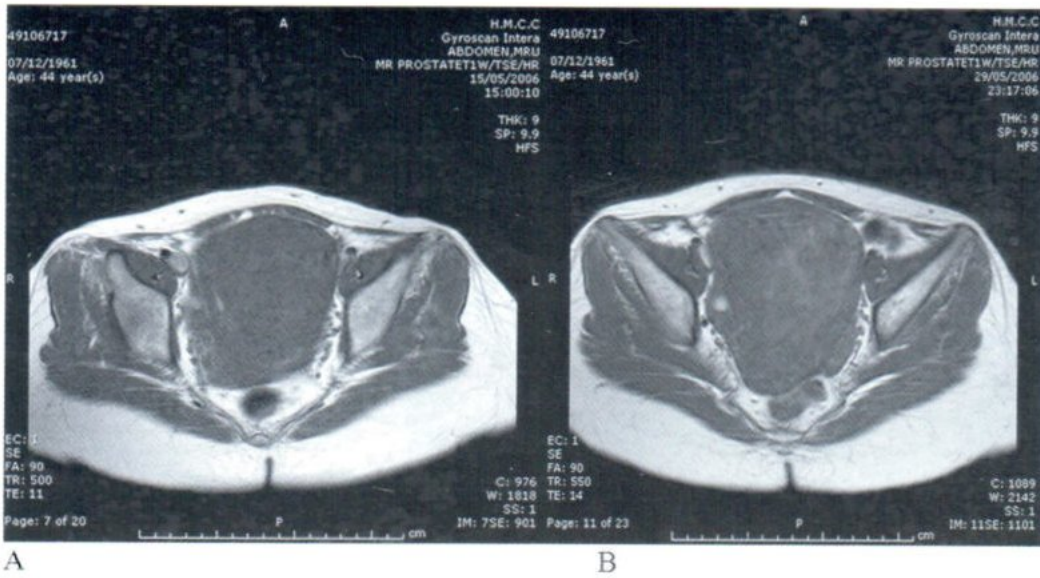


Fig.4 T1-weighted axial image of the uterus. A:Prior to UAE. Large intramural fibroid with isosignal intensity. B:15 days post-UAE image revealed heterogenous increased signal intensity, represents hemorrhagic infarction.

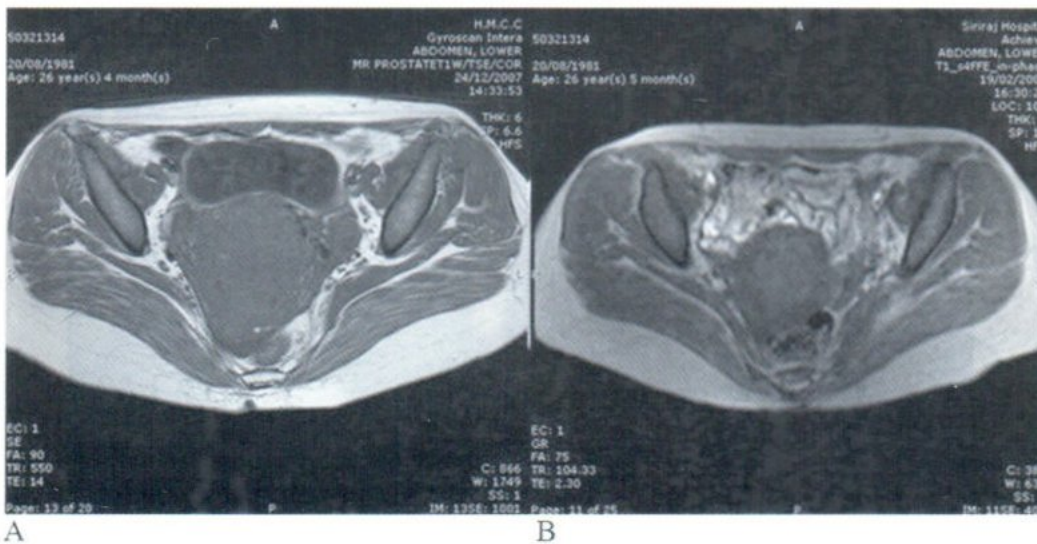


Fig.5 Axial T1W of uterus with fibroid. A. Prior to UAE. B.3 months post-UAE. There was decreased in size of fibroid and the uterus. Increased signal intensity of fibroid was noted.

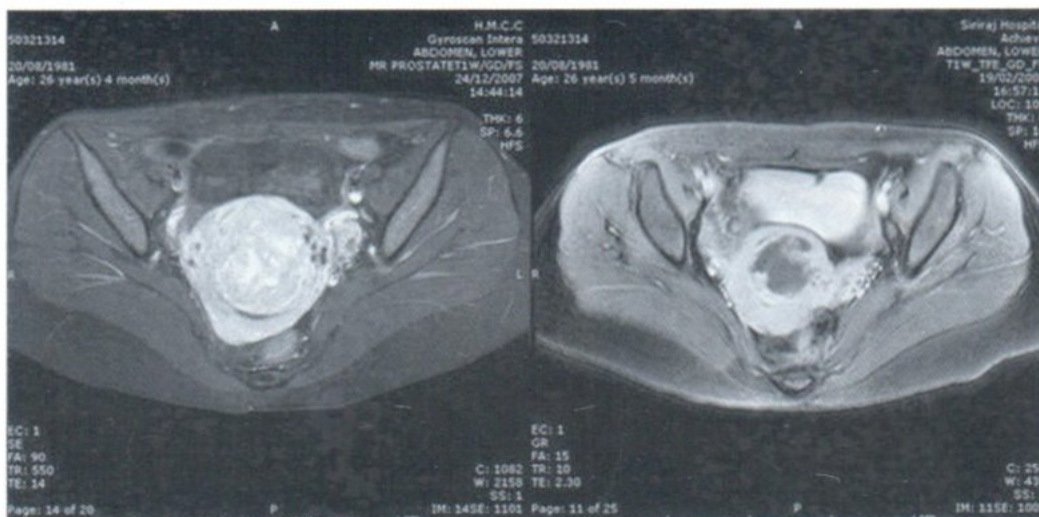


Fig.6 Axial T1W Gd-enhanced images. A. Prior to UAE showed hypervascular fibroid at fundus. B. 3 month post-UAE image revealed degeneration of fibroid with decreased size and vascularity.

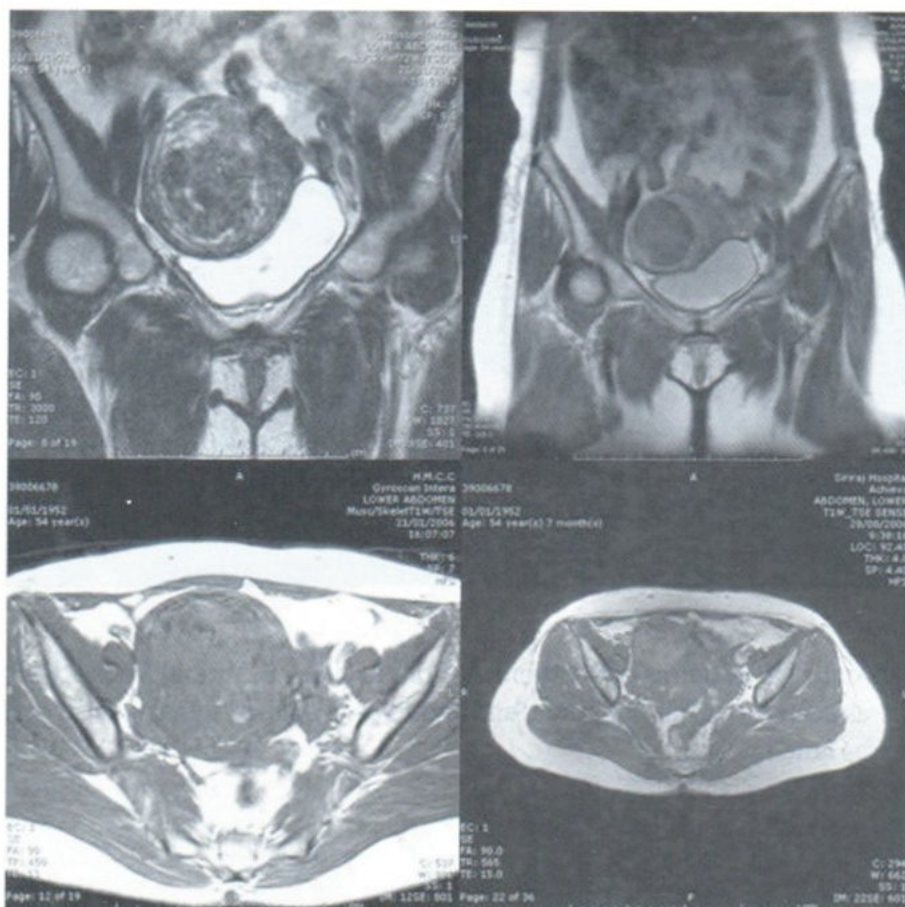


Fig.7 Coronal and axial MRI images in pre-UAE (A,B) and 1 month post-UAE (C,D) Post-UAE images revealed significant decreased size of fibroid with hemorrhagic infarction.

The volume of the uterus was calculated by total volume of the uterus-total volume of fibroids. The volume reduction of the uterus after UAE was 32.1% (range 17.2-47.4%). The greater volume reduction was observed in patients at 3 and 6 months (3 and 2 pts) after UAE, 30.9% and 41.7% respectively. One patient at 2 yrs post-UAE had 10.9% of uterine volume reduction and 37.7% of fibroid volume reduction.

Clinical Follow Up:

The patient clinical presentations were menorrhagia (4 pts), bulk-related symptoms (3 pts), dysmenorrhea (3 pts), infertility (2 pts). 48 hrs follow up revealed moderate pelvic pain in 2 pts with recovery in few days by using of narcotics. Abnormal bleeding and dysmenorrheal were significant improved in 3 of 4 pts (75%) and minimal improved in 1 pt. Bulk-related symptoms were improved in all 3 pts. (100%) All patients (8pts) (100%) were satisfied with clinical results. The average hospital stay was ranged 2-3 days (mean = 2.2 days)

DISCUSSION

Findings from this study demonstrated significant volume reduction of fibroid after UAE at 1, 3, 6 month and 2 years (36.9%, 34.5%, 39.2% and 37.7 % respectively) The volume reduction of the uterus was obviously, 28.9%, 30.9%, 41.7% and 10.9% at 1, 3, 6 month and 2 years after UAE. A significant decreased in size of the uterus and fibroids has been described by various investigators. Laurent et al. reported the 23% mean size reduction of fibroids in series during the first 3 months after embolization whereas reported by Worthington-Kirsch et al 46% and that by Burn et al 43%. The volume reduction of the dominant fibroid is greater than that of the uterus. The follow up ultrasound has shown a reduction in uterine size of upto 40% with the dominant fibroid decreasing in size by upto 70%. The majority of fibroid shrinkage occurs within 6 month period following embolization with further reduction in size occurring between 6 and 12 months.¹²⁻¹⁴

The immunohistochemical data showed that the myometrium had a significant greater microvascular density than a small or large fibroid.⁷ Farrer-Brown et al reported greater average vascular diameter in myometrium than in fibroid. Nandita et al reported that at 4 months after bilateral UAE, myometrium perfusion had returned to normal whereas fibroid perfusion suppressed.

Burn et al reported poor response in patients with fibroid of high signal on T1W before UAE. We found that intermediate-high SI on T1W had 41.1% volume reduction and that of hypo- and isointensity were 34.5 % and 31.8 %. The intramural fibroids had greater volume reduction (44.5 %) than those of submucosal and subserosal lesions (28 % and 25 %). James et al reported that submucosal location and a high correlation with size reduction.

Post-UAE fibroids also showed signal change. In this study there were 19 fibroid (73.1 %) increased signal intensity on T1-weighted with 45.2% of volume reduction. 7 fibroids (26.9%) with no significant signal intensity change after UAE showed 17.9 % volume reduction. The increased signal intensity on T1W in post-UAE is consistent with **hemorrhagic infarction**. Treated fibroids typically show more homogenous dark signal on T2W and diminished vascularity.

All of our 8 patients are satisfied with treatment. Abnormal uterine bleeding and dysmenorrheal are significant improved in 3 of 4 patients. Bulk-related symptoms are also improved in post-UAE of all 3 pts. Worthington-Kirsch et al reported 46 of 52 pts (88%) with marked improvement of abnormal uterine bleeding, 29/31 pts (94%) with substantial improvement of bulk-related symptoms and 90 % of pts returned to normal activity within 10 days. The mean time for resolution of all postprocedural symptoms was 13 days. 79% of pts would choose this procedure again.

CONCLUSION

This study reveals significant volume

reduction of fibroid after bilateral uterine artery embolization for treatment of fibroid with good clinical outcomes. We suggest that UAE is an effective and safe alternative treatment for uterine fibroid.

REFERENCES

1. Cramer SF, Patel A. The frequency of uterine leiomyomas. *Am J Clin Pathol* 1990; 94: 435-438.
2. Baird DD, Dunson DB, Hill Mc et al. High cumulative incidence of uterine leiomyoma in black and white women: Ultrasound evidence. *Obstet Gynecol* 2003; 188: 100-107.
3. Wilcox LS, Koonin LM, Pobras R, et al. Hysterectomy in the united states, 1998-1990. *Obstet Gynecol* 1994; 83: 549-555.
4. Burn p, McCall JM, Chinn r, et al. Embolization of uterine fibroids. *Br J Radiol* 1999; 72: 159-161
5. Jha RC, Ascher SM, Imaoka I et al. Symptomatic fibroleiomyomata: MR imaging of the uterus before and after uterine embolization. *Radiology* 2000; 217: 228-231.
6. Tetsuya Katsumori, Kazuhiro Nakajima, et al. Is large fibroid a high risk factor for uterine artery embolization. *AJR*; 2003; 181: 1309-1314
7. Nandita M. deSouza et al. Uterine arterial embolization for leiomyomas: Perfusion and volume change at MR imaging and relation to clinical outcome. *Radiology*; Feb 2002: 365-373
8. Casey R, Rogers PA, Vollenhoven BJ. An immunohistochemical analysis of fibroid vasculature. *Hum Reprod* 2000; 15: 1469-1475
9. Pelage JP, Le Dref O, Soyer P, et al. Fibroid-related menorrhagia: treatment with superselective embolization of the uterine arteries and midterm follow up. *Radiology* 200; 215: 428-431
10. James B. Spies, Jean -Pierre Pelage. Uterine artery embolization and syncologic embolotherapy 2004; 6-7, 41-45
11. Walker WJ, Pelage JP. Uterine artery embolization for symptomatic fibroids: clinical results in 400 women with imaging follow up. *BJOG* 2002; 109: 1262-1272
12. Worthington-Kirsch RL, Popky GL, Hutchins FL Jr. Uterine arterial embolization for the management of leiomyomas, quality of life assessment and clinical response. *Radiology* 1998; 208: 625-629
13. Molly T., Johanna L., et al. Cost-effectiveness of uterine artery embolization and hysterectomy for uterine fibroids. *Radiology* 2004; 230: 207-212
14. Haney AF. Clinical decision making regarding leiomyomata; what we need in the next millennium. *Environ Health Perspect* 2000; 108: 835-839