
ULTRASOUND OF FOREIGN BODY (PADDY) IN VAGINA OF A GIRL OF 2 YEARS.

Dr. M. A. Taher,¹

A girl 2 years of age, jumped on a stack of paddy and started crying due to accidental insertion of paddy into her vagina. Her mother tried to pull it out by her finger, but it did not come out, rather impacted further upwards. Abdominal ultrasound could locate the paddy through the full urinary bladder (Fig. 1). It was pulled out in the hospital under general anesthesia (GA), to avoid the risk of sloughing by the sharp corners of the paddy resulting in vesicovaginal fistula (VVF).

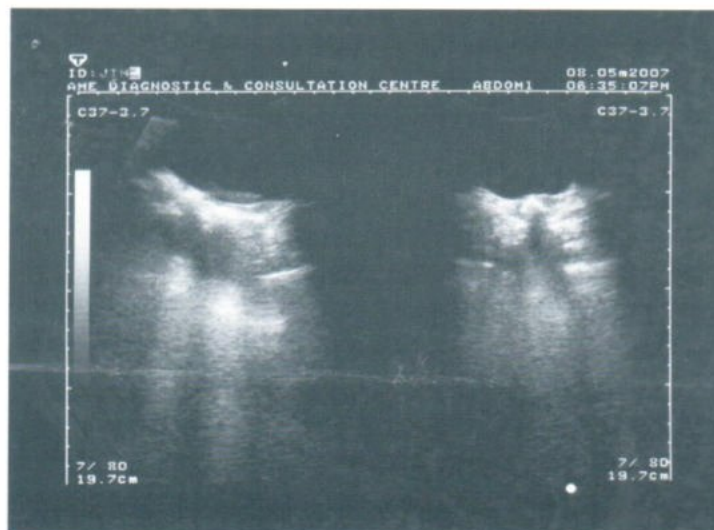


Fig. 1 Paddy Vagina

¹ Director, Centre for Nuclear Medicine & Ultrasound, Rangpur, Bangladesh