
REVERSING SIGN ON COMPUTED TOMOGRAPHY OF HYPOXIC ISCHEMIC CEREBRAL INJURY IN TWO CHILDREN.

Chanya CHAISIRAT M.D.¹

ABSTRACT

An anoxic ischemic cerebral injury may cause a variety of neuropathologic abnormalities, which depend on the age of onset, duration and intensity. Reversing sign is an uncommon radiological finding on computed tomography. It is seen mainly in cases of severe pediatric hypoxia.

The purpose of this study was to present and describe the reversing sign on computed tomography of two cases of hypoxic children.

We reviewed the clinical features, etiologies, outcome and the reversal sign on computed tomography in two interested children. They have severe developmental delay due to prolonged hypoxia in different ages at the time of on set, the one was birth asphyxia and the other was cardiopulmonary arrest after seizures. They were underwent computed tomographic examination next 1-2 months after the anoxic events to evaluate the outcome.

The reversing signs on computed tomography of our two pediatric cases were defined by reversal of the normal gray and white matter density, a relative increase density of preserved thalami, brain stem and cerebellum, some decrease volume of the white matter mantle and some ventricular dilatation. The different degrees of the decrease cerebral density, white matter volume loss and atrophic ventricular enlargement were observed. They represented various degrees of periventricular leukomalacia and cystic encephalomalacia on chronic state.

As our result and reviewed relevant literatures, we presumed that the reversing sign is an uncommon classic computed tomographic findings which are divided into acute, intermediate and chronic reversing groups. They occur following diffuse anoxic ischemic injury in any age groups. It usually represents severe brain injury, irreversible brain damage and carries a poor outcome.

Key Words: Reversing sign, computed tomography, hypoxic ischemic encephalopathy (HIE).

INTRODUCTION

If cerebral circulation is interrupted for several seconds or longer, brain oxygen is rapidly depleted. Following successful resuscitation, complete

recovery may occur, however in other cases, cerebral hypoxia causes edema, ischemic and hypoxic ischemic encephalopathy.¹

¹ Department of radiology, Kamphaengphet Hospital, Kamphaengphet 62000, Thailand

An anoxic ischemic insult may cause a variety of neuropathologic abnormalities, including neuronal necrosis, marmoration of basal ganglia and thalami, watershed infarction, parasagittal cerebral injury, periventricular leukomalacia, focal and multifocal ischemic brain necrosis.^{2,5} The pattern of neuropathologic alteration depends on the patient's age at the time of insult and the duration of the anoxic episode.³

When cerebral blood flow was interrupted completely, a small percentage of patients who suffer a global cerebral hypoxic ischemic injury develop distinctive computed tomography finding which termed as a reversal sign.

In the past and until now, CT still has been utilized in detection of the neuropathologic changes in patient who survived from this episode particularly in the rural hospital where MRI is not available.

The reversal sign expressed (1) just diffusely decreased density of cerebral cortical gray and white matter with reduced or lost gray, white matter differentiation or (2) less frequently, reversal of the normal gray white matter density. The density of thalami, brainstem and cerebellum were usually preserved and relatively increased in density.^{4,5,6,12,14}

Reversal sign on computed tomography is seen mainly in cases of pediatric hypoxia. However, now the reversal sign has been described for adult who has prolonged anoxic ischemic injury in scattered literatures.^{6,8}

The reversal sign has been described for anoxic ischemic states due to variety of causes, including birth asphyxia, drowning, status epilepticus, meningitis, and degenerative encephalitis.^{5,6,9} It can occur following other causes such as child abuse, cardiac arrest, electrocution and accidental injury.^{5,6,9} This sign has been mainly seen as either an early sign or sequel of hypoxic ischemic insult.

The aim of this report was to show the two

classic reversal signs on computed tomography, which resulted from prolonged hypoxic ischemic cerebral injury of two pediatric cases who presented CT appearance as chronic reversal signs. We also discussed the clinical features, etiologies and outcome; and also reviewed the relevant literature.

MATERIALS AND METHODS

We retrospectively analyzed the clinical features and the reversal sign on computed tomography images of two hypoxic children who have severe developmental delay, one was due to birth asphyxia and the other was due to cardiopulmonary arrest. We reviewed its possible causes, and also discussed the relevant literatures.

Patient 1, A 6 month-old child born at 37 weeks gestational age by C/S. He was healthy term infant and had normal Apgar Scores at birth ~ 9, 10 and 10 in 1, 5 and 10 minutes, respectively. Next 6 months later, he was brought to emergency services with unconscious after seizures, he was EIVIM1 and then he rapidly developed cardiopulmonary arrest. On arrival at the hospital he had no detectable pulse and respiration. On examination the child was comatose, cyanosis and unresponsive to noxious stimuli. Few minutes after cardiopulmonary arrest, an emergency nasotracheal intubation was performed and mechanical ventilation was initiated.

The initial computed tomography was obtained 2 hours after resuscitation. There were small right frontal intracerebral hematoma and chronic bilateral frontal convexity subdural hemorrhage (not shown).

He was referred to intensive care unit for conservative treatment, after unsuccessful cardiopulmonary resuscitation. After that, he has survived but developed clinical signs of cerebral hypoxia including spastic diplegia and seizures.

Follow up 2 months non-contrast computed

tomography after the anoxic event demonstrated diffusely decreased density of gray matter and striking increased density of white matter, it was reversal of the normal gray and white matter densities. There were slightly decrease amount of white matter mantle and mildly dilated all ventricles. Relatively increased density of the preserved thalami, brainstem and cerebellum were detected. All findings are typical features of chronic reversal sign (Fig.1 A-D). Bilateral chronic subdural hemorrhages were also detected.

Patient 2, A 2 month-old child, who had prior history of 38 weeks term infant, severe fetal distress and birth asphyxia is presented. The infant had low Apgar Scores at birth ~ 2, 4 and 5 in 1, 5 and 10 minutes, respectively. He required resuscitation and ventilatory assistance at birth. After that, he developed hypoglycemia and seizures. For long term, he survived. The clinical sign of hypoxic ischemic

encephalopathy (HIE) were detected as major motor disabilities, including spastic diplegia, abnormal neuromuscular tone and reflexes. Seizures, altered consciousness and developmental delay were also observed.

One month after birth, initial plain computed tomography was performed to evaluate the clinical prognosis. His plain computed tomography scans demonstrated reversal of normal gray and white matter density which were seen as generalized CSF like hypodensity throughout the cerebral gray matter representing cystic encephalomalacia. Volume of white matter is markedly decreased, and accompanying reversal increase white matter density is seen. Relative hyperdensity are seen in thalami, brainstem and cerebellum. All findings are characteristic CT appearance of chronic form of reversal sign (Fig.2 A-D).

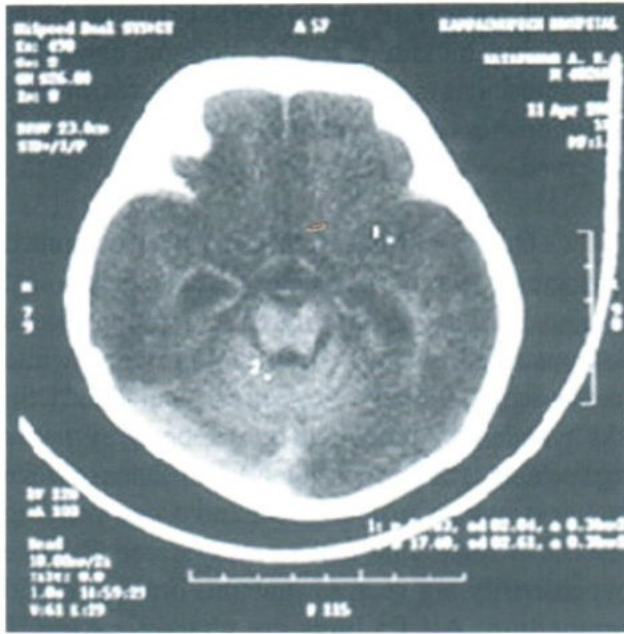


Fig. 1A

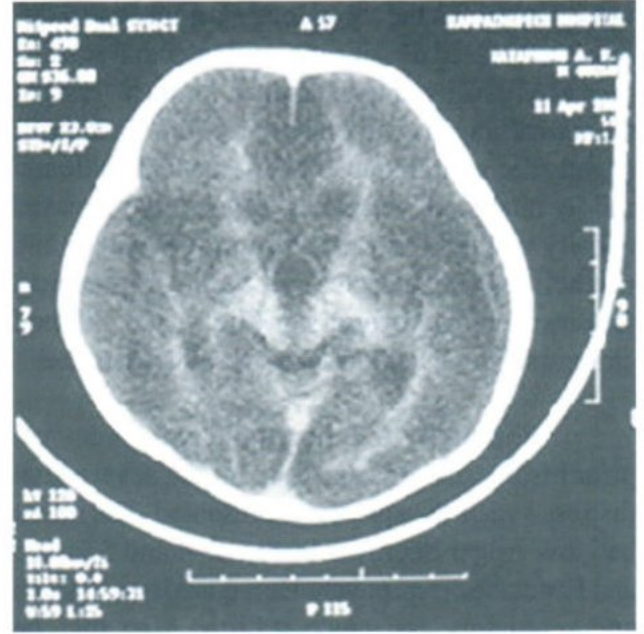


Fig. 1B

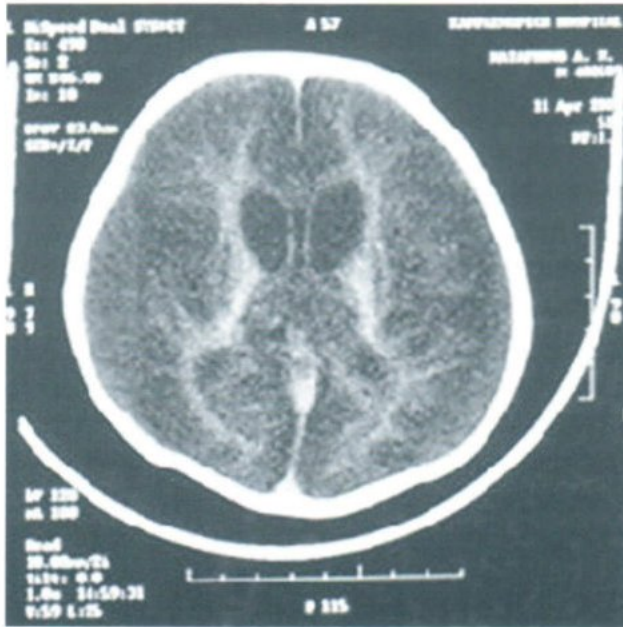


Fig. 1C

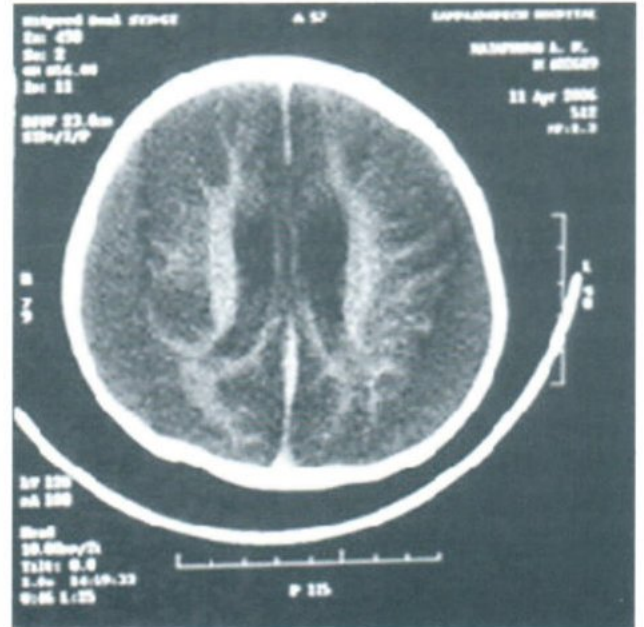


Fig. 1D

Fig.1 A-D Chronic reversal sign in 8 month-old child with history of post resuscitation for 2 months, secondary to cardiopulmonary arrest.

Plain CT scans reveal decrease density of cortical gray matter and increase density of subcortical white matter, causing reversal of the normal gray and white matter densities, some decrease amount of white

matter is seen. Relative increase density of thalami, brainstem and cerebellum are observed. All ventricles are mildly dilated.

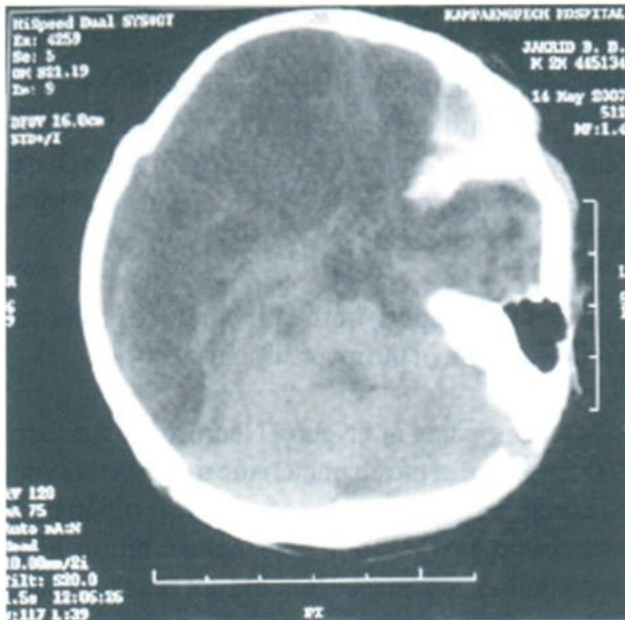


Fig. 2 A

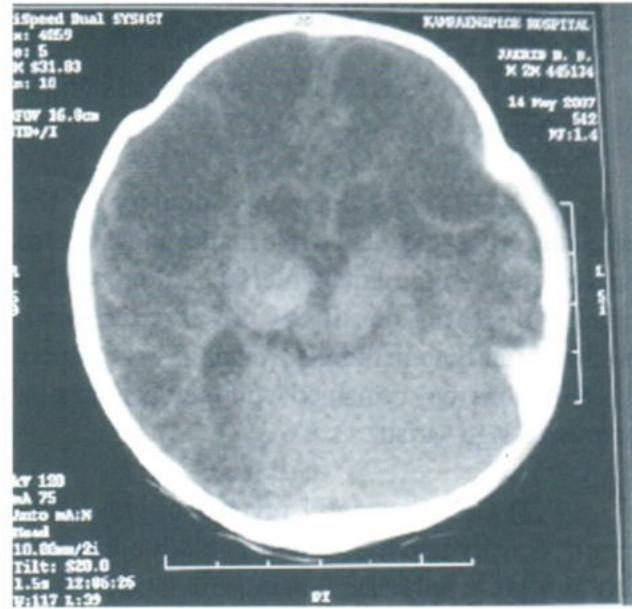


Fig. 2 B

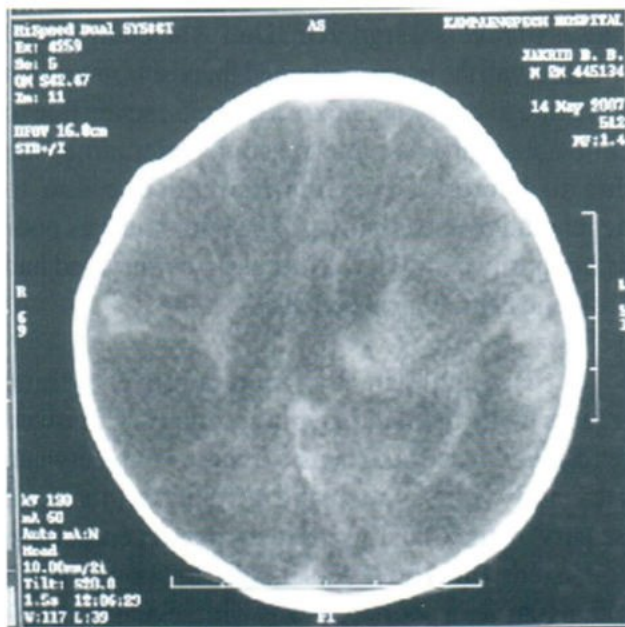


Fig. 2C

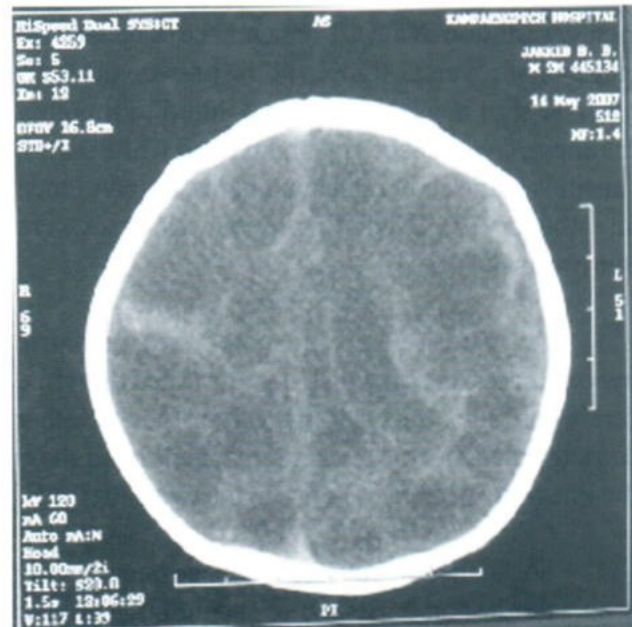


Fig. 2D

Fig.2 A-D Chronic reversal sign in 2 month-old child with previous history of fetal distress and severe birth asphyxia

Plain axial CT show generalized CSF like hypodensity throughout both cerebral hemisphere representing cystic encephalomalacia, increase density of subcortical white matter, reversal of normal gray

white matter density. Markedly decreased volume of white matter and all ventricular dilatation are seen. Relative hyperdensity is seen in thalami, brain stem and cerebellum.

DISCUSSION

In several recent studies, the reversal sign has been described by;

(1) Diffusely decreased density of the cerebral cortical gray and white matter and decrease or lost gray white matter interface, along with a relative increased density of preserved thalami, brainstem and cerebellum, however in some papers these findings may be named white cerebellum sign or reversal sign variant.

(2) Less frequently, reversal of gray white matter density and associated a relative increase density of preserved thalami, brainstem and cerebellum, these findings may be named true reversal sign.

Some texts and literatures are confusing in their description of the CT appearance of these two patterns of reversal sign. In some papers, the term reversal sign has been mainly limited to imaging findings of reversal of gray matter and white matter densities of the cerebral hemispheres, as mentioned on category (2). CT findings of our two cases were true reversal signs.¹²

S. Moosa et al. presented two pediatric hypoxic cases, one of which demonstrated the white cerebellum sign, (reversal sign variant) and the other demonstrated the true reversal sign, in order to show the imaging differences between the two patterns.¹²

Actually, the reversal sign has been mainly seen as either an early sign or sequel of hypoxic ischemic insult, its recognition may be early or delayed. B. Kim Han et al. divided CT findings of reversal sign into three groups, including (1) acute within 24 hours at presentation, (2) intermediate, 2-22 days and (3) chronic reversal sign.⁵

In chronic reversal group, associated atrophic brain, atrophic ventricular enlargement and/or cystic encephalomalacia were detected and the

attenuation of the cerebral mantle is visually lower than in patient with acute reversal group, and it has a density similar to that of CSF, whereas in acute phase, there are small compressed ventricles secondary to diffuse cerebral edema.

In our report, both of them were presented as chronic form of the reversal signs.

One paper in *J Neurol Neurosurg Psychiatry* 2000 reported acute characteristic true reversal sign on computed tomography of a 70 year old man; it was found just 1 hour post resuscitation after cardiopulmonary arrest. He could not be resuscitated and was declared brain dead, one hour later.⁸

By reviewed literatures, there are numerous causes of reversal sign. Kim Han et al. analyzed 20 children with the reversal sign and found that nine cases were due to hypoxia/anoxia incidents, seven due to child abuse, and two due to accidental trauma, one due to bacterial encephalitis and one due to degenerative encephalitis.⁵ The outcome was poor as a majority expired, while those who survived had profound neurological deficits.⁵

H. Schulman et al. reported seven of nine infants with neonatal hypothermia, CT showed reversal of the normal density relationship between grey and white matter and a relative increased density of the thalami, brainstem and cerebellum consistent with the reversal sign. In six surviving infants carries a poor prognosis with severe developmental delay.⁷

We found that the reversal sign was seen mainly in cases of pediatric hypoxia but there are scattered reports describing in adult with severe anoxic ischemic injury. G. Vergote et al. reported a 36-year-old woman with bacterial meningitis. CT after resuscitation showed a striking reversal sign, it indicates serious brain damage and carries a poor

outcome.¹⁵

B. Nail et al. retrospectively examined the computed tomography of 9 adult patients in vegetative state due to prolonged anoxia, range of age 21-67 years and they thought that the reversal sign was a characteristic finding of the ischemic vegetative state of the adult brain.⁶

Cho Jey Min et al. evaluated prognosis-related CT findings in 28 children with a clinical history and CT findings suggestive of hypoxic ischemic encephalopathy (HIE). They found that the CT appearances including poor differentiation of gray and white matter, reversal sign, obliteration of perimesencephalic cistern, high density on tentorial edge indicate severe anoxic ischemic brain injury and carries a poor prognosis.¹³ Because of CT findings showed distinct differences between groups in whom prognosis was good, and in whom it was poor. An awareness of poor prognostic, CT findings may be clinically helpful in the evaluation of patients with hypoxic ischemic cerebral injury.¹³

CONCLUSION

As a result, our study confirmed that the pattern of brain injury from prolonged hypoxic ischemic insult in neonates differed from that seen in children after the neonatal period.

The reversal sign is a classic uncommon characteristic radiological finding, secondary to hypoxic ischemic cerebral injury and can occur in any age.

The reversal sign has been mainly seen as either an early sign or sequel of hypoxic ischemic insult, dividing into acute, intermediate and chronic reversal signs.

There are numerous causes of the reversal sign, including (1) severe hypoxia particularly birth asphyxia, cardiac arrest, drowning, status epilepticus

(2) trauma such as abused child, less frequently accidental injury (3) infection especially meningitis and degenerative encephalitis (4) others such as electrocution, smoke inhalation and neonatal hypothermia.

Reversal sign usually represents severe hypoxic ischemic brain injury, also indicates irreversible devastating brain damage and carries a poor prognosis. The prognosis and outcome for reversal sign were poor as a majority expired, while those who survived had profound neurological deficit and permanent impairment.

An awareness of poor outcome, CT is the most useful modality and has been use as the primary imaging method to evaluate the prognosis of patient with anoxic ischemic cerebral injury.

ACKNOWLEDGEMENT

The author acknowledges Dr. Kamchai Rangsimunpaiboon, the chief of Kamphaengphet provincial Hospital, for his supports, and also acknowledges pediatric attending clinicians who gave me the patient details and useful comments.

The author would like to thank Mrs. Jiraporn Maneeprai for her help with this project about reference papers, patient's profiles and manuscript preparation.

REFERENCES

1. Leon Weisberg, Charles Nice. Cerebral computed Tomography: Cerebral Anoxi and Brain Death. A Text Atlas, 3rd Edn, 1989 : 272-273
2. R.G. Grainger, D.J. Allison, A. Adam, A.K. Dixon. Diagnostic Radiology A Textbook of Medical Imaging, Fourth Edn, Chapter Elsevir, 2001. p. 2472.
3. S. Haward Lee, Krishna C.V.G. Rao, Robert A. Zimmerman. Atrophy secondary to anoxia. Cranial MRI and CT, third Edn, 1992: 277-281.

4. Osborn AG. Craniocerebral Trauma: In Osborn AG (editor) *Diagnostic Neuroradiology*, 1st Edn, Chapter: Elsevier; 1994. p. 199-247.
5. Han BK, Towbin RB, De Courten-Myers G, McLaurin RL, Ball WS Jr. Reversal sign in CT: Effect of Anoxia / Ischemic cerebral injury in children. *AJR* 1990; Feb 154:361-8.
6. B. Nail, P. Yuksel, K.H. Kermal, T. Cem. T. Mustafa, U. Taner. Result of Acute Cerebral Anoxia in Adults: is it a reversal sign. *Turk J Med Sci* 2000; 571-577.
7. H. Schulman, L. Laufer, Julia Berginer, E. Hershkowitz, Tamar Berenstein, Shaul Sofer, Esther Maor, Yancu Hertzanu. CT findings in neonatal hypothermia. *Paediatric Radiology* 1998; June 28; 6: 414-417
8. Reversal sign after cardiopulmonary arrest. *J Neuron Neurosurg Psychiatry* 2000; April 68: 525
9. Cohen RA, Kaufman RA, Myers PA, Towbin RB. Cranial Computed Tomography in the Abused Child with Head Injury. *AJNR* 1985; 6: 883-8
10. Dwarakanath S, Bansal A, Rudrappa S, Gopal S, Venkataramana NK. White cerebellum sign-A case report and review of literature. *Journal of Paediatric Neurosciences* 2006; 1: 322-23.
11. A.-C. Duhaime, C. W. Christian, L. B. Rorke, and R. A. Zimmerman Nonaccidental Head Injury in Infants -- The "Shaken-Baby Syndrome" *N. Engl. J. Med.*, June 18, 1998; 338(25): 1822-1829.
12. S. Moosa, S. Andronikou. Case Report: Hypoxic-ischaemic injury-the 'white cerebellum sign' versus the true 'reversal sign'. *South African Journal of Radiology* Vol.9(1) 2005: 32-33
13. Cho Jay Min, Kim OH, Kang DK, Suh JH, Il YB. Hypoxic Ischemic Encephalopathy in Children: CT Findings Related to Prognosis. *J Korean Radiol Soc.* 1997 Jul; 37(1):167-172. Korean.
14. (2006) *Medcyclopaedia*. Pediatric imaging: Reversal sign. GE healthcare Medical diagnosis. Medcyclopaedia.com.
15. G. Vergote, H. Vandepierre and R. de Man. The reversal sign. *Neuroradiology* 1992 ; 34: 215-216