

Original Article

The preoperative factors associated with underestimation of invasive breast cancer in stereotactic vacuum-assisted biopsy-diagnosed DCIS patients

Somchanin Pipatpajong, M.D. ⁽¹⁾

Rachata Tangkulboriboon, M.D. ⁽²⁾

From ⁽¹⁾Department of Radiology, Faculty of Medicine, Chulalongkorn University, Bangkok, Thailand.

⁽²⁾Department of Radiology, King Chulalongkorn Memorial Hospital, The Thai Red Cross Society, Bangkok, Thailand.

Address correspondence to S.P. (e-mail: somchanin.p@chula.ac.th)

Received 22 April 2023; revised 2 July 2023; accepted 2 July 2023
doi:10.46475/aseanjr.v24i2.778

Abstract

Objective: To determine preoperative factors associated with underestimation of invasive breast cancer, where stereotactic vacuum-assisted biopsy (VAB) diagnosed as ductal carcinoma in situ (DCIS).

Materials and Methods: Data from 95 patients diagnosed with DCIS by stereotactic VAB, including their clinical, radiological, and pathological findings between November 2010 and May 2021, were analyzed retrospectively. The clinical, radiological, and pathological features were analyzed.

Results: The underestimation rate was 30.5 %. Three preoperative features were significantly associated with the underestimation of invasive breast cancer in multivariable analysis, including palpability (OR, 11.51; 95% CI: 1.817-72.897;

P = 0.009), BI-RADS category (OR, 3.705; 95% CI: 1.214-11.303; P = 0.021), and visibility of a mammographically detected lesion at ultrasonography (OR, 7.115; 95% CI: 1.977-25.611; P = 0.003). The calcification morphology was statistically significant in an univariable analysis but not in a multivariable analysis.

Conclusion: Preoperative variables significantly associated with underdiagnosis of invasive breast cancer, including palpability, BI-RADS category, and visibility of mammographically detected lesions at ultrasonography, could aid in assessing the risk of developing invasive breast cancer and conducting treatment selection.

Keywords: Breast cancer, Ductal carcinoma in situ, Stereotactic vacuum-assisted biopsy, Underestimation.

Introduction

Ductal carcinoma in situ (DCIS) of the breast is a pathological entity where malignant cells originate from and line within the breast ducts without evidence of invasion. This entity is a non-obligate precursor of invasive breast cancer. Three-fourths of patients with DCIS lesions presented with breast calcifications. Up to 23 percent had a breast mass or asymmetry, and roughly 12 percent were associated with a palpable abnormality [1]. The standard treatment for patients with a biopsy-confirmed diagnosis of DCIS is lumpectomy with radiation or total mastectomy. A sentinel lymph node biopsy (SLNB) should be considered for mastectomy or lumpectomy, of which the anatomic location likely compromises the performance of a future SNLB [2].

Diagnosis of DCIS by biopsy potentially leads to an underestimate of invasive breast cancer in subsequent surgical excision. The reported underestimation rates varied from 14.1-42.7 percent [3-7]. The one from a meta-analysis was 25.9 percent (95% confidence interval (CI): 22.5-29.5), indicating the considerable number of patients with invasive breast cancer being undertreated [3].

Several studies have sought to identify factors associated with DCIS lesion upstaging to invasive cancer following surgical excision [3-7]. The most frequently reported risk factors for underestimation were palpability, histologic grading, biopsy device, and some radiological features, e.g., lesion size, mass on mammogram or ultrasonogram, and the Breast Imaging Reporting and Data System (BI-RADS) score. However, there is a paucity of reported data on radiological features which composed BI-RADS scores.

The gold standard procedure for tissue diagnosis is excisional biopsy. This procedure is generally costly and associated with morbidity, so other less invasive interventions should be considered [8,9]. Vacuum-assisted biopsy (VAB) is an alternative intervention to obtain some tissue of mammographically detected lesions, especially microcalcifications. The VAB procedure was considered safe and cost-effective compared to the surgical biopsy. VAB also provided high-quality specimens and low rates of false-negative results [8,9]. The reported underestimation rate for VAB was 6.1-29.0 percent [8-13].

Our study aimed to identify the preoperative factors associated with underestimated invasive breast cancer and estimate the extent of this underestimation at King Chulalongkorn Memorial Hospital.

Materials and methods

Patient

The King Chulalongkorn Memorial Hospital institutional review board, has approved the study and waived the informed consent process.

We used data from the hospital systems of King Chulalongkorn Memorial Hospital, including the Hospital Information System (HIS), the Radiological Information System (RIS), and the Picture Archiving and Communication System (PACS). A total of 136 female patients had been diagnosed with any subtype of

DCIS by VAB. It subsequently underwent breast surgery of either wide excision or mastectomy, irrespective of sentinel lymph node biopsy (SLNB) at the hospital on 1 November 2010 and 31 May 2021, were identified. Of those patients, 41 patients were excluded due to the following criteria- unavailable or inconclusive pathological data [22], multifocal or multicentric DCIS by VAB [13], and the longer-than-90-day interval between biopsy and surgery [3] and between mammography and biopsy [2]. Thus, 95 patients (mean age \pm standard deviation, 53.9 ± 10.9) were included in the study (Figure 1). Clinical data with radiological and pathological findings were then collected and reviewed (Table 1).

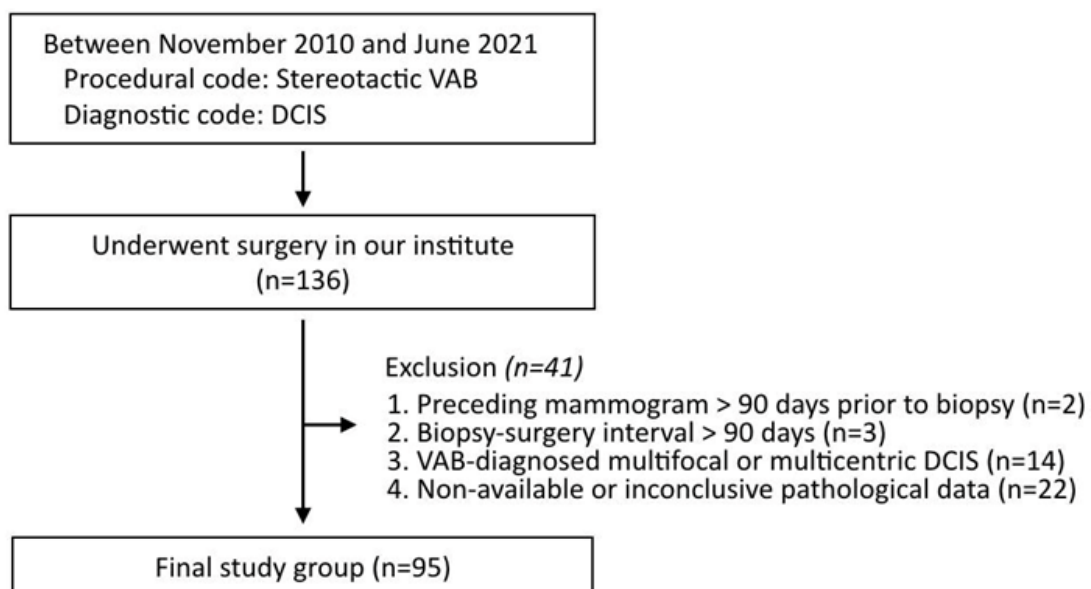


Figure 1. Flowchart of patient selection.

The radiologists performed stereotactic VABs, using either a 9- or 10-gauge vacuum-assisted device (Mammotome; Ethicon-Endosurgery, Cincinnati, OH). Patients with a longer-than-90-day interval between mammography and biopsy, VAB-diagnosed multifocal or multicentric DCIS, and unavailable or inconclusive pathological data were excluded.

Table 1. *Data collection.*

Clinical data	Radiological findings	Histological findings
Age	Morphology	DCIS,
Presentations	Distribution	DCIS with microinvasion
Mass characteristics	Amount of calcification	Invasive breast cancer
Previous history of breast cancer	Presence of mass	DCIS grading
	Architectural distortion	
	Asymmetry	
	Skin Retraction	
	Nipple retraction	
	Axillary lymphadenopathy	
	Ultrasonographic visibility	
	BI-RADS score	

The underestimated invasive breast cancer was defined as identifying the invasive part in subsequent surgical excision. Microinvasive carcinoma was defined as any foci of cancer cells sized in 1 millimeter or less infiltrating into the stroma. This microinvasion subtype was not classified as an underestimation as it was treated the same as others with pure DCIS [2, 14].

Two researchers independently reviewed the imaging findings. All clinical and histopathological data were blinded during the review to prevent bias. In case of disagreement between the two researchers, a consensus was made.

Statistical analysis

All variables were compared between the non-underestimation and underestimation groups, using Pearson's Chi-square or Fisher's exact test for categorical variables and Student's t-test for continuous ones.

Univariate analyses were initially performed to identify determinants of the underestimation. The statistically significant variables (P-value of less than 0.05) in

the univariate analyses were then included in the multivariate analysis. Backward stepwise regression was used to gradually eliminate variables from the regression model to find a reduced model that best explains the data. All statistical analyses were performed using SPSS Statistics version 22.0 (IBM, Armonk, NY). P-values of less than 0.05 was considered statistically significant.

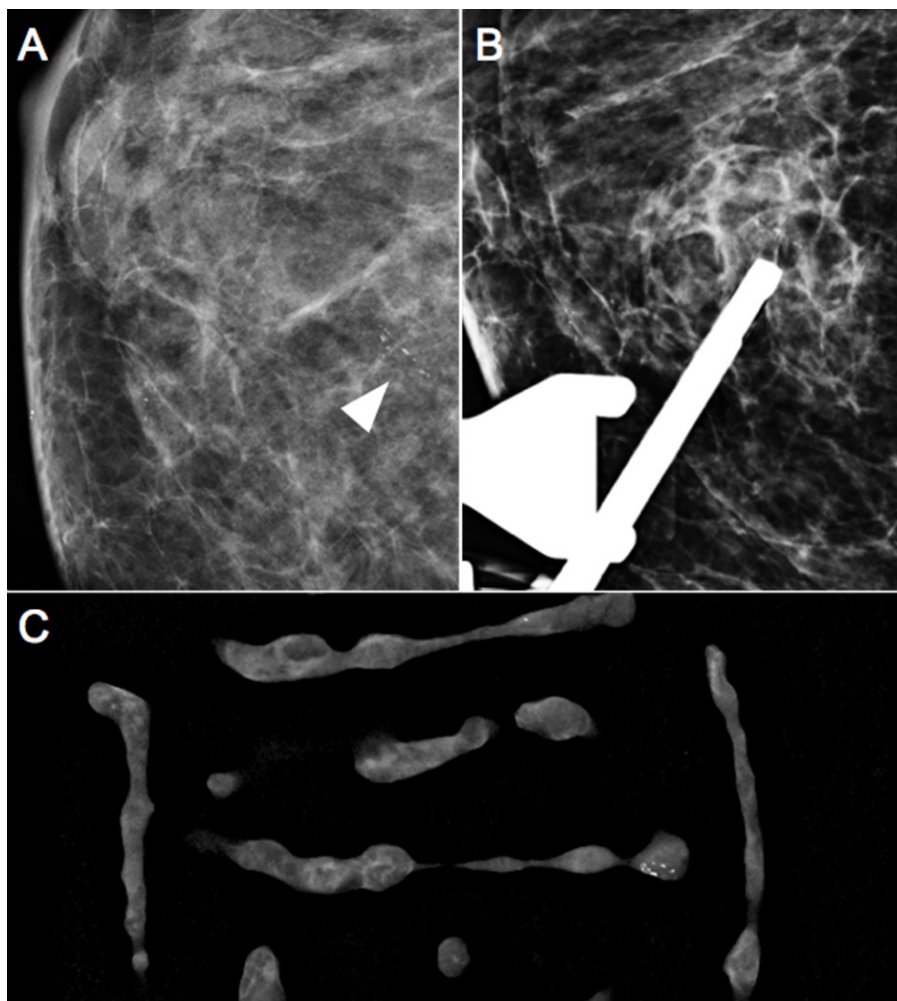


Figure 1. Screening mammogram (A) of a 68-year-old patient shows fine-linear microcalcifications in a linear distribution at the right central region: pre-biopsy image (B) and specimengraphy (C) obtained during stereotactic 9G VAB. High-grade DCIS was identified on pathology. Following that, a wide excision was performed, and histology confirmed IDC.

Results

Patient characteristic

The baseline characteristics are summarized in Table 2. Twenty-nine of 95 patients with VAB-diagnosed DCIS had invasive breast cancer on the surgical excision and were included in the underestimated group, accounting for 30.5% of the underestimation rate. Almost all patients in this underestimated group were diagnosed with DCIS with invasive ductal carcinoma at the excision pathology, except the only patient diagnosed with DCIS with invasive lobular carcinoma. Sixty-six patients were included in the non-underestimated group, 62 with pure DCIS and 4 with DCIS with microinvasion, which was also included in the non-underestimated group because the treatment and follow-up were the same as pure DCIS.

Of the 95 DCIS diagnoses at stereotactic VAB, there are 79 (83.2%) with screening mammograms, 16 (16.8%) with symptoms, 9 (9.5%) with a palpable lesion, and 20 (21.1%) with history of breast cancer. Most tissue pathology from stereotactic VAB was DCIS with intermediate grade (55.8%) and not specified (24.2%). The collection of the comedo subtype was initially intended; however, the majority of pathological reports did not include information on the comedo subtype. As a result, the comedo subtype is not reported in this article. Following the biopsies, 71 DCIS patients (74.7%) underwent surgical excision without SLNB. Of the underestimated group, 20 (69.0%) underwent surgical excision without SLNB.

Table 2. Baseline patient characteristics in the included patients.

Baseline characteristic	All (n = 95)	Underestimated invasive breast cancer		P value
		No (n = 66)	Yes (n = 29)	
Age (y)*	53.93±10.9 (33-76)	54.0±10.8 (33-76)	53.7±10.9 (35-75)	0.470
Age categories				0.275
< 45	21 (22.1)	13 (19.7)	8 (27.6)	
≥ 45	74 (77.9)	53 (80.3)	21 (72.4)	
Presentation				0.063
Screening	79 (83.2)	58 (87.9)	21 (72.4)	
Symptoms	16 (16.8)	8 (12.1)	8 (27.6)	
Palpability				0.003
No	86 (90.5)	64 (97.0)	22 (75.9)	
Yes	9 (9.5)	2 (3.0)	7 (24.1)	
History of breast cancer				0.407
No	75 (78.9)	53 (80.3)	22 (75.9)	
Yes	20 (21.1)	13 (19.7)	7 (24.1)	
Grade at VAB				0.816
Low	13 (13.7)	9 (13.6)	4 (13.8)	
Intermediate	53 (55.8)	33 (50.0)	20 (69.0)	
High	11 (11.6)	8 (12.1)	3 (10.3)	
Not specified	23 (24.2)	16 (24.2)	7 (24.1)	
Type of surgery				0.239
Wide excision	40 (42.1)	32 (48.5)	8 (27.6)	
Wide excision with SLND	3 (3.2)	2 (3.0)	1 (3.4)	
Mastectomy	31 (32.6)	19 (28.8)	12 (41.4)	
Mastectomy with SLND	21 (22.1)	13 (19.7)	8 (27.6)	

Data are means ± standard deviations.

Radiographic features

Table 3 shows the radiologic findings of all DCIS patients. All of them had any suspicious morphology of calcification, of which the majority were non-linear (86.3%). Grouped calcification was the most common, followed by segmental and linear calcification. This sequence of the distribution was indifferent between the non-underestimated and underestimated groups. Other radiological findings were rarely discovered, including architectural distortion (3.2%), focal asymmetry (2.1%), skin retraction (1.1%), nipple retraction (1.1%), and axillary lymphadenopathy (1.1%). In addition, mass, skin thickening, or trabecular thickening were radiologically undetected. The distribution of the BI-RADS category was 4.2% BI-RADS 4a, 47.4% BI-RADS 4b, 38.9% BI-RADS 4c, and 9.5% BI-RADS 5. 18 (18.9%) of all DCIS patients had visibility of the lesion at ultrasonography. The DCIS patients were equally concentrated between the BI-RADS 4A/4B and 4C/5. The BI-RADS distribution was different between the two groups; the non-underestimated group was likely to have a result of BIRADS 4A/4B, whereas the other group was otherwise. Any lesions were ultrasonographically visible in 18 DCIS patients (18.9%). The differences in calcification morphology, BI-RADS, and ultrasonographic visibility between the two groups were significant.

The features with the rate of the most significant difference in the underestimated group compared with the rate in the non-underestimated group were palpable lesion, fine linear/fine-linear branching calcification, BI-RADS 4c and 5, and visibility of the lesion at the US.

Table 3. Radiographic features.

Radiographic features	All (n = 95)	Underestimated invasive breast cancer		P value
		No (n = 66)	Yes (n = 29)	
Mass				
No	95 (100.0)	66 (100.0)	29 (100.0)	
Yes	0	0	0	
Morphology of calcification 0.002				
Non-linear group	82 (86.3)	62 (93.9)	20 (69.0)	
Fine linear/ fine-linear branching	79 (83.2)	58 (87.9)	21 (72.4)	
	13 (13.7)	4 (6.1)	9 (34.6)	
Distribution of calcification 0.120				
Diffuse	0	0	0	
Regional	0	0	0	
Grouped	66 (69.5)	49 (74.2)	17 (58.6)	
Linear	10 (10.5)	5 (7.6)	5 (17.2)	
Segmental	19 (20.0)	12 (18.2)	7 (24.1)	
Amount of calcification 0.173				
No comparison	45 (47.3)	31 (47.0)	14 (48.3)	
Newly developed	20 (21.1)	11 (16.7)	9 (34.6)	
Increased amount	30 (31.6)	24 (36.3)	6 (20.7)	
Architectural distortion 0.669				
No	92 (96.8)	64 (97.0)	28 (96.6)	
Yes	3 (3.2)	2 (3.0)	1 (3.4)	
Asymmetry 0.520				
None	93 (97.9)	65 (98.5)	28 (96.6)	
Asymmetry	0	0	0	
Global	0	0	0	
Focal	2 (2.1)	1 (1.5)	1 (3.4)	
Developing asymmetry	0	0	0	
Skin retraction 0.0695				
No	94 (98.9)	65 (98.5)	29 (100.0)	
Yes	1 (1.1)	1 (1.5)	0	
Nipple retraction 0.305				
No	94 (98.9)	66 (100.0)	28 (96.6)	
Yes	1 (1.1)	0	1 (3.4)	

Radiographic features	All (n = 95)	Underestimated invasive breast cancer		P value
		No (n = 66)	Yes (n = 29)	
Axillary lymphadenopathy				0.305
No	94 (98.9)	66 (100.0)	28 (96.6)	
Yes	1 (1.1)	0	1 (3.4)	
Skin thickening	0	0	0	
Trabecular thickening	0	0	0	
BI-RADS				<0.001
4a and 4b	49 (51.6)	42 (63.6)	7 (24.1)	
4c and 5	46 (48.4)	24 (36.3)	22 (75.9)	
Visibility of the lesion in the US				<0.001
No	77 (81.1)	61 (92.4)	16 (55.2)	
Yes	18 (18.9)	5 (7.6)	13 (44.8)	

Risk for underestimation

Table 4 shows the univariate and multivariate analysis results of the risk for underestimation. Morphology of calcification was a significant determinant of the underestimation in univariate analysis but not in multivariate analysis. In multivariable analysis, palpability (OR, 11.51; 95% CI: 1.817-72.897; P = 0.009), BI-RADS category (OR, 3.705; 95% CI: 1.214-11.303; P = 0.021), and visibility of a mammographically detected lesion at ultrasonography (OR, 7.115; 95% CI: 1.977-25.611; P = 0.003) were significantly associated with the underestimation.

Table 3. Radiographic features.

Patient and lesion characteristics	Analysis for underestimated breast cancer					
	Univariable analysis			Multivariable analysis		
	OR	95% CI	P value	OR	95% CI	P value
Age (y)*						
< 45	1					
≥ 45	0.644	0.233-1.777	0.395			
Presentation						
Screening	1					
Symptoms	2.762	0.920-8.295	0.070			
Palpability						
No	1			1		
Yes	10.182	1.966-52.722	0.006	11.510	1.817-72.897	0.009
History of breast cancer						
No	1					
Yes	1.297	0.456-3.687	0.625			
Morphology of calcification						
Non-linear	1			-	-	-
Fine linear/fine-linear branching	1.911	1.247-2.928	0.003	-	-	-
Distribution of calcification						
Grouped	1					
Linear	2.882	0.742-11.195	0.126			
Segmental	1.681	0.569-4.967	0.347			
BI-RADS						
4a & 4b (<50%)	1			1		
4c & 5 (≥ 50%)	5.500	2.049-14.763	<0.001	3.705	1.214-11.303	0.021
Visibility of the lesion in the US						
No	1			1		
Yes	9.912	3.079-31.910	<0.001	7.115	1.977-25.611	0.003

Discussion

Our analysis shows that the underestimation rate of invasive breast cancer among the patients with VAB-diagnosed DCIS was 30.5%, which is higher than the previously reported rates ranging from 11.2% to 18.0% [7,10,14]. This could be attributed to the initial implementation of the VAB technique at the hospital, where staff might not be highly experienced. It is also noted that ethnicity differs across these studies. A direct comparison between them should be made with caution. Other previous studies demonstrating various underestimation rates are incomparable because of different study populations or biopsy methods [3,4,5,6,8,11,12,15].

Preoperative risk factors for an underestimated diagnosis of invasive breast cancer comprised palpability, BIRADS category, and visibility of mammographically detected lesions on an ultrasound. These findings partly correspond with previous studies [3-5]. Palpability was reported as the risk factor in the earlier studies where the ultrasound-guided biopsy was included. Palpability or palpated mass could imply that the lesion is considerably large and thus likely to be invasive breast cancer. The presence of a mass more significant than 20 mm in size at imaging was significantly associated with the underestimation of invasive breast cancer in the prior studies [3, 4, 7].

BIRADS category was another reported factor in our study; the higher BIRADS scores had an increased likelihood of underestimating invasive breast cancer among patients with VAB-diagnosed DCIS compared to the lower ones [3,5]. It should be noted that our patients were classified into two groups – the group of 4A/4B, where the likelihood of being malignant is less than 50%, and the other group of 4C/5, where it is otherwise. This classification is unique as BIRADS 4 was not subcategorized elsewhere [3,5]. The last factor of visibility of mammographically detected lesions on ultrasound is strongly associated with the underestimation of invasive breast cancer in this study. Still, it is inconsistent with the meta-analysis, which included various biopsy methods and devices [3].

Despite no demonstrable association between distribution with the morphology of calcifications and underestimation of invasive breast cancer, the morphology of suspicious calcification and other features of calcification (e.g., distribution and increased amount/new development of suspicious calcification) give rise to a higher BI-RADS score on the radiologist consideration [14].

Age is not a predictor of an underestimated diagnosis of invasive breast cancer for our patients, similar to previous literature [3, 5, 7, 14]. In addition, we failed to demonstrate the association between certain mammographic features, including architectural distortion, asymmetry, skin and nipple retraction, axillary lymphadenopathy, and the risk of underestimation. However, those features are significantly associated with breast cancer [16,17]. A possible explanation could be the small number of patients in our study.

Four patients of DCIS with microinvasion were classified as pure DCIS and given the same management for DCIS, irrespective of microinvasion. These 4 cases were not an underestimated diagnosis of invasive breast cancer, different previously reported by Chan et al. [7].

The pathologic information of high nuclear grade of DCIS, including the comedo subtype of DCIS and any suspected microinvasive component, was another preoperative factor for underestimating invasive breast cancer in the earlier studies [3, 5]. Unfortunately, the analysis of this piece of information was not feasible for this study. This limitation arose from the non-specific report of nuclear grading in up to 24.2% of cases and the absence of information regarding the comedo subtype in the majority of pathological reports.

This study has some limitations. The data were retrospectively collected and analyzed in a single tertiary hospital. Our small sample size might affect the reliability of our results; some findings are not statistically significant as they would otherwise be due to lack of power. Our study's high underestimation rate might not reflect our current practice's quality. This could be attributed to the initial implementation of the VAB technique, potentially resulting in a lack of extensive

experience among the staff involved. Clinical data were not able to be verified due to retrospective data collection. For example, palpated mass might not be the same lesion where VAB was performed. Some pathological reports were not feasible to analyze due to non-specific results in nuclear grading and the absence of information regarding the comedo subtype, as described earlier.

Our study has crucial clinical implications. We have provided helpful clinical clues to the detection of invasive breast cancer in the patients who were diagnosed with DCIS by VAB. This could enable physicians to make sound judgments, preventing undertreatment and re-operation for those patients.

Conclusion

In conclusion, according to our retrospective analysis, invasive breast cancer was underdiagnosed by 30.5 % in VAB-diagnosed DCIS. Preoperative risk factors significantly associated with underestimated invasive breast cancer, including palpability, BI-RADS category, and visibility of mammographically detected lesions at ultrasonography, have been summarized. This could help physicians identify patients more likely to have invasive breast cancer when diagnosed with DCIS on VAB, as well as preoperative guide discussions regarding the risk of underdiagnosis and treatment alternatives, such as axillary procedure selection at the time of surgical excision or repeat biopsy.

References

1. Parikh U, Chhor CM, Mercado CL. Ductal carcinoma in situ: the whole truth. *AJR Am J Roentgenol* 2018;210:246-55. doi: 10.2214/AJR.17.18778.
2. NCCN Clinical Practice Guidelines in Oncology: Breast Cancer (Version 3.2019) [Internet]. NCCN;2019 Sept 6 [cited 2023 Jul 2]. Available from: https://www2.tri-kobe.org/nccn/guideline/archive/breast2019/english/breast_v3.pdf
3. Brennan ME, Turner RM, Ciatto S, Marinovich ML, French JR, Macaskill P, et al. Ductal carcinoma in situ at core-needle biopsy: meta-analysis of underestimation and predictors of invasive breast cancer. *Radiology* 2011; 260:119-28. doi: 10.1148/radiol.11102368.
4. Kim J, Han W, Lee JW, You JM, Shin HC, Ahn SK, et al. Factors associated with upstaging from ductal carcinoma in situ following core needle biopsy to invasive cancer in subsequent surgical excision. *Breast* 2012 ;21:641-5 . doi: 10.1016/j.breast.2012.06.012.
5. Meurs CJC, van Rosmalen J, Menke-Pluijmers MBE, Ter Braak BPM, de Munck L, et al. A prediction model for underestimation of invasive breast cancer after a biopsy diagnosis of ductal carcinoma in situ: based on 2892 biopsies and 589 invasive cancers. *Br J Cancer* 2018;119:1155-62. doi: 10.1038/s41416-018-0276-6.
6. Jakub JW, Murphy BL, Gonzalez AB, Connors AL, Henrichsen TL, Maimone S 4th, et al. A validated nomogram to predict upstaging of ductal carcinoma in situ to invasive disease. *Ann Surg Oncol* 2017;24:2915-24. doi: 10.1245/s10434-017-5927-y.
7. Chan MY, Lim S. Predictors of invasive breast cancer in ductal carcinoma in situ initially diagnosed by core biopsy. *Asian J Surg* 2010;33:76-82. doi: 10.1016/S1015-9584(10)60013-9.

8. Esen G, Tutar B, Uras C, Calay Z, İnce Ü, Tutar O. Vacuum-assisted stereotactic breast biopsy in the diagnosis and management of suspicious microcalcifications. *Diagn Interv Radiol* 2016;22:326-33. doi: 10.5152/dir.2015.14522.
9. Luparia A, Durando M, Campanino P, Regini E, Lucarelli D, Talenti A, et al. Efficacy and cost-effectiveness of stereotactic vacuum-assisted core biopsy of nonpalpable breast lesions: analysis of 602 biopsies performed over 5 years. *Radiol Med* 2011;116:477-88. English, Italian. doi: 10.1007/s11547-011-0625-x.
10. Jackman RJ, Burbank F, Parker SH, Evans WP 3rd, Lechner MC, Richardson TR, et al. Stereotactic breast biopsy of nonpalpable lesions: determinants of ductal carcinoma in situ underestimation rates. *Radiology* 2001;218:497-502. doi: 10.1148/radiology.218.2.r01fe35497.
11. Pandelidis S, Heilman D, Jones D, Stough K, Trapeni J, Suliman Y. Accuracy of 11-gauge vacuum-assisted core biopsy of mammographic breast lesions. *Ann Surg Oncol* 2003;10:43-7. doi: 10.1245/aso.2003.05.004.
12. Kettritz U, Rotter K, Schreer I, Murauer M, Schulz-Wendtland R, Peter D, et al. Stereotactic vacuum-assisted breast biopsy in 2874 patients: a multicenter study. *Cancer* 2004;100:245-51. doi: 10.1002/cncr.11887.
13. Lee CH, Carter D, Philpotts LE, Couce ME, Horvath LJ, Lange RC, et al. Ductal carcinoma in situ diagnosed with stereotactic core needle biopsy: can invasion be predicted?. *Radiology* 2000;217:466-70. doi: 10.1148/radiology.217.2.r00nv08466.
14. Kim M, Kim HJ, Chung YR, Kang E, Kim EK, Kim SH, et al. Microinvasive carcinoma versus ductal carcinoma in situ: a comparison of clinicopathological features and clinical outcomes. *J Breast Cancer* 2018;21:197-205. doi: 10.4048/jbc.2018.21.2.197.

15. Houssami N, Ciatto S, Ellis I, Ambrogetti D. Underestimation of malignancy of breast core-needle biopsy: concepts and precise overall and category-specific estimates. *Cancer* 2007;109:487-95. doi: 10.1002/cncr.22435.
16. Jiang L, Ma T, Moran MS, Kong X, Li X, Haffty BG, et al. Mammographic features are associated with clinicopathological characteristics in invasive breast cancer. *Anticancer Res* 2011;31:2327-34.
17. Wadhwa A, Majidi SS, Cherian S, Dykstra DS, Deitch SG, Hansen C, et al. Architectural Distortion on Screening Digital Breast Tomosynthesis: Pathologic Outcomes and Indicators of Malignancy. *J Breast Imaging* 2021;3:34-43.