

## ULTRASOUND - GUIDED TRANSRECTAL DRAINAGE OF PELVIC ABSCESS

Wiwatana TANOMKIAT,MD., Siriporn HIRUNPAT,MD

### ABSTRACT

Although transrectal drainage of deep pelvic abscess has been reported, the cumulative experience is small. Two cases of deep pelvic abscess treated successfully with transrectal drainage were described. Ultrasound was used as the imaging guidance, providing inexpensive, real-time, multiplanar and radiation-free images that made the procedure quick, accurate and safe.

### INTRODUCTION

Percutaneous drainage has become an effective method in the treatment of intraabdominal abscesses. However, most pelvic abscesses are located close to the bowel, bladder or uterus which prevents an anterior or anterolateral percutaneous approach. A posterolateral or transgluteal approach is usually painful and uncomfortable for the patient. A transrectal approach is an alternative and has advantages over anterior or posterolateral percutaneous approaches by being the shortest route and avoids important structures. Although imaging-guided transrectal drainage of pelvic abscesses has been reported and the first case in Thailand has been recently described,<sup>1</sup> the cumulative experience is small. To our knowledge, transrectal drainage with real-time sonographic guidance has never been reported in ASEAN countries.

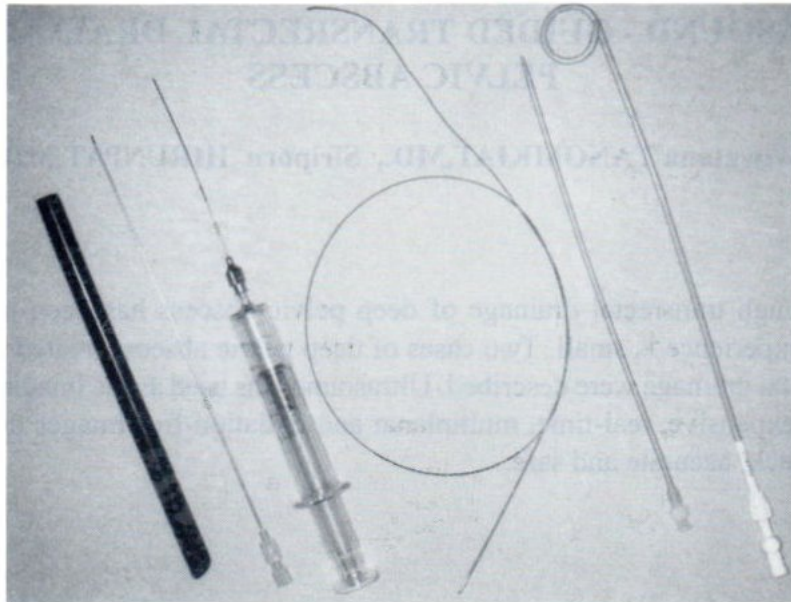
### TECHNIQUE

The rectum was prepared with 100 cc of Unison Enema®(15% Sodium Chloride). Sedation was not necessary. Patients were in a left decubi-

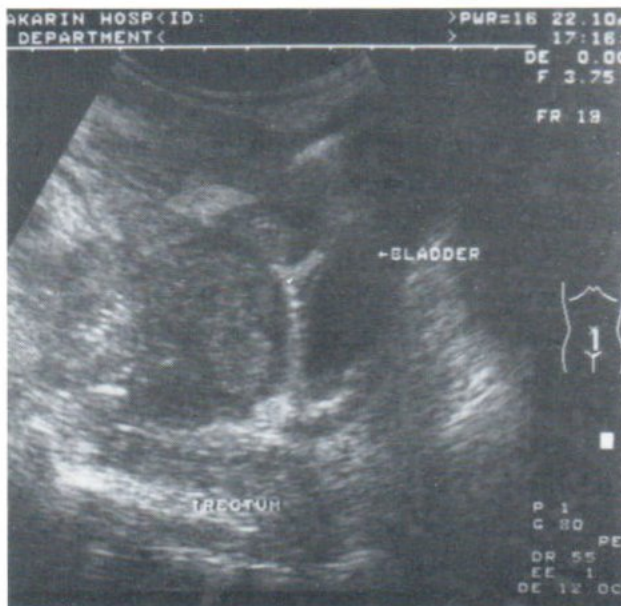tus position with hips and legs flexed. The distended urinary bladder was used as a good acoustic window for transabdominal sonography. The abscess and its relationship to the rectum were observed with real-time sonography, using a 3.5 MHz probe (Fig.2). A 34-French plastic tube lubricated with lidocaine jelly was inserted to protect the anal canal. The tube was well demonstrated on sonography as it was passing through the rectum to the site of abscess. When the tip of the tube was in optimal contact with the abscess, the rectal wall was firmly pressed. Using a 22-gauge spinal needle, 2.5 cc of 1% lidocaine was injected into the rectal wall. The puncture was made with a 16-gauge needle (Fig.3,4). After the pus was aspirated, an 0.035-inch guide wire was placed into the abscess (Fig.5). The needle was then removed, and the tract was dilated with a 10-French dilator. A 10-French self-retaining catheter was inserted and its loop was formed (Fig.6). The catheter was connected to the portable suction apparatus. The instruments used in the procedure are shown in Fig.1.

**Correspondance** : Department of Radiology, Faculty of Medicine, Prince of Songkla University, Kanchanavanich Rd. Hat - Yai, 90110, Thailand Tel. 66-74-212070-9 ext 1501 Fax : 429927 E-mail : twiwadha@ratree.psu.ac.th

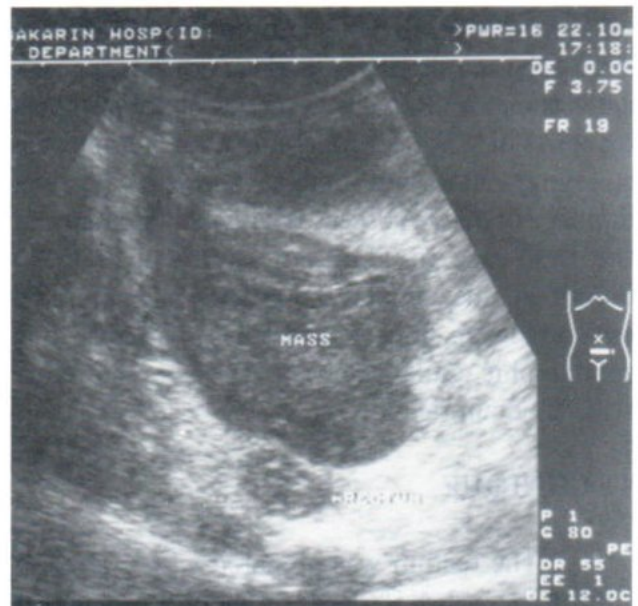**Correspondance to** : W. Tanomkiat



**Fig.1.** Showing the instruments used in the procedure. From Left to Right are : a 34-French plastic tube, a 16-guage needle, a 22-guage spinal needle connected to a syringe containing 2.5 cc of 1% lidocain, a 0.035-inch guide wire, a 10-French dilator and a 10-French self-retaining catheter.



**2A.**

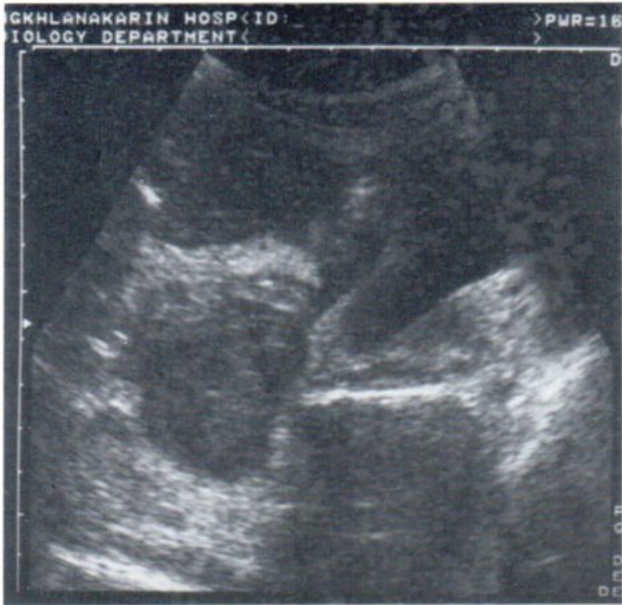

**2B.**

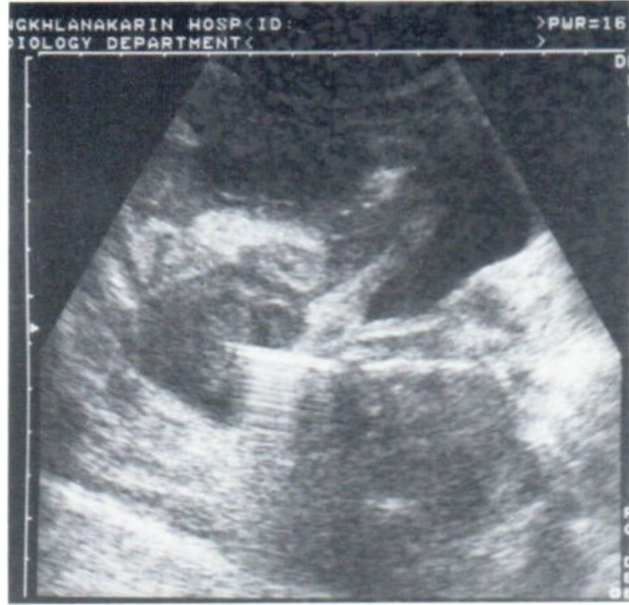**Fig.2.** A deep pelvic abscess in patient 1.

A, Sagittal sonography shows an abscess lying above the urinary bladder and anterior to the rectum.

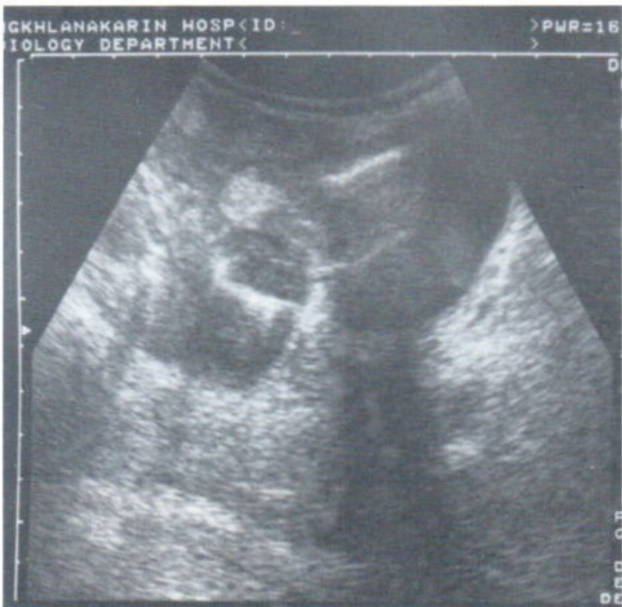B, An axial sonogram shows that the abscess is just anterior to the rectum.



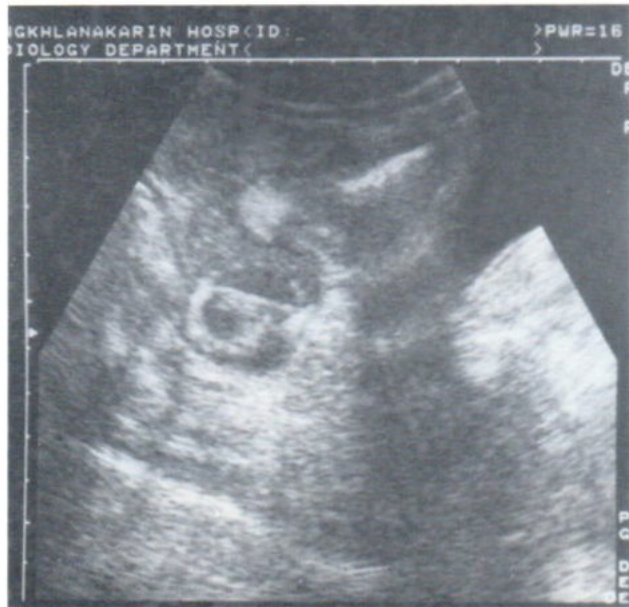**Fig.3.** A sagittal sonogram shows a needle inserted via the rectum. The tip of the needle is in optimal contact with the abscess.



**Fig.4.** A sagittal sonogram showing that the abscess is punctured.



**Fig.5.** A sagittal sonogram shows that the abscess is partially collapsed after aspiration. The guide wire is placed into the abscess.



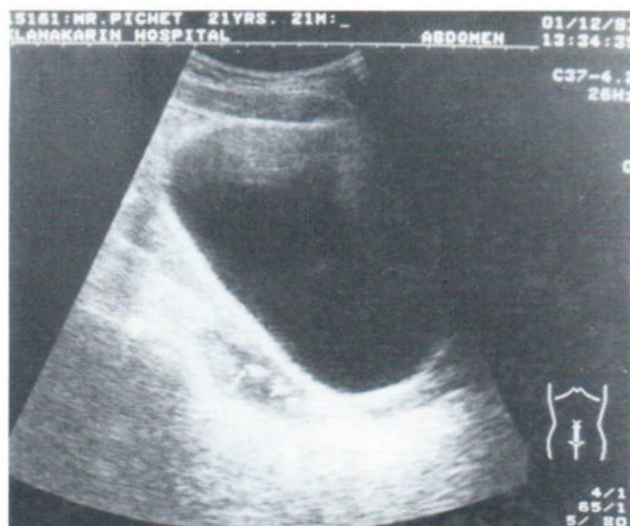**Fig.6.** A sagittal sonogram shows placement of a self-retaining catheter.

## RESULTS

### PATIENT 1

A 20-year-old man had ruptured appendicitis. After surgery he had high fever, abdominal pain, diarrhea and leukocytosis. Sonography revealed an abscess in the rectovesical pouch.

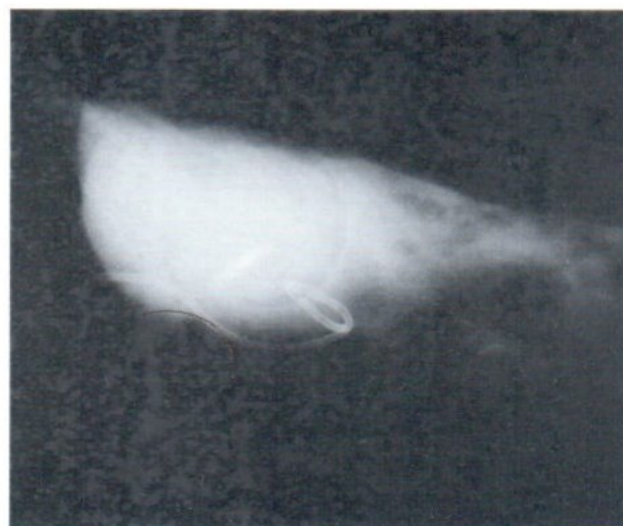A catheter was placed with the transrectal approach and 83 cc of pus was aspirated. His temperature became normal during the first day after drainage. Serial sonograms showed nearly complete collapse of the abscess (Fig.7). The catheter was removed 6 days after insertion. The patient was discharged 8 days after catheter placement.



**Fig.7.** A follow - up sagittal sonogram reveals nearly complete collapse of the abscess. Arrows point to the loop of the catheter.

### PATIENT 2

A 28-year-old man had peptic ulcer perforation and underwent surgery. He had postoperative fever, left lower quadrant pain and high leukocytosis. Sonography revealed an abscess in the pouch of Douglas and a separate smaller one next to it. The abscess in the pouch of Douglas was drained by a catheter inserted with the transrectal approach, and 50 cc of pus was aspirated. The catheter was removed 5 days after insertion. The smaller abscess was subsequently aspirated percutaneously.



**Fig.8.** A lateral radiograph demonstrates the position of the catheter.

## DISCUSSION

Transrectal drainage of pelvic abscesses can be guided by fluoroscopy, computed tomography (CT), or ultrasound. The first-described pelvic abscess drainage by transrectal approach was done under fluoroscopic control.<sup>2</sup> The disadvantage of fluoroscopy is that it cannot provide cross-sectional images which may result in an inaccurate puncture. In addition, both the operator and the patient are exposed to radiation.

The major disadvantage of CT is that it cannot provide the sagittal or oblique sagittal images which probably are the most useful planes to visualize the puncture and needle insertion. Accurate puncture or needle placement may not be possible by using only an axial CT image. Furthermore, most CT scanners do not provide real-time guidance which makes the procedure more time consuming than those guided by either fluoroscopy or ultrasound. In addition, like fluoroscopy, the patient is exposed to radiation.

Ultrasound is probably the most widely available cross-sectional imaging machine. Its multiplanar images provide accurate localization and needle placement. It also provides real-time guidance which makes the puncture and needle placement both accurate and quick. Each of our cases required less than 20 minutes to complete. In addition, sonography is inexpensive and can be performed bed-side. In contrast to CT or fluoroscopy, it is radiation-free.

Like percutaneous drainage, catheter placement with the transrectal approach can be used as the definitive treatment or for temporary relief in patients with a pelvic abscess. In our 2 cases it was used as the definitive treatment of post-operative abscesses, and obviated the need of re-operation. It has also been used as a definitive treatment in patients with appendiceal abscess or prostatic abscess.<sup>3,4</sup>

As compared to anterior percutaneous or transgluteal approaches, transrectal drainage is well tolerated. It requires less analgesia and shorter hospital stays than either percutaneous or surgical drainage.<sup>5</sup> Moreover, it allows better gravitational sump drainage. It was also found to be without complications in most reports.<sup>2,9</sup>

In conclusion, transrectal drainage is a quick, safe, effective and well tolerated treatment of pelvic abscesses.

## REFERENCES

1. Tanisro K. CT-guided transrectal drainage of deep pelvic collection. *Asean Journal of Radiology* 1998; 4: 135-140
2. Mauro MA, Jaques PF, Mandell VS, Mandel SR. Pelvic abscess drainage by the transrectal catheter approach in men. *AJR* 1985; 144: 477-479
3. Jamieson DH, Chait PG, Filler K. Interventional drainage of appendiceal abscess in children. *AJR* 1997; 169: 1619-1622
4. Barozzi L, Pavlica P, Menchi I, et al. Prostatic abscess: diagnosis and treatment. *AJR* 1998; 170: 753-757
5. Pereira JK, Chait PG, Miller SF. Deep pelvic abscesses in children: transrectal drainage under radiologic guidance. *Radiology* 1996; 198: 393-396
6. Noshier JL, Needell GS, Amorosa JK, Krasna IH. Transrectal pelvic abscess drainage with sonographic guidance. *AJR* 1968; 146: 1047-1048
7. Bennett JD, Kozak RI, Taylor BM, Jory TA. Deep pelvic abscesses: transrectal drainage with radiologic guidance. *Radiology* 1992; 185: 825-828

8. Gazelle GS, Haaga JR, Stellato TA, et al. Pelvic abscesses: CT-guided transrectal drainage. *Radiology* 1991; 181: 49-51.
9. Carmody E, Thurston W, Yeung E, Ho CS. Transrectal drainage of deep pelvic collections under fluoroscopic guidance. *Can Assoc Radiol J* 1993; 44: 429-433