

## SMALL BOWEL LEIOMYOMA ; CASE REPORT

Porntip SUPAWONGSE MD.<sup>1</sup> Kosin TRIRUTVIRAPONG MD.<sup>2</sup>

### ABSTRACT

Tumour of small bowel, both benign and malignant, are relatively uncommon and often present a diagnostic challenge as their symptoms are often vague and mimic with other diseases of the digestive tract. Here is a case which was suffering from nonspecific chronic abdominal pain for a long time, about 10 months, before operation indicated by gut obstruction. Radiographic studies, UGI, SBFT, BE and CT were performed. Dilatation of proximal jejunum with mucosal edema were demonstrated. No definite cause of obstruction is detected and the contrast media passing through the colon was observed. Intussusception of small bowel with self release was diagnosed.

UGI	=	Upper G.I.
SBFT	=	Small Bowel Follow Through Study
BE	=	Barium Enaema

### CASE REPORT

A Thai female, 48, first came to the hospital with a chief complaint of melena and abdominal pain. Physical examination revealed good built, 62.5 kg., and stable vital signs but markedly pale was noted. CBC showed Hb 4.7%, Hct 15% with normal morphology and differential count. Blood chemistry and electrolytes were within normal limits. Gastroscopy revealed two hemorrhagic spots at roof of the bulb. Telangiectasia or vascular ectasia was suspected. Double contrast BE and UGI studies were normal. She was treated as peptic ulcer disease and received blood replacement. Bleeding ceased and the patient noticed some improvement.

However she still had abdominal pain, on and off, and noticed that it was aggravated after get up in the morning until evening but relieved at night. Sometime nausea, vomiting, referred pain to the back and constipation occur. Seven months

after the first admission, marked abdominal distension with pain and constipation brought her to the second admission and gut obstruction was diagnosed.

BE study was again normal. UGI with small bowel follow through (SBFT) showed dilatation of the proximal part of small bowel, prominently at jejunum and lessly at duodenum, with edematous wall. Distal small bowel was unremarkable. Transitional zone was visualized without mass, pressure effect or definite cause of obstruction. (Fig. Ia, Ib, Ic) CT study showed normal solid organ and confirmed the finding in SBFT. (Fig. IIa, IIb, IIc) No mass or ascites was detected. Small bowel obstruction with self release was concluded.

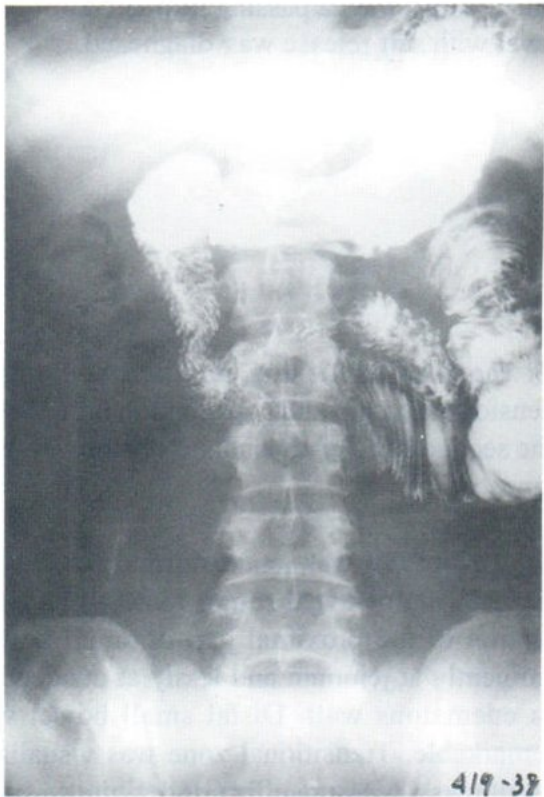Exploratory laparotomy was performed and revealed a well circumscribed small bowel

<sup>1</sup> Division of Radiology , Pranangkloa Hospital , Nonthaburi , Thailand

<sup>2</sup> Division of Surgery , Pranangkloa Hospital , Nonthaburi , Thailand

tumour 1 cm. in diameter, at 1.5 feet from ligament of Treiz. The mass involved through mucosa. The proximal jejunum and the jejunum 2 feet distal from the mass were dilated. The rest of small bowel and colon were normal .

The bowel including tumour and adjacent lymph nodes were resected and end to end anastomosis was performed. Histopathological study of the resected mass was reported as leiomyoma with free margin and lymph node hyperplasia. The patient got well since then.

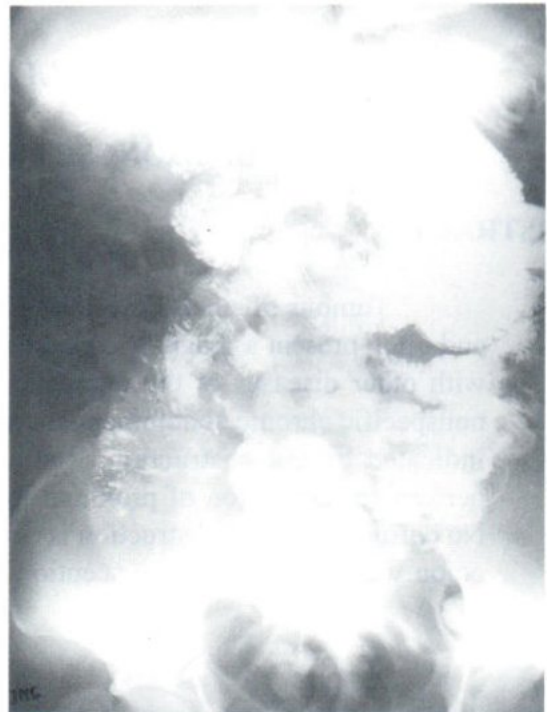

1A

**FIG. 1** Small bowel follow through study

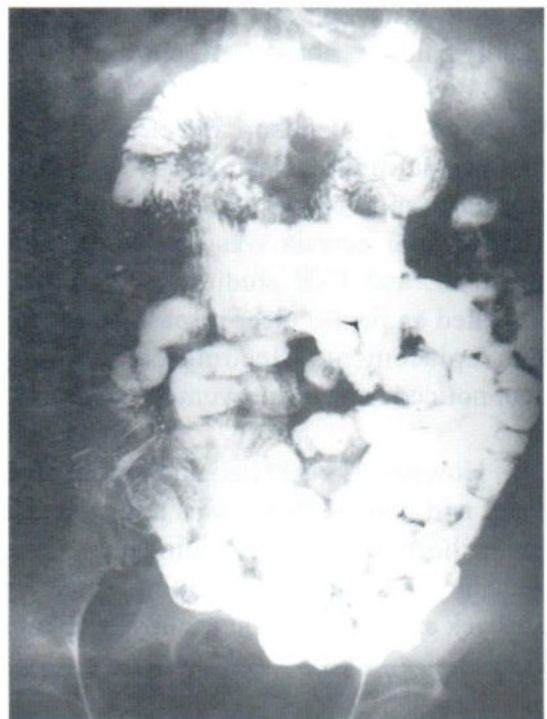1A. 15 min. After intake, slightly dilated C-loop with dilated proximal jejunum

1C. 45 min. Normal ileum and colon visualized



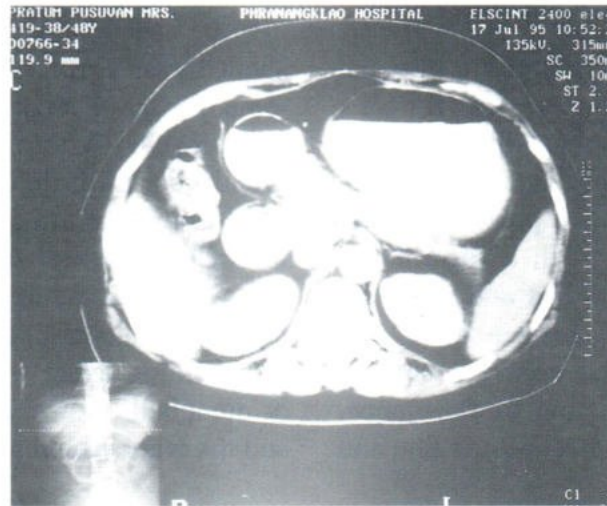
1B

1B. 30 min. Continuous dilated proximal jejunum with mucosal edema, transitional zone noted at midline of lower part of the film, no intraluminal mass or extrinsic pressure effect visualized



1C

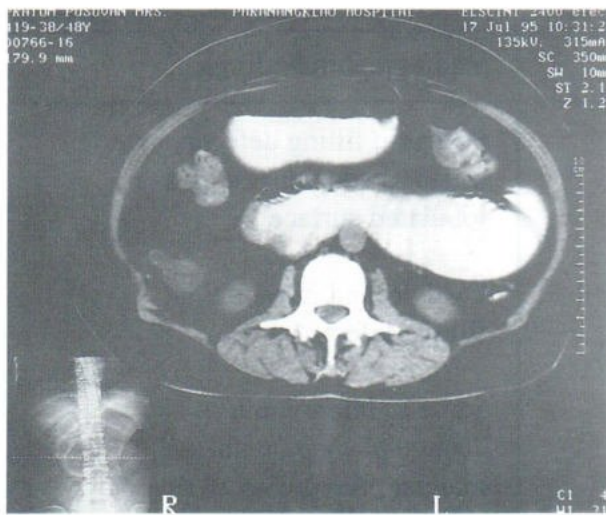



2A

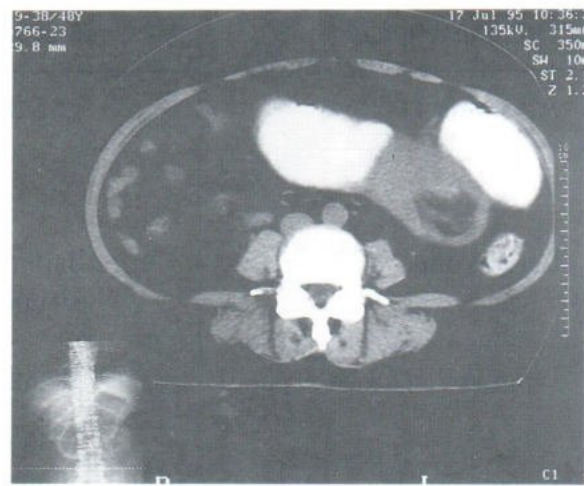
FIG. 2 CT study

2A. Dilated C-loop at pancreatic head level, cross section view



2B

2B. Continuous dilated loop of jejunum with slight mucosal edema



2C

2C. Dilated jejunal loop and nondilated distal small bowel with contrasted filled

## DISCUSSION

Neoplasms of small bowel are rare and comprising only 2-5 % of tumours of GI tract<sup>1,3</sup> and much less than that of colon which is said to be about 1: 40<sup>4</sup>. Benign group is found slightly more than the malignant one. It presents to both clinician and radiologist with a formidable diagnostic challenge. Symptoms and signs are often absent, sometime intermittent and nonspecific. There may be poorly localized abdominal pain, vague feeling of flatulence, chronic occult blood loss, bowel obstruction and palpable mass.

Of the benign group, about 90% are adenoma, leiomyoma, lipoma and hemangioma in order of frequency.<sup>5</sup> Adenoma and leiomyoma are

about the same frequency in some series.<sup>4</sup> Leiomyoma is in the first rank when included with those of stomach.<sup>6</sup> Within small bowel, leiomyoma oftenly occurs in jejunum, lessly in ileum and duodenum. The tumour mass oftenly grows out through the serosal layer and causing extrinsic mass effect. Sometimes it occurs in submucosal layer (as in our case) and causing smooth oval or round filling defect. It may pedunculated, bilobed or dumbbell shaped with one part in the lumen and the other protuding out of the serosal.

The tissue histology, frequency, locations and radiographic findings of the common small bowel tumours are shown on table 1 .

**Table I ;** Differences in locations and radiographic findings of common small bowel benign tumours<sup>3,5</sup>

Tumour/frequency	Locations	Radiographic findings
Adenoma 17-25 %	Duodenum	Polypoid filling defects , usually pedunculated and lobulated surface
Leiomyoma 17 %	Jejunum Ileum	Oval , round intraluminal filling defect
Lipoma 14 %	Ileum	Same as leiomyoma . change of shape with manual pressure on abdomen
Hemangioma 10 %	Jejunum	Intramural or intraluminal round polypoid mass



Accepted clinical indications for small bowel radiography include 1) unexplained GI bleeding, 2) possible small bowel tumour, 3) small bowel obstruction, 4) Crohn's disease, and 5) malabsorption. Because of the inherent difficulty of visualizing numerous loops of an actively peristaltic bowel a reliable imaging method is needed not only for detection of small or early structural abnormality but also for accurately documented normalcy. The yield of information provided by enterocyclis and its high negative predictive value suggested that it should be a primary method for small bowel examination.<sup>1</sup> However, many radiologist prefer overhead-based conventional small bowel follow through as it is easier to perform and causing less discomfort to the patient particularly in the presence of bowel obstruction. The study may reveal only secondary changes of obstruction such as bowel dilatation and wall edema as in this case. Small mass effect, filling defect or transitional zone may be masked by overlapping loops. Sometime transitional zone shows nothing if intussusception is the cause of obstruction and the tumour is the leading point, as the mass should be localized in the dilated part

CT can be a useful test for evaluation of small bowel obstruction and can reveal both the diagnosis of obstruction and its differentiation from other conditions resulting in small bowel dilatation. Some specific criteria were proposed to indicate obstruction i.e. 1) the presence of continuous bowel dilatation, 2) the presence of prestenotic dilatation, and 3) the identification of transitional zone between normal and abnormal dilated part. Intermittent dilatation of small bowel, dilatation of large bowel, mucosal edema and bowel fluid more than 50 %, are nonspecific and could be found in nonobstructive group as well.<sup>2</sup>

Angiography is sometime helpful in demonstrating small intestinal leiomyomas, even if performed at a time when the patient is not in active bleeding. These tumours are often hypervascular and show intense opacification during the capillary phase of the injection, and there may be early opacification of large mesenteric veins draining the tumour.<sup>5</sup>

In this case, continuous bowel dilatation and mucosal edema were demonstrated in both SBFT and CT studies without definite identification of tumour mass. Furthermore flow to colon was shown in SBFT study. So only one specific criteria by Gaselle,<sup>2</sup> continuous bowel dilatation, was fitted to indicate obstruction. As correlate to clinical symptoms, the patient was likely suffered from intermittent intestinal intussusception with self release. As we know, small bowel tumour is a common cause of intestinal intussusception in adult and elderly .

## CONCLUSION

Leiomyoma of small bowel is a rare disease, occurring in late adult or elderly and often undiagnosed because there are usually symptomless or only vague nonspecific abdominal symptoms. Sometime it would take a long time before we can make a diagnosis. With prolonged abdominal pain, GI bleeding or bowel obstruction the condition should be kept in mind and investigation should be performed. Enterocyclis is proposed to be the primary test to be obtained. SBFT should be an alternative study if enterocyclis is not possible. CT should follow as a complimentary study and for evaluation of situations of other organs. Sometime definite diagnosis of tumour cannot be concluded before operation and histologic study .

## REFERENCE

1. Maglinte DDT, Kelvin PM, O'Conner K., Lappas LC, Chernish SM ; Current status of small bowel radiography (Review), *Abdominal imaging* (3) : 247-257,1996 May-Jun.
2. G-Scotte Gaselle, Mark A. Goldberg, Jack Wittenberg, Elkan F. Halpern, Lynne Pinkney, Peter R. Mueller : Efficacy of CT in distinguishing small-bowel obstruction from other cause of small bowel dilatation *AJR* 1994;162;43-47.
3. Shearman David JG : Disease of gastrointestinal tract and liver 1989;439-440
4. Courtney M. Townsend, Jr., Jame C. Thompson ; *Schwartz Principle of surgery*; 6th edition; 1994,1170-1178
5. Robert E. Kochler, Alexander R. Margulis; *Alimentary tract radiology* 3rd edition; 1979 , 962-965
6. Mendes da Costa P., Beernaert SA, Benign tumour of upper gastrointestinal tract (stomach, duodenum, small bowel ) ; a review of 178 surgical cases ; Belgian multicentric study *Acta Chirurgica Belgica*; 1993 , Mar.- Apr. , 93(2):39-42