

THREE DIMENSIONAL COMPUTERIZED PLANNING AND PERIODICAL IRRADIATION WITH THE CORRESPONDING OF PATIENT'S RESPIRATION PHASE FOR SOLITARY LUNG METASTASIS : A CASE REPORT.

Pattaranutaporn P, MD.¹, Chansilpa Y, MD.¹, Kakanaporn C, MSc. (Med. Phys.)¹,
Onnomdee K, BSc.(Med. Tech.)², Mungkung N, BSc.(Med. Tech.)²,
Santisiri R, BSc.(Med.Tech.)².

ABSTRACT

A case report of metastatic lung from carcinoma of the rectum was treated with 3D-CT planning and periodical irradiation with the corresponding of patient respiration phase. This technique permits the precise delivery of high dose of radiation to the target while sparing the most of normal lung tissue. The radiation dose was 20 Gy single dose, encompassed the target at the 90 per cent isodose line. The tumor was totally disappeared 1 month after the completion of treatment. The patient could tolerate to the treatment procedure well without any complications inherent to the technique. This technique is an effective and safe treatment for localized lung metastasis. However, long term follow-up should be done to evaluate the late radiation effect of the single fraction radiation therapy.

INTRODUCTION

The optimal treatment for patients with pulmonary metastases from colorectal carcinoma is still controversial. Currently, the only treatment capable of significantly prolonging survival in patients with isolated pulmonary metastases from colorectal cancer is complete resection. Surgery represents the first-choice treatment to manage the pulmonary metastases from colorectal cancer when the primary tumor has been controlled and there is no evidence of metastatic spreading to any other organs. The three and five years survival post metastatectomy were 71.6 and 23-43 per cent respectively and some reported in ten year survival.¹⁻⁴ A significant difference was noted in the survival rate according to both number and size of the metastatic lesions ($P < 0.05$).^{1-3,5}

Conventional radiation therapy for pulmonary metastases is limited by the tolerance of the lung tissue. With the improvement of radiation technique such as stereotactic radiotherapy, it is

accepted to be an effective loco-regional treatment modality as surgery. Three dimensional treatment planning system and conformal radiotherapy facilitates treatment by providing a mechanism for conforming the high-dose treatment volume to the target volume, thus minimizing the dose to the adjacent uninvolved normal structures. This process involves graphic reconstruction of 3-dimensional images from multiple cross-sectional images, beam's-eye-views display, rapid dose calculations and dose display, and the interactive modification of beam parameters to allow target dose coverage and exclude uninvolved tissue. However, the movement of intrathoracic and intraabdominal target during treatment still be the major problem for conforming radiation technique. The periodical irradiation with the corresponding of patient's respiratory phase technique for lung metastasis is developed to solved this problem.

¹ Division of Radiation Oncology, Department of Radiology, Faculty of Medicine, Siriraj Hospital, Mahidol Univesity, Bangkok.

² Department of Radiology, Srisiam Hospital, Bangkok.

MATERIAL AND METHOD

A 60 years old male patient with carcinoma of rectum was treated with radiation and chemotherapy because of the contra-indication to surgery from cirrhosis of the liver. Metstasis in the right lower lung was detected one year later. The CT scan of the lung was done for evaluation of the metastases and showed only single small lesion in the right lower lung. Because of the same contraindication to surgery, radiation was considered for this condition.

TECHNIQUE

The patient was positioned and immobilized on the CT-scanner couch with the marker wires placed in the midline and lateral of body along the laser beam. This position was set with these markers through out the treatment procedure. Axial CT images, with 0.5 cm slice thickness through the lung were obtained during full

inspiration. The CT images were transfered directly to the treatment planning system : Focus 3D-planning system. The process was done orderly from labelling of the external contour, normal critical organ and normal tissues that effect the inhomogenicity such as bone and air cavity. After that, the treatment volume was defined including the tumor volume and the biological and physical volume. The treatment planning were done according to the shape of tumor and critical organ nearby. Multiple arc rotation beams and static beams of different couch angles were used. The ninety per cent isodose line was encompassed the target while sparing the most of the lung tissue. After the treatment plan was approved, the alignment was transfer to the central level of the treatment field with conventional simulation, while the patient was set in the same position. The simulation film was checked to confirm that the tumor is in the field of treatment.

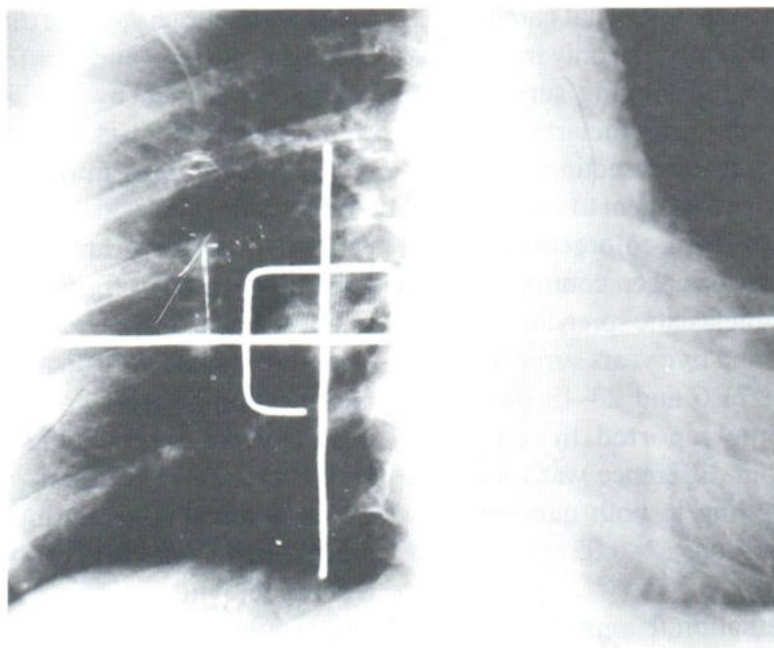


Fig. 1 The simulation film show the correct position of the target in the treatment field in the inspiratory phase.

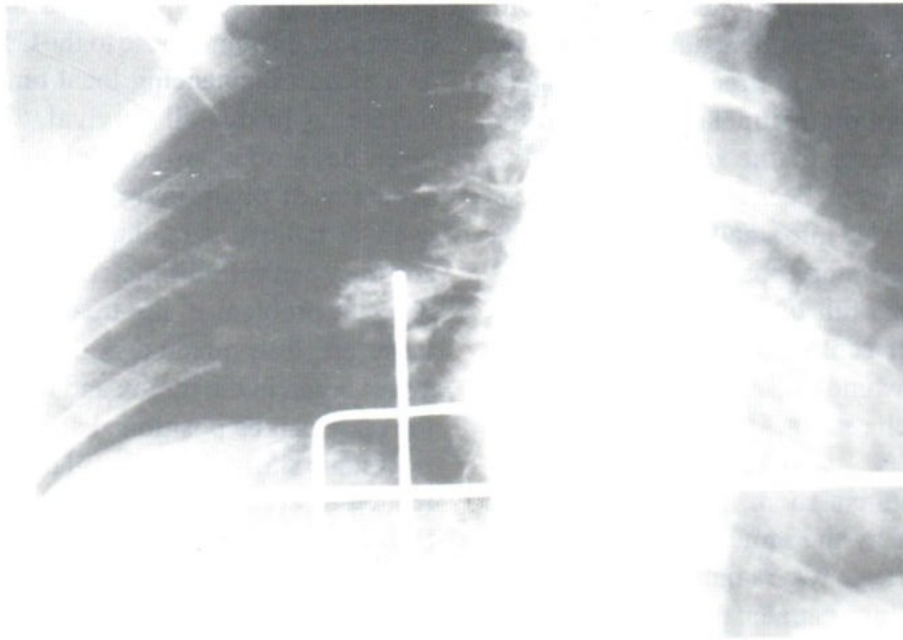


Fig. 2. The simulation film of the expiratory phase showed the error of treatment field due to respiration.

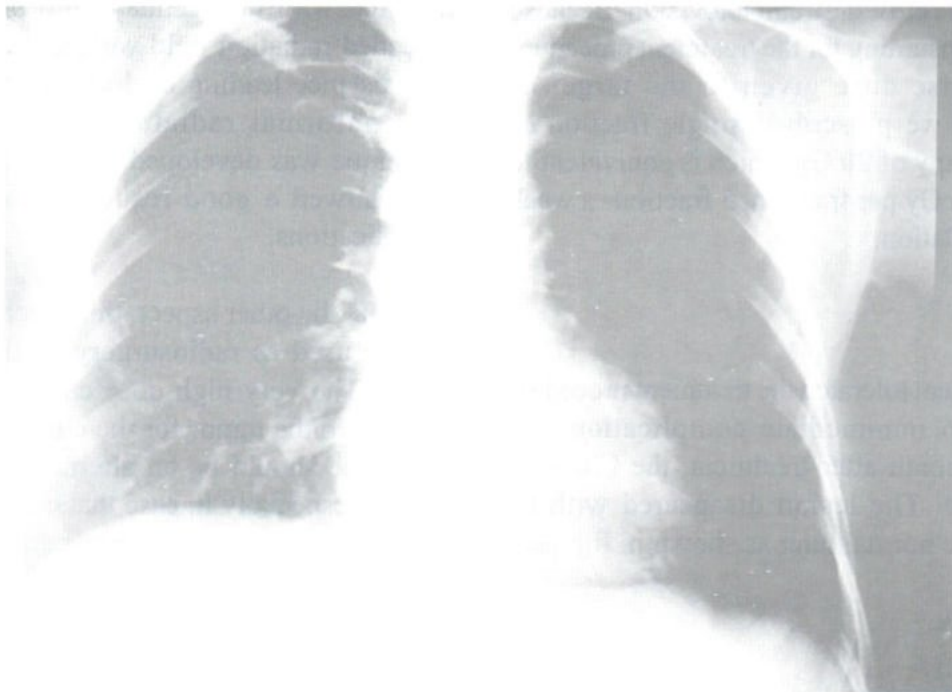


Fig. 3. The chest x-rays film 1 month after treatment showed the disappearance of the lesion.

Because of the chest movement from breathing, the small treatment target would be missed during the period of irradiation as in figure 1 and 2. The radiation treatment was limited for the inspiratory phase of the respiration as the treatment planning had been done. The treatment then had to be divided into small multiple sessions related to the inspiratory phase. The patient was trained to keep his full inspiration as long as he could and 80 per cent of the duration he could hold his breath would be used for the period of irradiation in each session.

In the treatment room, the patient was set and immobilized by the same position as for the CT scanning. At least two radiation technologists were needed for this treatment procedure. The first one worked on the treatment machine while the other controlled the patient respiration during treatment through the intercom, and observed the patient from the closed-circuit television. Because of the time consuming for the treatment procedure and the precise dose given to the target as radiosurgery, we prescribed single fraction of radiation therapy of 20 Gy which is equivalent to 70 Gy of 200 cGy per fraction, 5 fractions a week by TDF calculation.

RESULT

The patient tolerated the treatment procedure very well, no immediate complication was found. One month after treatment, the Chest X-ray was done. The lesion disappeared with no reaction of the normal lung as shown in figure 3.

DISCUSSION

The concern that the tumor receives the dose high enough to achieve a reasonable probability of local control while the radiation dose to normal tissue should be kept low enough to an acceptable complication level was well aware of. Target-specific treatment is particularly desirable if radiosensitive organs are located close to the tumor site. Three dimensional computerized

planning system provides a mechanism for increasing the tumor dose to the CT-defined target as a mean of enhancing local tumor control and increasing in overall survival.⁶⁻¹⁰ Many system were developed to control or determine the accuracy of positioning and quality assurance even in radiosurgery that was accepted for the accuracy within millimeter.¹¹⁻¹² One of the most difficult problem in the treatment procedure for these precisely method is the movement of the target organ in the thorax and the abdomen. Even the body can be positioned and immobilized, the metastatic site in the lung still moves up and down related to the cycle of breathing as shown in the figure 1&2. The conventional technique for measuring the motion of an organ is to locate the landmarks in the organ and on the bony anatomy and to compare the distance between these landmarks on subsequent CT scanning. Some invasive techniques using seeds implantation were reported with unacceptable morbidity.¹³⁻¹⁴ The extended radiation field were also used to cover this distance leading to decreasing the value of the conformal radiation technique. So this technique was developed to solved the problem and showed a good result without any acute complications.

In the other aspect, this precised technique can be used as radiosurgery in the movement organ. The very high dose can be given in one fraction to the tumor for the curative intent. This technique should be an alternative treatment to surgery especially in case that contraindicated to surgery. Thus, the 1.4 per cent of operative mortality can also be avoided.¹⁵

CONCLUSION

Three dimensional computerized planning and periodical irradiation at the corresponding respiratory phase of the patient, is one of the good method for irradiation the moving target such as the lung lesion. This technique should be considered as:

1. An alternative to open surgery for metastectomy in the lung metastasis from the colorectal cancer both for curative or palliative aims.

2. The best method for the new lesion or local recurrent in the previous irradiated lung lesion.

3. Used as the booster technique for delivering the high dose to the well defined volume while sparing the normal surrounding lung tissue.

REFERENCES

1. Shirouzu K, Isomoto H, Hayashi A, et al. Surgical treatment for patients with pulmonary metastases after resection of primary colorectal carcinoma. *Cancer* 1995;76:393-398.
2. Van Halteren HK, van Geel AN, Hart AA, Zoetmulder FA. Pulmonary resection for metastases of colorectal origin. *Chest* 1995;107:1526-1531.
3. Yano T, Hara N, Ichinose Y, et al. Results of pulmonary resection of metastatic colorectal cancer and its application. *J Thorac Cardiovasc Surg* 1993;106:875-879.
4. McCormack PM, Burt ME, Bains MS, et al. Lung resection for colorectal metastases, 10-year results. *Arch Surg* 1992;127:1403-1406.
5. Zapatero J, Flandes J, Lago J, et al. Prognostic factors in pulmonary metastases from colorectal cancer. *Respiration* 1994;61:280-282.
6. Ha CS, Kijewski PK, Langer MP. Gain in target dose from using computer controlled radiation therapy (CCRT) in the treatment of non small cell lung cancer. *Int J Radiat Oncol Biol Phys* 1993;26:335-359.
7. Leibel SA. The biologic basis for conformal three-dimensional radiation therapy. *Int J Radiat Oncol Biol Phys* 1991;21:805-811.
8. Lichter AS. Three-dimensional conformal radiation therapy : A testable hypothesis. *Int J Radiat Oncol Biol Phys* 1991;21:853-855.
9. Fuks Z, Leibel SA, Wallner KE, et al. The effect of local control on metastatic dissemination in carcinoma of the prostate : Long term results in patients treated with 125 I implantation. *Int J Radiat Oncol Biol Phys* 1991;21:537-547.
10. Leibel SA, Scott CB, Mohiuddin M, et al. The effect of local-regional control on distant metastatic dissemination in carcinoma of head and neck : Results of an analysis from the RTOG head and neck database. *Int J Radiat Oncol Biol Phys* 1991;21:805-811.
11. Menke M, Hirschfeld F, Mack T, et al. Photogrammetric accuracy measurements of Head Holder Systems used for fractionation radiotherapy. *Int J Radiat Oncol Biol Phys* 1994;29:1147-1155.
12. Drzymala RE, Klein EE. Assurance of high quality Linac-based stereotactic radiosurgery. *Int J Radiat Oncol Biol Phys* 1994;30:459-472.
13. Ten Haken RK, Forman JD, Heimburger DK, et al. Treatment planning issues related to prostate movement in response to differential filling of the rectum and bladder. *Int J Radiat Oncol Biol Phys* 1991;20:1317-1324.
14. Balter JM, Sandler HM, Lam K. Measurement of prostate movement over the course of routine radiotherapy using implanted markers. *Int J Radiat Oncol Biol Phys* 1995;31:113-118.
15. McAfee MK, Allen MS, Trastek VF, et al. Colorectal lung metastases : Results of surgical excision. *Ann Thorac Surg* 1992;53:780-785.