

## SKELETAL MUSCLE METASTASES FROM CA LUNG

Sopon KUMPONPUNTH<sup>1</sup>, Patchrin PEKANAN<sup>1</sup>, Sirintara PONGPECH<sup>1</sup>

### ABSTRACT

Metastatic nodule to the thigh muscle from carcinoma of the lung in a 57 year-old foreign male patient was presented. The nodule was seen faintly on T1WI axial MRI scan. The nodule was seen better by coronal view T1WI and axial view T2WI. Skeletal muscles are still considered rare sites for metastases.

### INTRODUCTION

Previously, it was thought that the skeletal muscle was remarkable free of metastatic disease (1,2). It had been said that almost all secondary tumors of striated muscle represent invasion from contiguous structures (1,3). However, Schultz (3) reported 12 patients with proven skeletal muscle metastases by CT scan.

### CASE REPORT

A 57 year-old male European patient came with the palpable mass at the thigh. He had a bronchogenic carcinoma under treatment. MRI study of the mass showed a solid mass in the Vastus lateralis muscle, size 4 cm in diameter. The mass was hardly seen on axial T1WI and isosignal bright to the marrow of the femur on T2WI (TR 3000, TE 80); small brighter area 5 mm diameter was shown in the mass. There was no surrounding edema (Fig. 1). T1WI-coronal image shadowed more obvious lesion than the axial one (Fig. 2). Streaks of low signal was seen radiating from the center (Fig. 3). Metastatic process from Ca lung was noted.

<sup>1</sup> Department of Radiology, Ramathibodi Hospital, Rama 6 Street, Bangkok 10400, THAILAND.

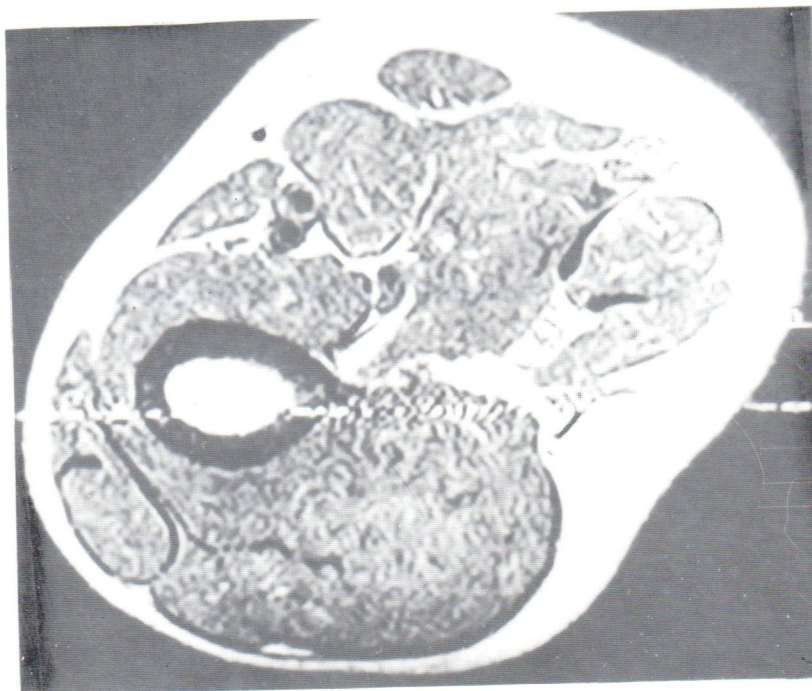


Fig. 1a. Axial T1WI (TR 500, TE 25) of the nodule in the Vastus lateralis showed very faint outline of the lesion.

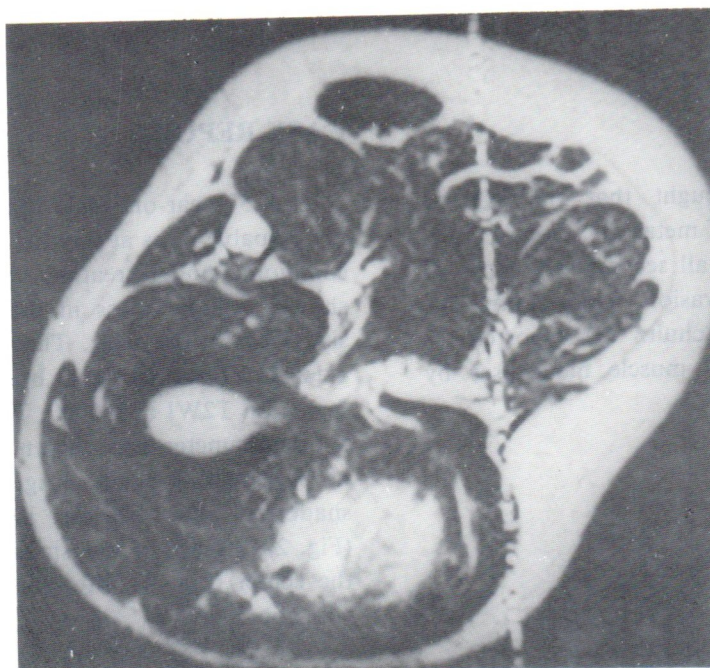


Fig. 1b T2WI-axial MRI study (TR 300, TE 80) of the nodule shows homogeneously bright nodule with a small brighter area at the anterior portion, represent necrosis.



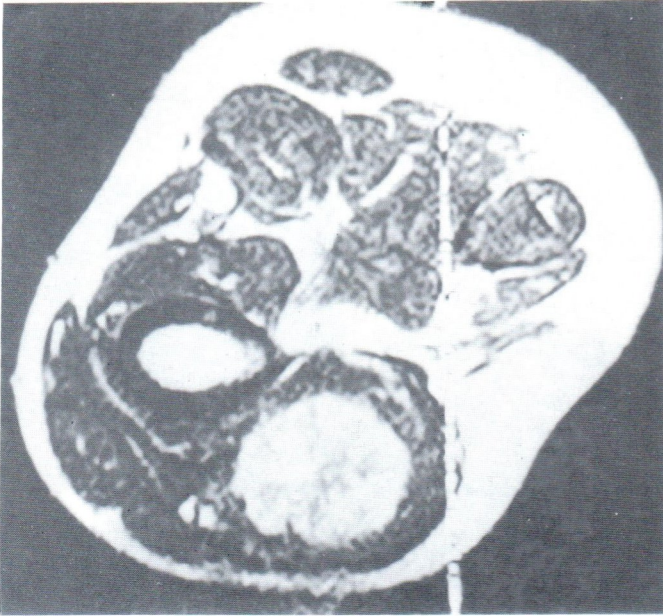


Fig. 2 Streaks of low signal radiated from the center to the periphery of the nodule was shown on the axial view, T2WI.

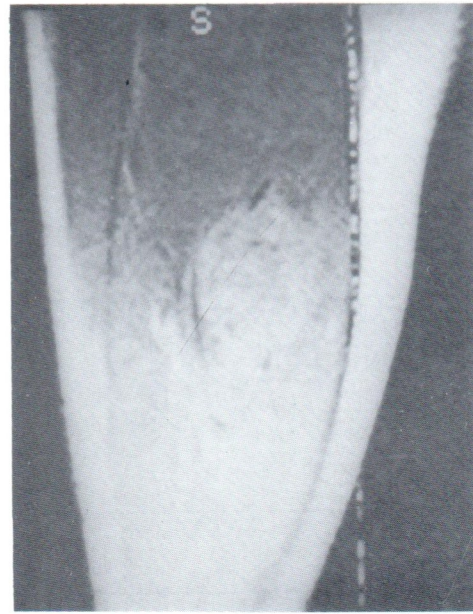


Fig. 3 Coronal view T1WI of the nodule showed faint hypersignal nodule embedded in the muscle of the Vastus lateralis. Better visualization of the nodule than the axial plane was observed.

## DISCUSSION

Metastatic disease of the skeletal muscle has been documented on rare occasions from melanoma, thyroid, or pulmonary carcinoma (1,3). Bone forming metastatic muscle disease has been seen from gastric adenocarcinoma, breast, ovary, thyroid, colon, bladder, skin and prostate gland (4).

Locations of masses reported (3) included iliopsoas muscles, gluteal muscle group, calf muscles, thigh muscles, anterior chest wall and quadratus lumborum muscle. Primary carcinoma sites reported by Schultz were endometrium, breast, esophagus, ovary, prostate, kidney, and lymph nodes.

CT findings reported by Schultz were enlargement of the muscle with a well defined or ill defined areas of decreased attenuation, which represented necrosis. The use of contrast enhancement was helpful in many instances to clarify the extent of the tumor (3).

MRI demonstrates the outline and the content of the tumor better. The tumor is usually low on T1WI and bright on T2WI and can be seen better than the CT scan. The surrounding edema is also well visualized by T2WI-sequence.

## REFERENCES

1. Delaney W. Non-myogenic tumors involving skeletal muscle. *An Clin Lab Sci* 1975;5:236-41.
2. Seely S. Possible reasons for high resistance of muscle to cancer. *Med Hypotheses* 1980;6:133-7.
3. Schultz SR, Bree RL, Schwab RE, Raiss G. CT detection of skeletal muscle metastases. *J Comput Tomogr* 1986;10:81-83.
4. Obley D, Slasky B, Peel R, Rosenbaum L, Nicholas J, Ellis L. Bone-forming gastric metastases in muscle-computed tomographic demonstration. *J Comput Tomogr* 1983;7:129-34.