

Original Article

Acute changes of superior mesenteric artery pressure after intraarterial bolus injection of prostaglandin-E1

Yukihiro Hama, M.D., Ph.D.

From Department of Radiology, Tokyo Edogawa Cancer Center, Edogawa Hospital,
2-24-18 Higashikojiwa, Edogawaku, Tokyo 133-0052, Japan.

Address correspondence to Y.H.(yjhama2005@yahoo.co.jp)

Received 22 January 2023; revised 21 August 2023; accepted 21 August 2023
doi:10.46475/aseanjr.v24i2.206

Abstract

Background: A bolus injection of prostaglandin-E1 (PGE1) into the superior mesenteric artery (SMA) immediately before SMA-portography can effectively visualize the portal vein.

Objective: The purpose of this study was to obtain basic pharmacoangiographical data and evaluate the hemodynamic changes following intra-arterial bolus injection of PGE1.

Materials and Methods: Forty-four consecutive patients undergoing transcatheter arterial chemoembolization (TACE) for liver cancer were retrospectively evaluated. SMA-portography was performed prior to TACE. An intra-arterial bolus injection of PGE1 was performed immediately before SMA-portography. Both SMA pressure and left brachial artery pressure were measured before, 1, 2, 3, 4, and 5 minutes after SMA-portography.

Results: Systolic pressure in the SMA decreased significantly 3 minutes after SMA-portography and remained low for 5 minutes. The maximum reduction rates in systolic and diastolic blood pressure in the SMA were 4.8% (4 minutes after SMA-portography) and 6.8% (5 minutes after SMA-portography), respectively. The left brachial artery pressure decreased similarly to the SMA. There were no significant changes in pulse pressure before or after PGE1 injection in either the SMA or brachial arteries.

Conclusion: A bolus injection of PGE1 into the SMA was shown to decrease blood pressure in the SMA and brachial arteries, but the pulse pressure remained constant.

Keywords: Interventional radiology, Pharmacodynamics, Catheterization.

Introduction

Superior mesenteric arterial portography (SMA-portography) or CT during arterial portography (CTAP) allows noninvasive visualization of blood flow to normal liver tissue as well as portosystemic shunts [1,2]. Prostaglandin-E1 (PGE1), a vasodilator, binds to prostaglandin receptors on smooth muscle cells which triggers the adenylate cyclase conversion of adenosine triphosphate to cyclic adenosine monophosphate (cAMP) [3]. Elevated cAMP results in reduction of cytosolic calcium and relaxation of smooth muscle. PGE1 is administered intra-arterially immediately before angiography to improve the contrast effect on the portal vein, but there are few data on arterial pressure change after bolus injection of PGE1 [4]. The purpose of this study was to obtain basic pharmacoangiographical data and evaluate the hemodynamic changes following intra-arterial bolus injection of PGE1.

Materials and methods

All procedures were in accordance with the ethical standards of the institutional and/or national research committee and with the 1964 Helsinki Declaration and its later amendments or comparable ethical standards. Our institutional review board granted a waiver of consent for this retrospective chart review study. Informed consent was obtained from the patients for the use of clinical data.

Patients

We retrospectively reviewed endovascular treatment charts of 44 consecutive patients (M/F 33/11) who had undergone transcatheter arterial chemoembolization (TACE) for liver cancer in the past 10 months at our institution. The median age of the patients was 68 years (interquartile range [IQR] 61-73 years). Of the 44 patients, 28 (63.6%) were diagnosed with hypertension but had stopped taking antihypertensive medication 24 hours prior to the angiogram.

Data collection

Approximately 10 mL of local anesthetic agent (1% lidocaine without epinephrine) was injected around the right femoral artery site, which was cannulated with Seldinger technique, and SMA-portography was performed prior to TACE. A 4-Fr sheath 11 cm in length and a 4-Fr shepherd hook catheter (Clinical Supply, Hashima, Japan) was used. Prior to SMA-portography, 5 micrograms of PGE1 (Alprostadil, Mitsubishi Tanabe Pharma, Osaka, Japan), diluted in 10 ml saline was injected intra-arterially through the catheter. Before intra-arterial administration of PGE1 and 1, 2, 3, 4, and 5 minutes after SMA-portography, SMA pressure was measured using a monitoring device (DX-300, NIHON KOHDEN, Tokyo, Japan), while blood pressure was simultaneously measured in the left upper arm (brachial artery) with a sphygmomanometer every minute. The patients received iodine-based contrast media at a flow rate of 4-5 mL/s and a total dose of 20-30 mL. After confirming portal venous flow on SMA-portography, TACE was performed. Once the 4-Fr guiding catheter was in place, the inner infusion catheter was inserted through the guiding catheter and advanced to the precise location within the artery that supplies the tumor. Then, chemotherapy drugs,

mixed with iodized oil, were injected through the infusion catheter into the tumor-supplying artery. After the mixture was delivered, embolic agents such as microspheres or gelatine sponge particles were injected through the infusion catheter.

Statistical analysis

Data were expressed as mean +/- and standard deviation (SD). Blood pressure and pulse pressure before PGE1 administration and after SMA-portography were compared using a paired t-test. All statistical tests were 2-sided, and group differences were considered statistically significant if $p < 0.05$.

Results

The systolic pressure in the SMA before PGE1 administration was 148.0 +/- 21.8 mmHg (IQR 127.0-167.3 mmHg), whereas at 1, 2, 3, 4, and 5 minutes after SMA-portography, it was 145.1 +/- 20.2 mmHg ($p = 0.23$), 143.1 +/- 21.6 mmHg ($p = 0.07$), 141.8 +/- 20.9 ($p < 0.05$) mmHg, 140.9 +/- 22.2 mmHg ($p < 0.05$), and 141.1 +/- 19.1 mmHg ($p < 0.05$), respectively (Figure 1a).

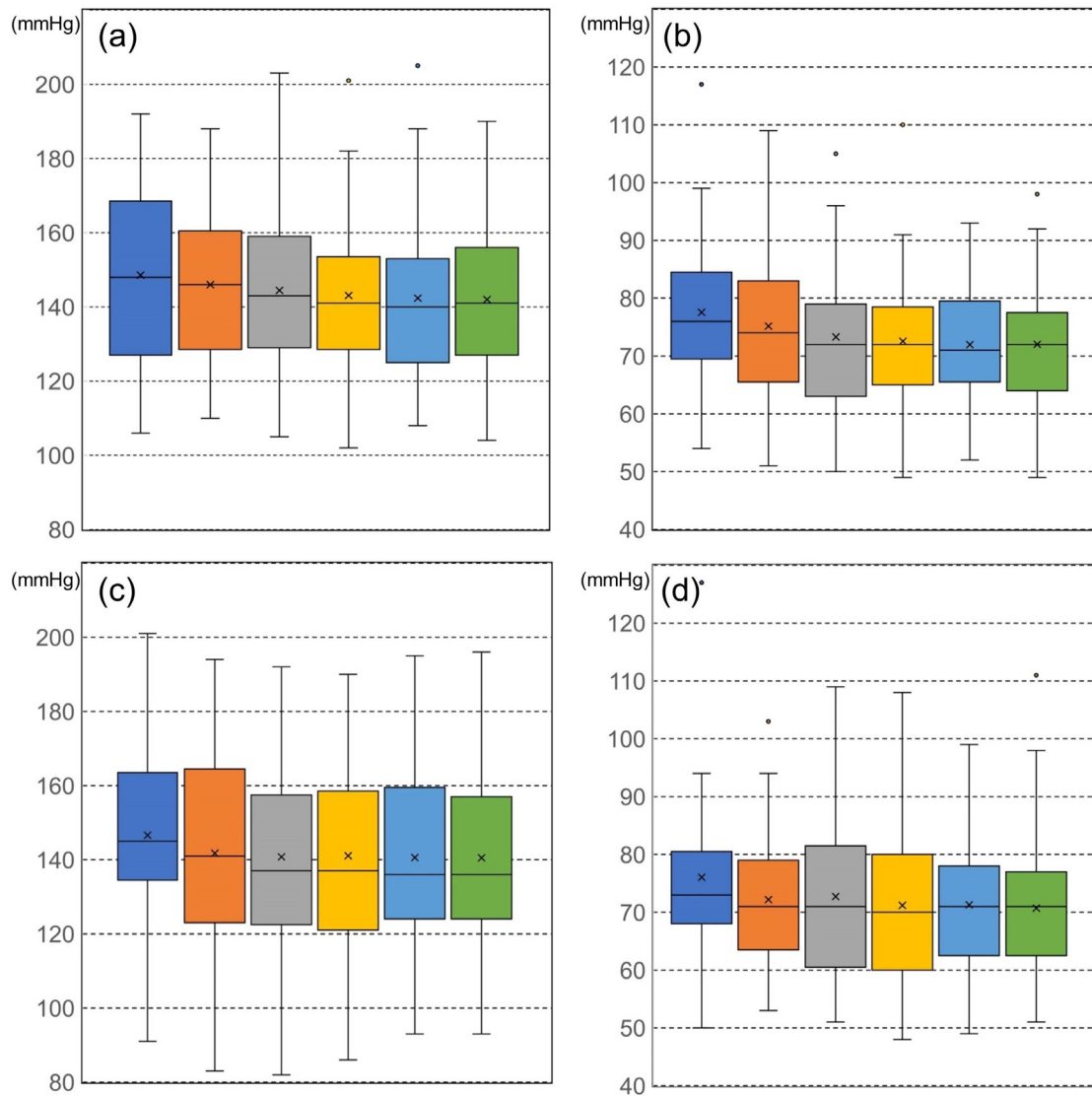


Figure 1. Box plots of blood pressure before intra-arterial injection of prostaglandin-E1 (blue) and 1 (dark brown), 2 (gray), 3 (yellow), 4 (light blue), and 5 (green) minutes after superior mesenteric artery-portography, (a) Systolic pressure in the superior mesenteric artery, (b) Diastolic pressure in the superior mesenteric artery, (c) Systolic pressure in the left brachial artery, (d) Diastolic pressure in the left brachial artery, "x" marks correspond to the means. The central horizontal bars are the medians. The lower and upper limits of the box are the first and third quartiles, respectively. Points above or below the whiskers' upper and lower bounds are outliers.

The diastolic pressure in the SMA before PGE1 administration was 76.7 +/- 12.3 mmHg (IQR 69.8-82.3 mmHg), whereas at 1, 2, 3, 4, and 5 minutes after SMA-portography, it was 74.4 +/- 12.3 mmHg ($p = 0.07$), 72.6 +/- 12.1 mmHg ($p < 0.05$), 71.7 +/- 12.0 mmHg ($p < 0.05$), 71.5 +/- 10.7 mmHg ($p < 0.05$), and 71.4 +/- 10.7 mmHg ($p < 0.05$), respectively (Figure 1b). The left brachial artery systolic pressure was 146.1 +/- 24.7 mmHg (IQR 135.3-159.0 mmHg) before PGE1 administration, whereas it was 140.9 +/- 27.4 mmHg ($p = 0.07$), 139.7 +/- 25.4 mmHg ($p < 0.05$), 140.0 +/- 25.6 mmHg ($p < 0.05$), 139.8 +/- 24.2 mmHg ($p < 0.05$), 139.9 +/- 23.9 mmHg ($p < 0.05$) at 1, 2, 3, 4 and 5 minutes after SMA-portography, respectively (Figure 1c). The left brachial artery diastolic pressure was 74.9 +/- 11.8 mmHg (IQR 68.0-80.0 mmHg) before PGE1 administration, whereas it was 71.5 +/- 11.2 mmHg ($p < 0.05$), 71.9 +/- 12.8 mmHg ($p < 0.05$), 70.4 +/- 12.3 mmHg ($p < 0.05$), 70.7 +/- 12.1 mmHg ($p < 0.05$), 70.1 +/- 11.7 mmHg ($p < 0.05$) at 1, 2, 3, 4 and 5 minutes after SMA-portography, respectively (Figure 1d). The maximum reduction rates in systolic and diastolic blood pressure in SMA were 4.8% (4 minutes after SMA-portography) and 6.8% (5 minutes after SMA-portography), respectively. The maximum reduction rates in systolic and diastolic blood pressure in the left brachial artery were 4.4% (2 minutes after SMA-portography) and 6.4% (5 minutes after SMA-portography), respectively. The pulse pressure in the SMA before PGE1 administration was 71.3 +/- 14.8 mmHg, whereas at 1, 2, 3, 4, and 5 minutes after SMA-portography, it was 70.7 +/- 11.7 mmHg ($p = 0.76$), 70.5 +/- 12.3 mmHg ($p = 0.73$), 70.1 +/- 12.6 ($p = 0.61$) mmHg, 69.4 +/- 14.5 mmHg ($p = 0.44$), and 69.7 +/- 11.1 mmHg ($p = 0.43$), respectively. The pulse pressure in the left brachial artery before PGE1 administration was 71.2 +/- 21.2 mmHg, whereas at 1, 2, 3, 4, and 5 minutes after SMA-portography, it was 69.4 +/- 19.8 mmHg ($p = 0.50$), 67.8 +/- 16.7 mmHg ($p = 0.19$), 69.6 +/- 15.9 ($p = 0.54$) mmHg, 69.1 +/- 15.3 mmHg ($p = 0.42$), and 69.7 +/- 16.1 mmHg ($p = 0.58$), respectively. After intra-arterial injection of PGE1, systolic and diastolic blood pressure decreased significantly in both SMA and brachial arteries, but pulse pressure did not change significantly.

Discussion

PGE1, also known as alprostadil, has been used to treat patent ductus arteriosus [5], erectile dysfunction [6], thromboangiitis obliterans [7], arteriosclerosis obliterans [8], and skin ulcers caused by diabetes [9]. Because of the safety and rapid vasodilating effect of PGE1, SMA-angiography is performed by bolus injection of PGE1 into the SMA immediately before angiography. Intra-arterial bolus injection of PGE1 induces intestinal peristalsis, which may be complicated by abdominal discomfort, nausea, and vomiting; however, there have been no studies examining acute hemodynamic changes in the SMA or peripheral arteries. As far as we know, this is the first report on changes in SMA and brachial arterial blood pressure after intra-arterial bolus injection of PGE1. According to the results of this study, both SMA and brachial systolic pressure dropped by about 5% after 3 minutes of intra-arterial injection of PGE1. SMA and brachial blood pressure, both systolic and diastolic, were comparable before and 5 minutes after administration. This indicates that PGE1 acts on arteries throughout the whole body and lowers blood pressure, rather than specifically on the target artery in this case SMA.

This study has several strengths. First, there are no reports measuring changes in both peripheral (brachial) and central (superior mesenteric artery) blood pressure after intra-arterial bolus injection of PGE1. The results of this study indicate that PGE1 nonspecifically lowers peripheral and central blood pressure within 3 minutes and maintains its hypotensive effect for at least 5 minutes after injection. Second, despite the high concentration of PGE1 infused into the SMA, there was no significant difference in the blood pressure lowering effect between the brachial artery and SMA. This indicates that temporarily high concentrations of PGE1 passing through an artery do not selectively decrease the blood pressure in that artery. Central blood pressure may be estimated by measuring peripheral blood pressure after PGE1 is injected into the central artery. Knowing that a blood pressure drop of about 5% occurring after intra-arterial infusion of PGE1 would be helpful in differentiating it from other causes of hypotension (e.g., vagal reflex, anaphylactic shock, etc.). This piece of knowledge of the pharmacological effects of PGE1 may contribute to the safe performance of angiography.

This study has some limitations. First, all the subjects in this study were liver cancer patients, and changes in arterial blood pressure in healthy subjects were not evaluated. However, since invasive angiography is not usually performed on healthy subjects, the lack of data on healthy subjects is not a limitation. Second, intestinal blood flow was not directly measured, and it remains a mystery how much the increase in intestinal blood flow contributed to the decrease in peripheral and central arterial blood pressure. The effect of PGE1 on cardiac function after intra-arterial infusion into the central arteries has not yet been evaluated. The effect of intra-arterial bolus injection of PGE1 on cardiovascular hemodynamics remains a topic for future research.

Conclusion

In conclusion, a single cohort study cannot be generalized to others without further scientific validation; however, after intra-arterial bolus infusion of PGE1, both systolic and diastolic blood pressures in the SMA and brachial artery were lower than before PGE1 infusion and remained lower for at least 5 minutes after infusion, while pulse pressure remained constant.

Acknowledgements

The author would like to thank Dr. Yutaka Sakurai for statistical analysis and is grateful to Dr. Shoichi Kusano for data collection and collaboration on the early stages of this work.

References

1. Redvanly RD, Chezmar JL. CT arterial portography: technique, indications and applications. *Clin Radiol* 1997;52:256-68. doi: 10.1016/s0009-9260(97)80051-7.
2. Soyer P. CT during arterial portography. *Eur Radiol* 1996;6:349-57. doi: 10.1007/BF00180609.
3. Owen NE. Effect of prostaglandin E1 on DNA synthesis in vascular smooth muscle cells. *Am J Physiol* 1986;250(4 Pt 1):C584-8. doi: 10.1152/ajpcell.1986.250.4.C584.
4. Davidovic LB, Vranes MR, Lotina SI, Cernak IF, Velimirovic DB, Stojanov PL, et al. Intraarterial perfusion of prostaglandin E1 after lumbar sympathectomy or reconstruction on femoropopliteal segment. *Int Angiol* 1991;10:178-81.
5. Akkinapally S, Hundalani SG, Kulkarni M, Fernandes CJ, Cabrera AG, Shivanna B, et al. Prostaglandin E1 for maintaining ductal patency in neonates with ductal-dependent cardiac lesions. *Cochrane Database Syst Rev* 2018;2: CD011417. doi: 10.1002/14651858.CD011417.pub2.
6. Urciuoli R, Cantisani TA, Carlini M, Giuglietti M, Botti FM. Prostaglandin E1 for treatment of erectile dysfunction. *Cochrane Database Syst Rev* 2004;(2): CD001784. doi: 10.1002/14651858.CD001784.pub2.
7. Cacione DG, Macedo CR, do Carmo Novaes F, Baptista-Silva JC. Pharmacological treatment for Buerger's disease. *Cochrane Database Syst Rev* 2020;5:CD011033. doi: 10.1002/14651858.CD011033.pub4.
8. Ambrus JL, Taheri P, Killion D, Donaldson G. Clinical experience with prostaglandin E1 in the treatment of arteriosclerosis obliterans. A preliminary report. *J Med* 1983;14:1-15.
9. Miyata T, Yamada N, Miyachi Y. Efficacy by ulcer type and safety of lipo-PGE1 for Japanese patients with diabetic foot ulcers. *J Atheroscler Thromb* 2010;17:805-16. doi: 10.5551/jat.3608.