



Functional MRI During Memory Recognition in Healthy Adults

Theeraphol Panyaping, MD

Lojana Tuntiyatorn, MD

Chakrit Sugying, MD

Witaya Sungkarat, MD, PhD

Department of Radiology, Faculty of Medicine Ramathibodi Hospital, Mahidol University, Bangkok, Thailand

Abstract

Purpose: To localize the functional cortices enrolled during abstract picture recognition task that might be a baseline study to provide Thais standard paradigm for future research.

Material and methods: The protocol study was approved by institutional review board and local ethics committee. Informed written consent was obtained from all participants after character of the experimental study was fully explained. Twenty healthy subjects underwent functional MRI and axial T1 weighted image, the latter was anatomic reference image. Abstract picture recognition task as block paradigm was used. Statistic analysis of fMRI datas were analyzed as a whole group analysis and using sample t test random effect analysis model, RFX (corrected P value <0.01). BOLD activities on brain surface rendering images were displayed as color from red (less activity) to yellow (strong activity). The anatomic reference image was loaded to overlay the colored maps and the anatomy of the cerebral cortical lobes and gyri and hippocampal formation were defined. In addition, BOLD activities are also displayed as color overlays on axial, coronal and sagittal views of T1W reference anatomic images, gradual change from dark blue (less activity) to red (most strong activity).

Results: Activation for abstract picture recognition was observed at the both-sided cerebellum, bilateral parietal lobes, left hippocampus, bilateral occipital lobes including calcarine cortices, left motor cortex, bilateral premotor cortices, supplementary motor area and left superior temporal gyrus (Wernicke's area). There is asymmetry of the activities in both hemispheres with left-sided predominance. Bilateral parietal and occipital lobes showed the most intense activities.

Conclusion: Abstract picture recognition task showed activation in multiple areas of cortical brain, which correlates with the human memory processing.

Background

Functional MR imaging has been proved to be powerful non-invasive research technique to aid in identifying regions of brain activation by particular stimuli and tasks. By using blood oxygenated level-dependent (BOLD) technique that based on the detection of local alteration in cerebral blood flow (CBF) and blood oxygenation in response to brain activity and the effect of those oxygenation changes on the MR signal^{1,2}.

Functional MR imaging activation patterns during various memory tasks have been studied in healthy volunteers. Two main groups of structures involved in working memory and secondary memory include the prefrontal cortex and medial temporal lobe. Hence, these regions have been the focus of prior functional MR imaging studies of normal memory. In prior functional MR imaging studies¹⁻⁵ the prefrontal cortex has consistently been found to be involved in learning and recall. In those studies, specific regions or hemispheres have been localized on the basis of the cognitive paradigm used. Activation in the prefrontal cortex is greater with increasing memory loads and is more pronounced during initial, as opposed to repeated, attempts at learning⁵. Increased activation during learning is associated with more successful subsequent recall⁵. Authors of functional MR imaging studies have also documented the role of the medial temporal lobe in learning and recall. The medial temporal lobe structures most often implicated in these studies are the hippocampus and parahippocampal gyrus⁶.

In the prior functional MRI study during memory recognition in healthy volunteers using words and common nameable objects showed cortical activation at hippocampi with left-sided predominance.⁷

Corresponding with the recent functional MRI study in patients with mild cognitive impairment, which showed decreased cortical activation in bilateral frontal cortices, hippocampus, and left cerebellum compared with control subjects ($P < .001$).⁸ Hence, functional MRI study during memory recognition can be the sensitive tool in detecting cortical deactivation in mild cognitive impairment patients or early Alzheimer's disease with benefit in early diagnosis correlating with the clinical finding and psychological test, whereas no detectable abnormality on conventional MR imaging.

To date, no study of functional MRI during memory recognition task has been established in Thailand. This is the first study being and using abstract picture recognition paradigm. The purpose of this study is to localization of the functional cortices during working memory task in healthy subjects.

In addition, it will provide standard Thais paradigm for future more advanced research in memory functional MRI, especially in patients with mild cognitive impairment or early Alzheimer's disease.

Materials and Methods

Subjects

Twenty volunteer subjects (11 males, 9 females) were included in the study. Their age varies from 25 to 59 years old, mean age: 32 years. All of them are right-handed, healthy subjects without history of neurological and psychiatric episodes. The health status of the subjects was evaluated by interviewing and normal finding on their routine axial T1-weighted images. All volunteers performed MMSE (Mini Mental State Examination) and their results were normal. Informed written consent was obtained

from all participants after character of the experimental study was fully explained. The institutional review board and local ethics committee approved the study protocol.

Data acquisition and post processing analysis

Functional MR imaging was performed using a 3.0-Tesla whole body imager (Acheiva; Phillips Medical Systems, Best, the Netherlands) and sense head coil was used. An automatic shimming method enhanced the signal-to-noise ratio and reduced the functional MR susceptibility artifacts. Preliminary set up and localizing scan required about 30 sec. In vivo's Eloquence system was used to control what the patient see inside the scanner. By using the Experiment Presentation Computer (EPC), the stimuli were presented via the Patient display hood (PDH), which contains a 15-inch LCD, 1025x768 resolution and 30 degree visual field coverage. The PDH was mounted on the head coil and the subjects were positioned in the scanner in supine position. The patients were instructed to look at the screen whether they can see the entire screen. Synchronization of the fMRI scan with the stimuli from the EPC was manually performed, and then time delay will be corrected.

Axial T1 weighted image {repetition time (TR) = 200 milliseconds, echo time (TE) = 2.3 milliseconds, in phase} will be the first step to provide image for anatomical localization of the activation maps.

Then functional MR imaging will be performed using a gradient-echo, echo planar sequence with following parameters; TR/TE=3000/35 milliseconds; flip angle, 90 degree; matrix size, 128x128; field of view, 240x240 mm; section thickness, 5 mm; no

gap intersection. Echo-planar images were position perpendicular to the long axis of the whole brain.

Imaging preprocessing and data analyses will perform with SPM2 software (Wellcome Department of Cognitive Neurology, London, England). Data preprocessing are done in a standardized fashion by using the following established procedures: section timing correction, motion correction and spatial normalization of the resection volumes to a based on the Montreal Neurological Institute (MNI) reference brain space. After spatial normalization, images will smooth with an 8-mm full-width-at-half-maximum isotropic Gaussian kernel.

Statistic consideration

Results of all subjects will be analyzed as a whole group analysis applying the general linear model and data will be analyzed by using the one-sample t test random effect analysis model, RFX (corrected P value <0.01).

The results were displayed in tile viewers, showing images with an overlay of colored maps (SPMs). Pixels with a value at or above the threshold value (corrected P value <0.01) were displayed as part of colored overlay. BOLD activities are displayed as brain surface rendering images with an overlay of colored maps, gradual change from red (pixels at threshold level) to yellow (pixels at greater threshold level). In addition, BOLD activities are also displayed as color overlays on axial, coronal and sagittal views of T1W reference anatomic images, gradual change from dark blue (less activity) to red (most strong activity).

The anatomic reference image was loaded to overlay the colored maps and the anatomy of the hemispheric lobes, cortical gyri and hippocampal

formation were defined according to supratentorial cortical anatomy and anatomy of the hippocampal formation on elsewhere⁹. Two neuroradiologists localized anatomy of areas of activation in consensus.

Cognitive task

Paradigm:

All participants will be trained to perform the functional MR imaging tasks by power point presentation, which will take about 10 minutes per person immediately before imaging.

Step 1

There are eight blocks of abstract pictures and each block contained six pictures. During picture encoding, the pictures will be projected on a computer screen at outside the imaging room and subjects will view the total 48 abstract pictures sequentially. Each block will be presented with 3 seconds per picture and 3 sec interval time for each block. These pictures will run sequentially and three round each. In total 48 images with three rounds each will acquire per subject and take time about 7.2 minutes. The subjects will be instructed to view the pictures carefully and memorize them.

Step 2: two sequential tasks

After finish the step 1, subjects will be positioned on the imaging table with a specially molded foam pad to restrict motion of the head. The pictures were projected on the small overhead LCD of

the PDH.

Task 1: Recognition

There are eight blocks of abstract pictures. Each block consists of six abstract pictures previously seen on step 1 and following by four gray screen pictures (control condition). Each block will be presented, sequentially with 3 seconds per picture.

Task 2: New picture

There are eight blocks of unseen abstract pictures. Each block consists of six new abstract pictures, which are not seen on step 1 and following by four solid gray screen pictures (control condition). Each block will be presented, sequentially with 3 seconds per picture.

The sequential tasks will perform with each block of task 1 (recognition condition) alternating with task 2 (new picture) in same fashion for all subjects. The functional MRI will be performed during task 1 and task 2 in 8 minutes. The subject will press the bottom on the right hand if there is any picture in the step 1.

Results

Twenty healthy subjects were included in the study, 11 males and 9 females, ages from 25 to 59 years old, mean age: 32 years. (Table 1)

BOLD activities are displayed as brain sur-



Fig. 1 Example of abstract pictures

face rendering images with an overlay of colored maps from red (less activity) to yellow (strong activity) as well as color overlays on axial, coronal and sagittal views of T1W reference anatomic image from dark blue (less activity) to red (strong activity).

The activity for task 1 (recognition) and task 2 (new picture) versus baseline are observed mainly at the both-sided cerebellum, bilateral occipital and parietal lobes as well as some activities at frontal lobes including supplementary motor area (Figure 1).

Using the statistical procedures as described above (corrected P value <0.01), activation for abstract pictures recognition versus new abstract pictures viewing was observed at the both-sided cerebellum, bilateral parietal lobes, bilateral occipital lobes including calcarine cortices, left hippocampus, left precentral gyrus, bilateral premotor cortices (posterior aspect of middle frontal and inferior frontal gyri), supplementary motor area and left superior temporal gyrus (Wernicke's area). (Figure 2) The BOLD signal at the left hippocampus is present at anterior aspect. (Figure 3) No activation of the right hippocampus is observed. Activities at the bi-

lateral caudate nuclei and left thalamus are also observed. (Figure 4) Bilateral parietal and occipital lobes showed the most intense activities. Note asymmetry of the activities in both hemispheres with left-sided predominance.

Comparing with activity during abstract picture recognition, the activity during viewing new abstract pictures showed the same location but significant lower in intensity (corrected $P < 0.01$).

Discussion

Functional MRI is superior to other functional imaging techniques (SPECT and PET) because it can evaluate both structural and functional anatomy in the single imaging with less time consuming and no contrast administration. Different type of stimuli and paradigm activates different cortical regions. Hence, functional MRI may be an aid powerful tool for evaluation of structure and function of the specific brain areas.

In prior functional MR imaging studies¹⁻⁵, the prefrontal cortex has been found to be activated in learning and recall. Also, there are many studies of prefrontal cortex lateralization on memory working.

Table 1 Demographic data of the subjects

Subject	Age	Sex
1	30	F
2	31	M
3	40	F
4	42	F
5	27	F
6	30	M
7	28	M
8	32	M
9	28	M
10	30	F

Subject	Age	Sex
11	25	M
12	27	F
13	30	M
14	28	M
15	28	F
16	53	F
17	59	M
18	28	M
19	25	M
20	30	F

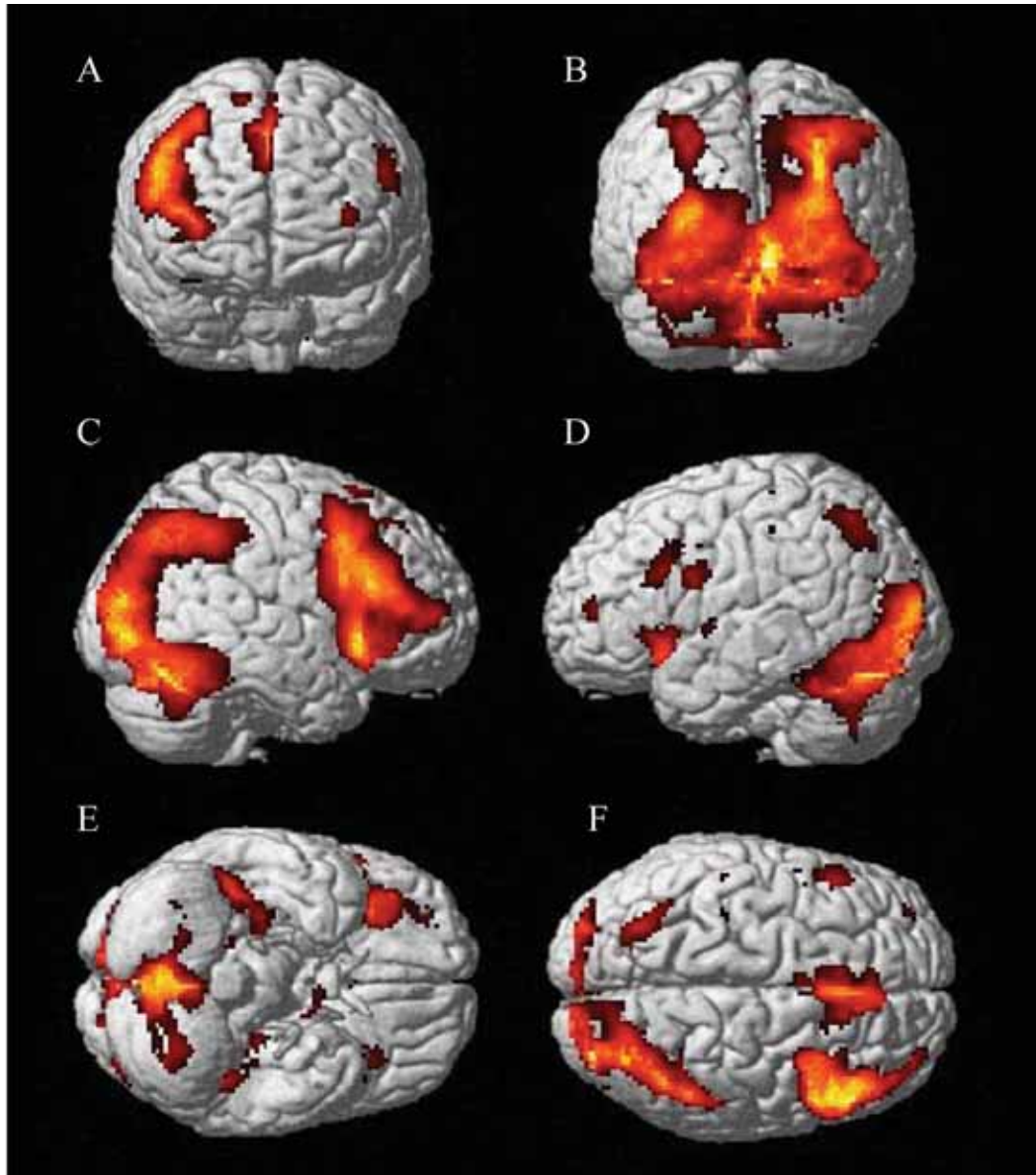


Fig. 1 Brain surface rendering images with an overlay of colored maps. A; anterior view, B; posterior view, C; right lateral view, D; left lateral view, E; inferior view, F; superior view Intensity of activation was displayed as color from red (less activity) to yellow (strong activity). The pictures showed activation for task 1 (recognition) and task 2 (new picture) versus baseline (control condition) at the both-sided cerebellum, bilateral parietal lobes, occipital lobes and some area of frontal lobes including supplementary motor area.

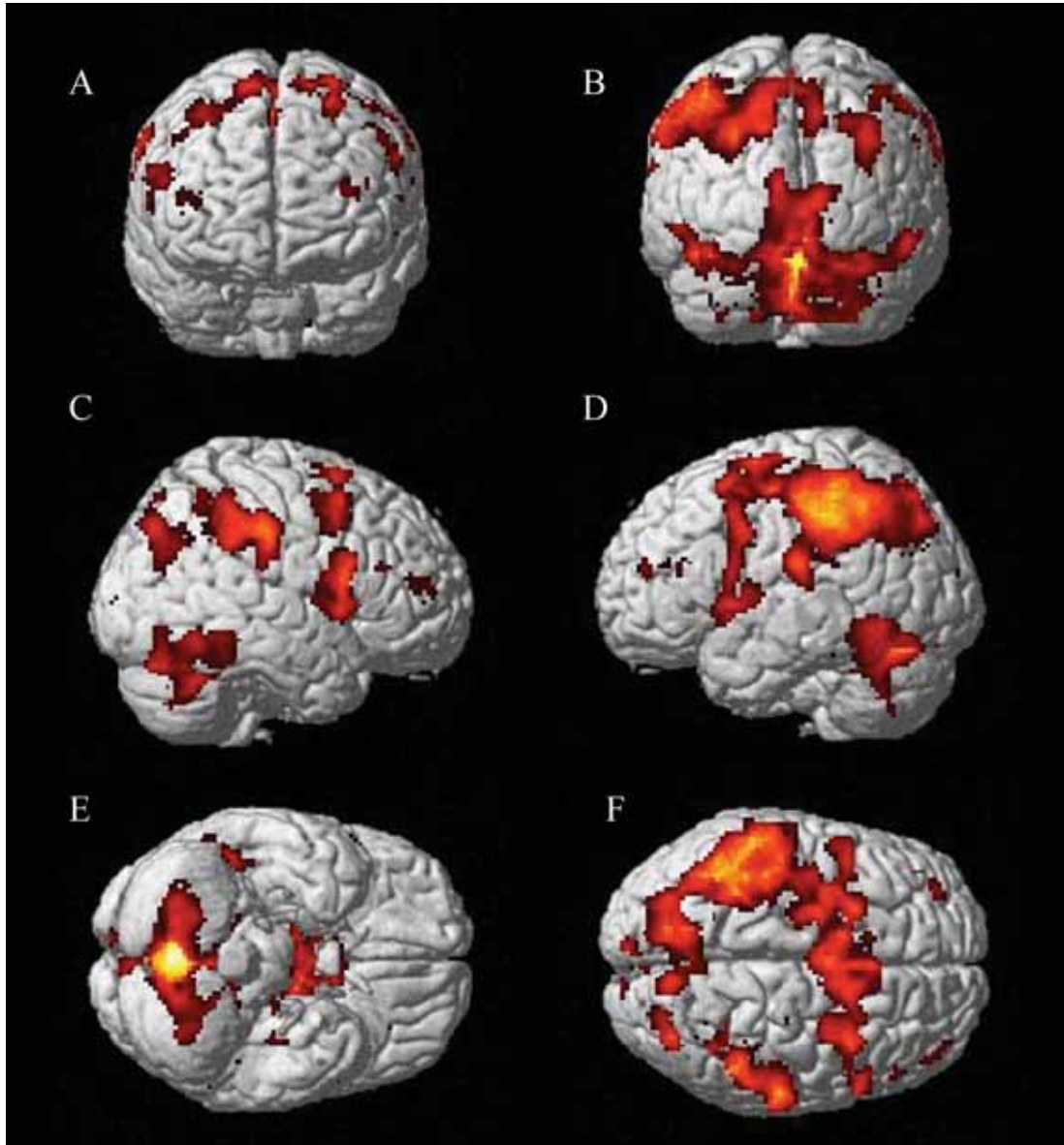


Fig. 2 Brain surface rendering images with an overlay of colored maps. A; anterior view, B; posterior view, C; right lateral view, D; left lateral view, E; inferior view, F; superior view. Intensity of activation was displayed as color from red (less activity) to yellow (strong activity). The pictures showed activation during abstract picture recognition at the both-sided cerebellum, bilateral parietal lobes, left hippocampus, bilateral occipital lobes, left motor cortex, bilateral premotor cortices, supplementary motor area and left superior temporal gyrus (Wernicke's area). These activities are predominant on the left side. Note the most intense activities at bilateral parietal and occipital lobes.

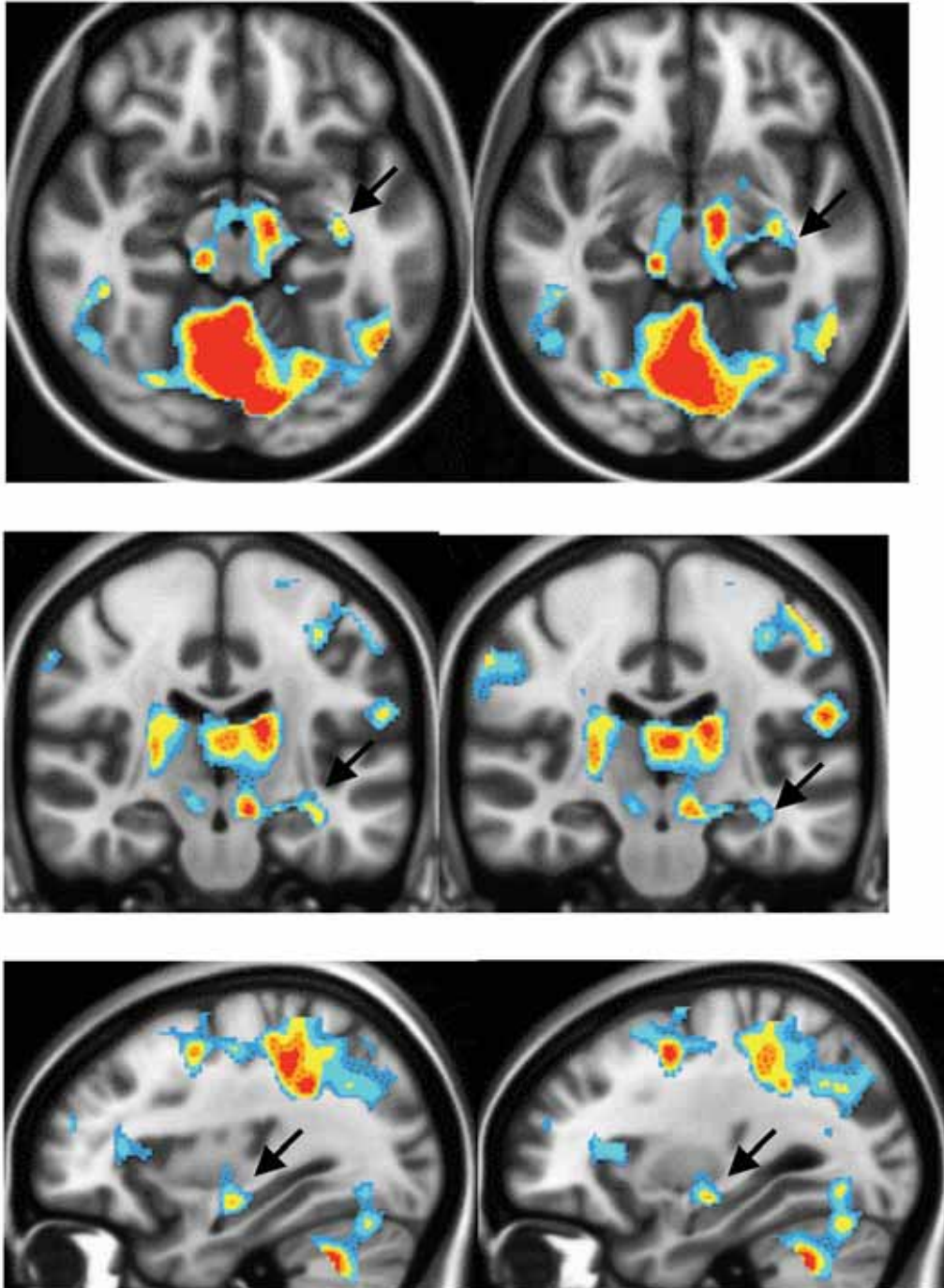


Fig. 3 Results at hippocampus level during abstract picture recognition are displayed as color overlays on axial (A), coronal (B) and sagittal (C) views of T1-weighted images. Intensity of activation was displayed as color, gradual change from dark blue (less activity) to red (strong activity). The pictures showed activation at the anterior aspect of left hippocampus (black arrow). Note no activation of the right hippocampus.

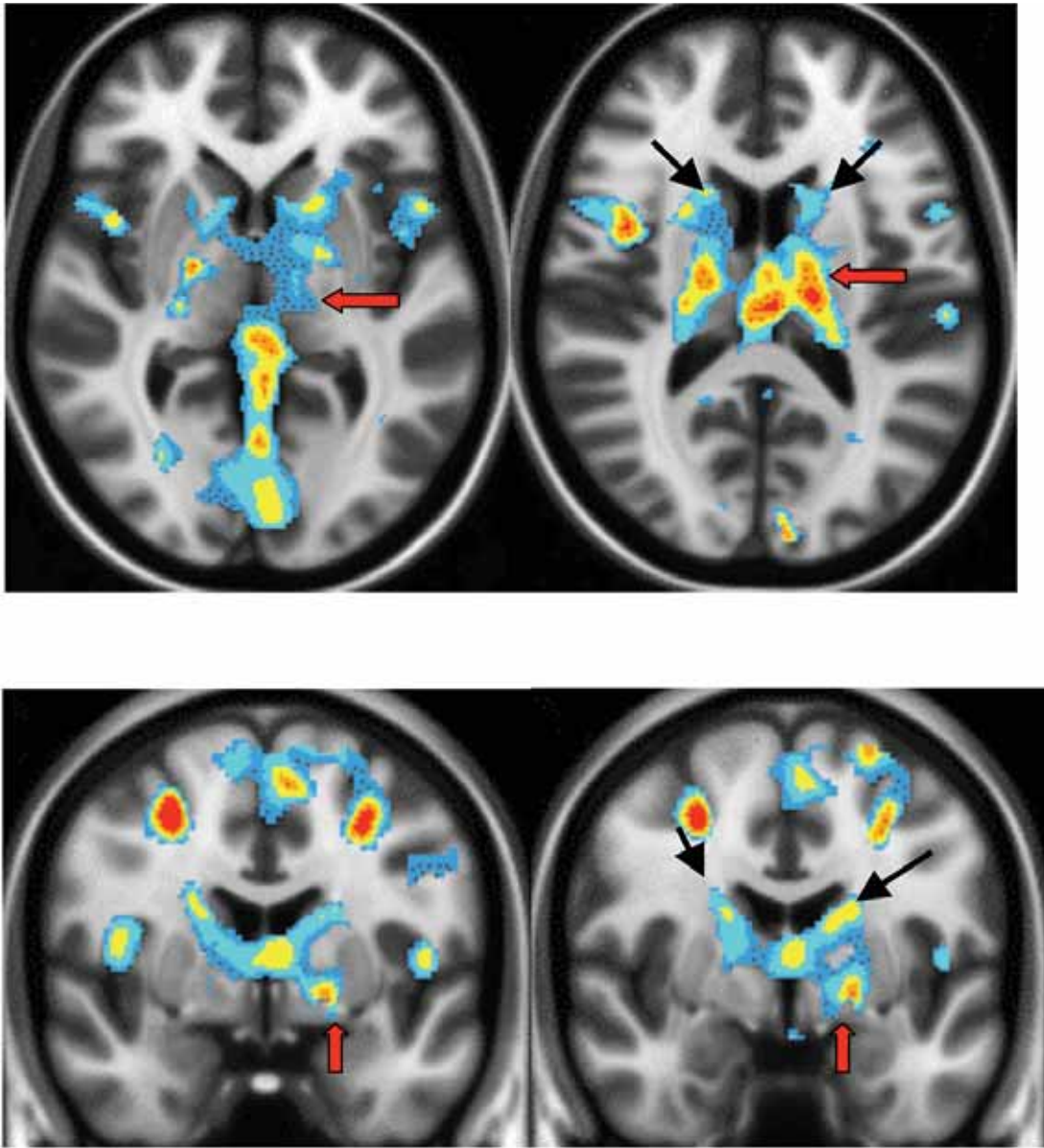


Fig. 4 Color overlays on axial (A) and coronal (B) views of T1-weighted images at the basal ganglia and thalamic regions. Intensity of activation was displayed as color, gradual change from dark blue (less activity) to red (strong activity). The pictures showed activities at the bilateral caudate nuclei (black arrow) and left thalamus (red arrow).

Grady et al studied brain activity during encoding pictures of objects and words using positron emission tomographic scans (PET). They found that differentiated stimulus type and the different encoding strategies yielded different brain activity with left prefrontal and bilateral medial temporal regions enrolled in deep processing and intentional learning of pictures⁶.

Task-activated BOLD signal at the left hippocampus in our study was anterior predominance, as has been previously reported in the prior functional MRI study during memory recognition in healthy volunteers using words and common nameable objects⁷. There was claimed that verbal/semantic memory is usually attributed to the left medial temporal structure and anterior aspect of hippocampus also supports the executive frontal lobe activity⁸. And corresponding with the recent functional MRI study in patients with mild cognitive impairment, which showed decreased cortical activation in the bilateral frontal cortices and left hippocampus during recognition ($P < .001$).⁹ Thus, it should be support that the left hippocampus plays the crucial role in memory recognition.

There has been known that cortical eye fields including occipitotemporal, occipitoparietal, parietal and prefrontal cortices¹¹. Furthermore, there are projections from visual cortex to the parietal, temporal and frontal lobes in pathway of memory processing and learning¹². Therefore, the most intense activation at parietal and occipital lobes as well as frontal lobes in our study could be associated with visual stimulation and memory pathway. Moreover, inferior parietal lobule has been implicated in the guidance of spatial attention and acts as a multifaceted behavioral integrator that binds visuospatial, motor

and cognitive information into a topographically salience. It may be said that the parietal cortex act as a bridge to link perception, action and cognition¹³.

The activity observed in the left thalamus is also consistent with the data in monkeys and humans at medial thalamus in previous study (Aggleton and Brown 1999) that indicates a role of the thalamus in memory recognition¹⁴.

The caudate nucleus is generally considered to be involved in the learning of more gradually acquired visual discrimination tasks (i.e., visual habit formation; Teng et al. 2000)¹⁵. Thus, activities at bilateral caudate nuclei in our study can be described with visual discrimination of the different abstract pictures in our memory task.

In addition, we found intense activation in the cerebellum and this finding confirms results of a previous study with 1.5-T MR imaging in healthy elderly subjects¹⁶. And corresponding with the result of decreased cortical activation at the left cerebellum in recent functional MRI study in patients with mild cognitive impairment⁹, which supports role of cerebellum in memory pathway.

There is also activation at the Wernicke's area, which may be due to receiving sensory input from visual and auditory cortices.

In this study, we have some limitation due to contamination of activity at the bilateral premotor cortices from activation of motor and sensory cortices during memory task.

The pictures using in this paradigm were not meaningful, resulting in no bias of the results due to effect of remote or long term memory. These our observations were based on group analysis with adequate sample size and statistically significance. So these results can be used as a reference of the

whole population. Thus, these results from healthy volunteers can also be used as control group reference for further research in the patients with mild cognitive impairment or early Alzheimer's disease. However, there is some limitation in age range of the subjects in our study that is too young comparing with age group of the patients with mild cognitive impairment or Alzheimer's disease.

Thus, further research of functional MRI during memory recognition in normal cognitive elderly subjects, with or without comparison to the patients with mild cognitive impairment or early Alzheimer's disease will get more benefit in early diagnosis combined with the clinical finding and psychological test. In addition, this functional MRI with abstract picture recognition paradigm could have benefit in follow up the patient with MCI or Alzheimer's disease by comparison of activation at specific areas between pre and post treatment.

Conclusion

The functional MR imaging of abstract picture recognition task in this study showed multiple sites of cortical activation. Significant activations were observed at the cerebellum, bilateral parietal lobes, occipital lobes, frontal lobes, left hippocampus, bilateral caudate nuclei, left thalamus and left superior temporal gyrus (Wernicke's area). There are asymmetric activities in both hemispheres with left-sided predominance.

Acknowledgement

The author thanks Dr. Witaya Sungkarat, Advisor and Ms. Ladawan Worapruengkjaru, MR technologist for technical help and data analysis.

References

1. Courtney SM, Ungerleider LG, Keil K, Haxby JV. Transient and sustained activity in a distributed neural system for human working memory. *Nature* 1997;386:608-11.
2. Ojemann JG, Buckner RL, Corbetta M, Raichle ME. Imaging studies of memory and attention. *Neurosurg Clin N Am* 1997;8:307-9.
3. Gabrieli JD, Poldrack RA, Desmond JE. The role of left prefrontal cortex in language and memory. *Proc Natl Acad Sci U S A* 1998;95:906-13.
4. Wagner AD, Desmond JE, Glover GH, Gabrieli JD. Prefrontal cortex and recognition memory: functional-MRI evidence for context-dependent retrieval processes. *Brain* 1998;121:1985-2002.
5. Buckner RL, Kelley WM, Petersen SE. Frontal cortex contributes to human memory formation. *Nat Neurosci* 1999; 2:311-4.
6. Cohen NJ, Ryan J, Hunt C, Romine L, Wszalek T, Nash C. Hippocampal system and declarative (relational) memory: summarizing the data from functional neuroimaging studies. *Hippocampus* 1999;9:83-98.
7. Craig E, L. Stark, Larry R. Squire. Functional magnetic resonance imaging (fMRI) activity in the hippocampal region during recognition memory. *The Journal of Neuroscience*, October 15, 2000, 20(20):7776-81.
8. Bellgowan PS, Binder JR, Swanson SJ. Side of seizure focus predicts left medial temporal lobe activation during verbal encoding. *Neurology* 1998;51:479-84.
9. Petrella JR, Krishnan S, Slavin MJ, Tran TT, Murty L, Doraiswamy PM. Mild cognitive impairment: evaluation with 4-T functional MR imaging. *Radiology* 2006;240:177-86.
10. Burton PD, Thomas PN, Tarek AY. Neuroimaging Clinical of North America. Anatomic basis of functional MR imaging. 2001;11:305-41.
11. Puce A, Allison T, Gore JC, McCarthy G. Face-sensitive regions in human extrastriate cortex studied by functional MRI. *J Neurophysiol* 1995;74:1192-9.
12. Anthony D., Benjamin J., Itamar K. Parietal lobe contributions to episodic memory retrieval. *TRENDS in Cognitive Sciences* 2005;9:445-53.

13. Gottlieb J. From thought to action: the parietal cortex as a bridge between perception, action and cognition. *Neuron* 2007;53:9-16.
14. Aggleton, J.P. and Brown, M.W. 1999. Episodic memory, amnesia and the hippocampal-anterior thalamic axis. *Behav. Brain Sci.* 22: 425-89.
15. Teng, E., Stefanacci, L., Squire, L.R., and Zola, S.M. 2000. Contrasting effects on discrimination learning after hippocampal lesions and conjoint hippocampal-caudate lesions in monkeys. *J. Neurosci.* 20:3853-63.
16. Rombouts SA, Barkhof F, Veltman DJ, et al. Functional MR imaging in Alzheimer's disease during memory encoding. *AJNR Am J Neuroradiol* 2000;21:1869-75.